



Image of the month

Wandering Spleen[☆]

Bazo errante

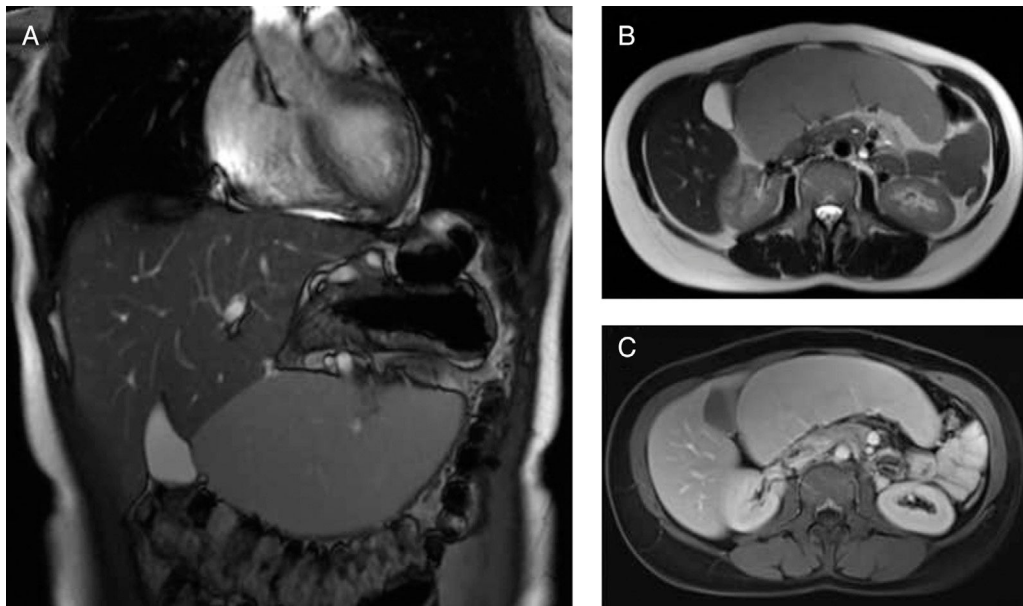
Veysel Ayyildiz,^a Bulent Guvendi,^b Hayri Ogul,^{c,*} Mecit Kantarci^c^a Department of Radiology, School of Medicine, Siirt State Hospital, Siirt, Turkey^b Department of General Surgery, Medical Faculty, Kafkas University, Kars, Turkey^c Department of Radiology, Medical Faculty, Ataturk University, Erzurum, Turkey

Figure 1

A 36-year-old woman presented with a 6-month history of pain in the hypogastrium. Physical examination, a large ovoid hypogastric mass was palpable. Magnetic resonance (MR) imaging showed absence of the spleen in the left upper quadrant as well as an enlarged spleen in the hypogastric region (Fig. 1A and B). On contrast enhanced images, the spleen had relatively homogeneous parenchyma structure (Fig. 1C). During the six months' period of control, due to the sudden onset of the abdominal pain, emergency splenectomy was performed. Acute torsion of the spleen was confirmed by surgery.

[☆] Please cite this article as: Ayyildiz V, Guvendi B, Ogul H, Kantarci M. Bazo errante. Cir Esp. 2018;96:171.

* Corresponding author.

E-mail address: drhogul@gmail.com (H. Ogul).