



Image of the month

Juxtarenal Aortoiliac Occlusive Disease in a Patient With Left Sided Inferior Vena Cava[☆]



Obstrucción aorto-bi-iliaca yuxtarenal en paciente con vena cava inferior izquierda

Delfina Fletcher Sanfeliu,^{*} Cristina Rueda Muñoz, Iván Martín-González, José Ángel Bahamonde Romano

Servicio de Cirugía Cardiovascular, Hospital Clínico Universitario Valencia, Valencia, Spain

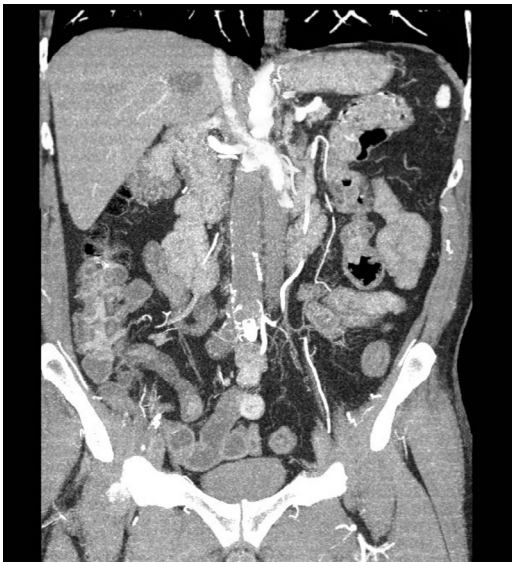

Fig. 1

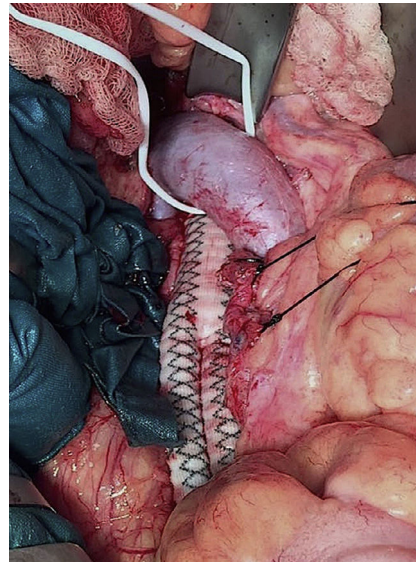


Fig. 2

A 58-year-old patient presented with critical ischemia of the right lower limb. CT angiography showed bilateral aortoiliac occlusive disease from the juxtarenal region and a left inferior vena cava (LIVC) that crossed to the right side in front of the aorta at the juxtarenal level (Fig. 1).

Using midline laparotomy, an aortobifemoral bypass was performed with a Dacron[®] 14 × 7 × 7 mm bypass graft, requiring mobilization of the LIVC to allow for suprarenal clamping and the creation of a proximal end-to-end anastomoses (Fig. 2).

The patient recovered bilateral pedal pulse and experienced transient acute renal failure in the postoperative period. The patient was discharged 7 days after the operation.

[☆] Please cite this article as: Fletcher Sanfeliu D, Rueda Muñoz C, Martín-González I, Bahamonde Romano JÁ. Obstrucción aorto-bi-iliaca yuxtarenal en paciente con vena cava inferior izquierda. Cir Esp. 2017;95:543.

^{*} Corresponding author.

E-mail address: delfletsan@gmail.com (D. Fletcher Sanfeliu).