



Image of the Month

Calcified Adrenal Pseudocyst: A Rare Pathology[☆]

Pseudoquiste suprarrenal calcificado: una dolencia infrecuente

Álvaro Martínez Manzano^{*} Elena Romera Barba, Francisco Javier Espinosa López, Ángel de Paco Navarro

Servicio de Cirugía General y del Aparato Digestivo, Hospital Universitario Santa Lucía, Cartagena (Murcia), Spain

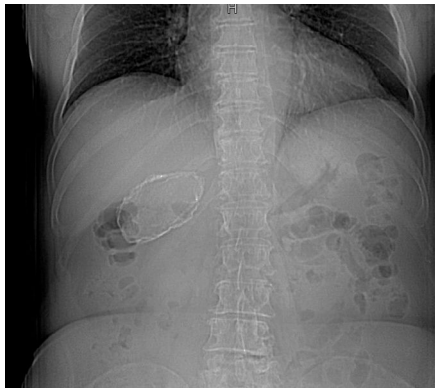


Fig. 1

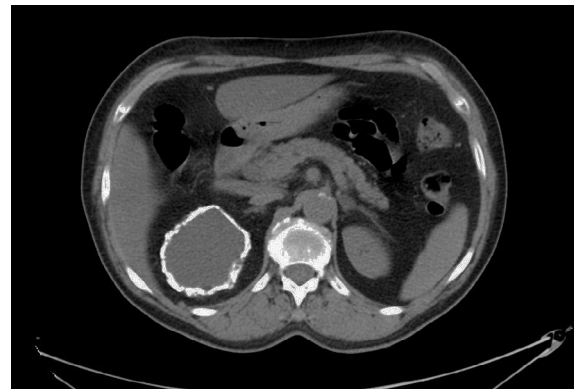

Fig. 2

The patient is a 73-year-old woman with no prior history of interest, who came to the emergency room due to lumbar pain. Lumbar radiograph (Fig. 1) identified a calcified image in the right hypochondrium. Abdominal CT scan (Fig. 2) showed a lesion in the right adrenal gland, suggestive of a calcified adrenal pseudocyst.

Pseudocysts are the most frequent subtype of adrenal cysts. They are formed by encapsulated residue from an adrenal hemorrhage; calcifications can be found in 10%–15% of cases. It is recommended to resect cysts larger than 5 cm due to the high risk of bleeding and secondary complications.

[☆] Please cite this article as: Martínez Manzano Á, Romera Barba E, Espinosa López FJ, de Paco Navarro Á. Pseudoquiste suprarrenal calcificado: una dolencia infrecuente. Cir Esp. 2017;95:612.

^{*} Corresponding author.

E-mail address: alvaromm88@gmail.com (Á. Martínez Manzano).