



Image of the month

Extreme Gigantomastia[☆]

Gigantomastia extrema

Ana Calvache González,^{*} Beatriz Vidal Herrador, Mariana Loreto Brand, Finta Abella Otero

Unidad de Mama, Servicio de Cirugía General, Complejo Hospitalario Universitario de Santiago de Compostela, Santiago de Compostela, La Coruña, Spain

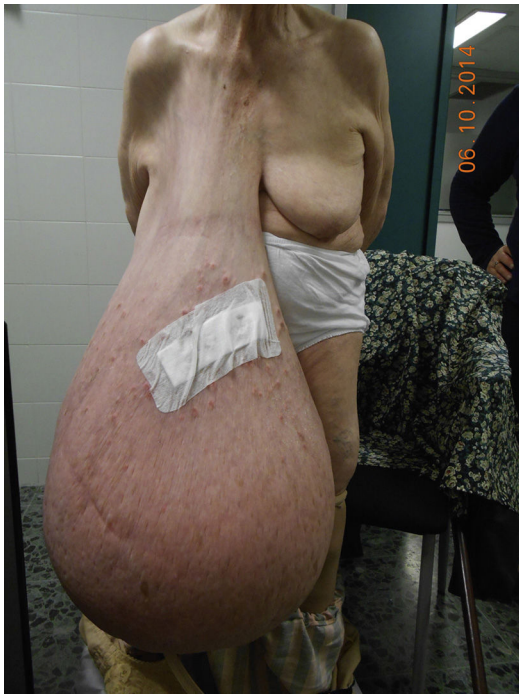

Fig. 1

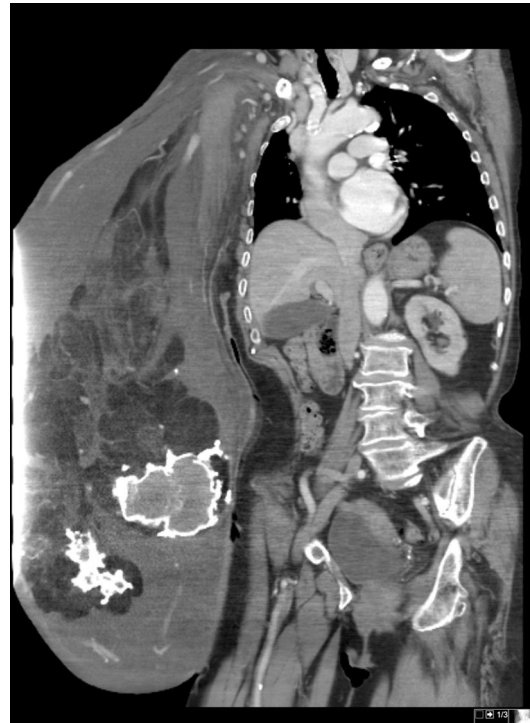


Fig. 2

84 year old woman, no history of interest, with progressive growth of the right breast for 40 years. It presents a breast of 30 kg (Fig. 1), which causes him to occasionally dizziness and shortness of breath in standing position. TAC Thoracoabdominal (Fig. 2): giant breast with severe cutaneous edema, heavy glasses and Central gross calcifications (liponecrosis). Without signs that suggest malignancy or other pathologic findings.

Histopathological diagnosis after mastectomy right: multiple foci of infiltrating ductal carcinoma, grade I, Luminal A, located in dermis and underlying breast tissue, epidermal ulceration and infiltration of the nipple-areola complex; 3-year disease-free.

[☆] Please cite this article as: Calvache González A, Vidal Herrador B, Loreto Brand M, Abella Otero F. Gigantomastia extrema. Cir Esp. 2018;96:377.

^{*} Corresponding author.

E-mail address: acalvache@telefonica.net (A. Calvache GonzálezQ1).