



Image of the month

Intestinal Obstruction and Megarectum[☆]

Megarrecto condicionante de oclusión intestinal

Juan Manuel Romero Marcos,^{*} María Pau Carbonell Aliaga, Lorenzo Sbert Castañer, José Andrés Cifuentes Ródenas

Servicio de Cirugía General, Hospital Son Llàtzer, Palma de Mallorca, Spain

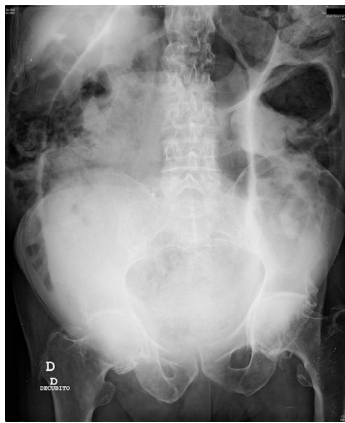


Fig. 1

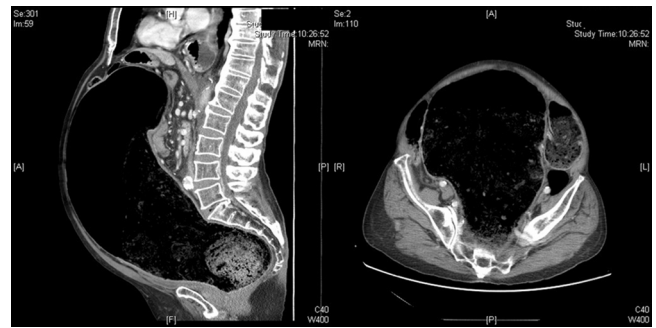

Fig. 2

The patient is a 68-year-old male who came to the Emergency Room complaining of symptoms of bowel obstruction. Abdominal radiography showed a coffee-bean sign suggestive of sigmoid volvulus (Fig. 1). However, by extending the study with an abdominal computed tomography scan, a voluminous megarectum was detected (Fig. 2).

The causes of megarectum in adults include Hirschsprung disease, functional anorectal obstruction and certain neuroendocrine disorders, although it is frequently classified as idiopathic. Treatment is medical, involving enemas and laxatives; however, surgery can be necessary in refractory cases.

[☆] Please cite this article as: Romero Marcos JM, Carbonell Aliaga MP, Sbert Castañer L, Cifuentes Ródenas JA. Megarrecto condicionante de oclusión intestinal. Cir Esp. 2018;96:49.

^{*} Corresponding author.

E-mail address: jmromeromarcos@gmail.com (J.M. Romero Marcos).