



Image of the month

Esophageal Compression by Giant Zenker's Diverticulum[☆]



Compresión esofágica por divertículo de Zenker gigante

Clara Gené Skrabec, Marta Viciano Martín,^{*} Andrea Fernández Pujol, Elisenda Garsot Savall

Servicio de Cirugía General y Digestiva, Hospital Germans Trias i Pujol, Badalona, Barcelona, Spain

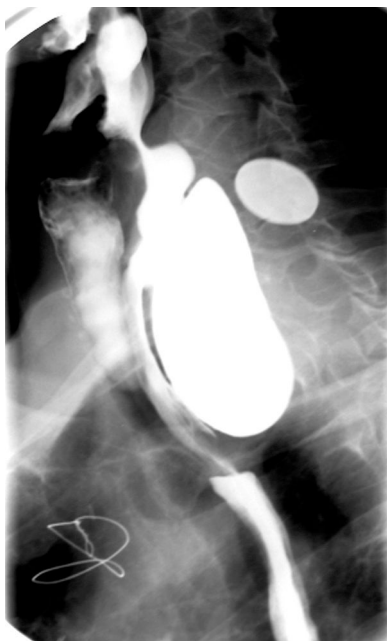

Figure 1

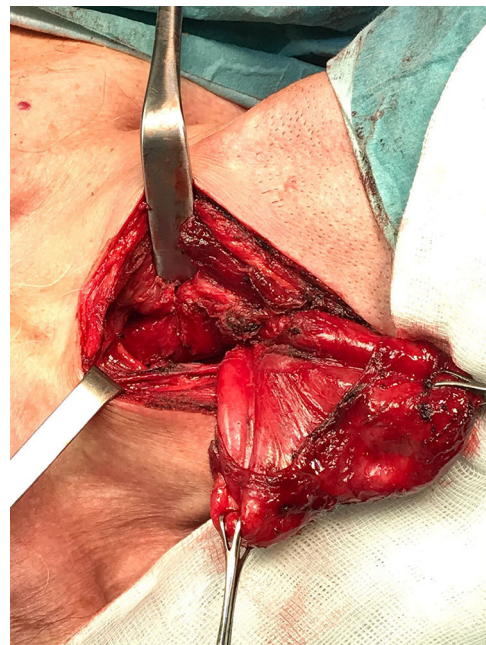


Figure 2

A 67-year old man, with history of ACS in 2005 treated with stenting by catheterism. The patient referred progressive dysphagia and history of regurgitation of liquid and solid intake.

In the last two years he experienced a 13 kg weight-loss associated with severe malnutrition (BMI: 19.7 kg/m²). The barium esophagogram (Fig. 1) showed a large Zenker's diverticulum conferring esophageal compression.

The surgical procedure consisted of a diverticulectomy of a large Zenker's diverticulum, which measured 6 cm, through left lateral cervicotomy (Fig. 2) and distal myotomy of the diverticulum's neck.

[☆] Please cite this article as: Gené Skrabec C, Viciano Martín M, Fernández Pujol A, Garsot Savall E. Compresión esofágica por divertículo de Zenker gigante. Cir Esp. 2019;97:108.

^{*} Corresponding author.

E-mail address: mviciano13@gmail.com (M. Viciano Martín).