



Image of the month

Metallic Bezoar After Suicide Attempt[☆]

Metalobezoar tras intento autolítico

Cristina Camacho Dorado,^{*} Alba Sánchez Gallego, Jose Ignacio Miota de Llama, Jose Antonio González Masiá

Cirugía General, Hospital General Universitario de Albacete, Albacete, Spain

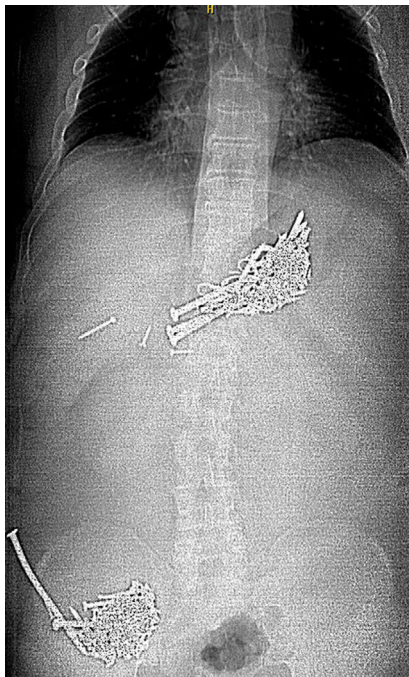


Fig. 1

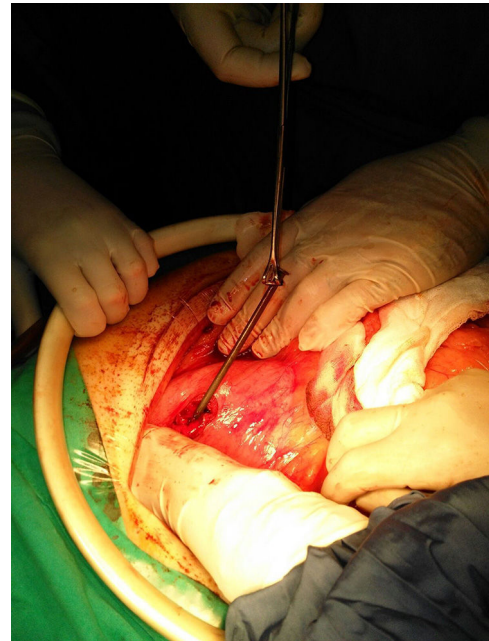


Fig. 2

The patient is a 44-year-old male with intellectual disability who, after intentional self-harm by swallowing a large number of metallic objects, went to the emergency department due to lower gastrointestinal bleeding, which was evident in the form of melena. Simple abdominal radiograph (Fig. 1) showed a gastric metal bezoar and another in the cecum, which were confirmed by abdominal CT. An attempt was made to remove the metal objects by fibrogastroscopy, which was not successful, so urgent laparotomy was conducted (Fig. 2). Gastrotomy and colotomy were performed and 238 screws and nails were extracted, with subsequent primary suture. The patient was discharged on the 8th postoperative day without incident.

[☆] Please cite this article as: Camacho Dorado C, Sánchez Gallego A, Miota de Llama JI, González Masiá JA. Metalobezoar tras intento autolítico. Cir Esp. 2018;96:515.

^{*} Corresponding author.

E-mail address: Criscd1989@gmail.com (C. Camacho Dorado).