



Image of the month

Wandering Spleen and Intestinal Malrotation ☆



Bazo errante y malrotación intestinal

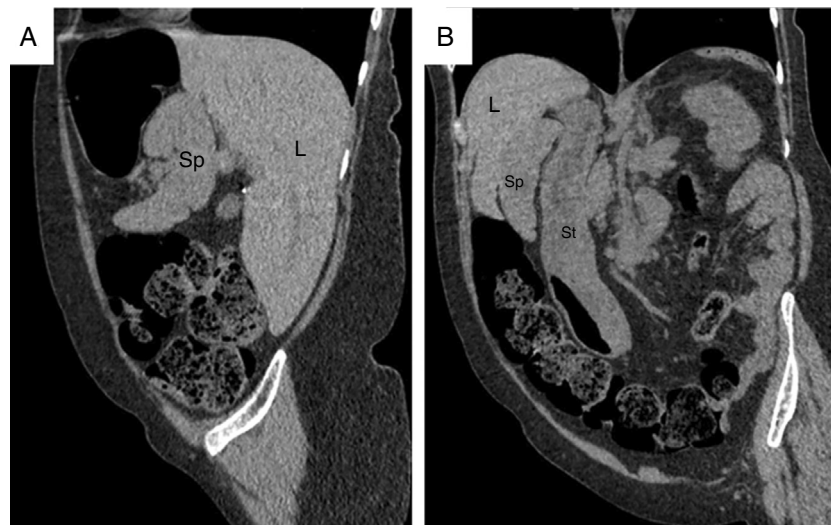
Bulent Guvendi,^a Hayri Ogul^{b,*}^a Department of General Surgery, Medical Faculty, Kafkas University, Kars, Turkey^b Department of Radiology, Medical Faculty, Ataturk University, Erzurum, Turkey

Fig. 1

A 62-year-old female was admitted to our hospital with intermittent abdominal distension over the past 6 months. Non-contrast CT scans showed an absence of the spleen in the left upper quadrant, as well as a spleen (Sp) in the liver (L) hilum (Fig. 1A and B). The stomach was shown in the right hypochondriac region in CT images, while the cecum had relocated to the left hypochondriac region.

☆ Please cite this article as: Guvendi B, Ogul H. Bazo errante y malrotación intestinal. Cir Esp. 2019;97:232.

* Corresponding author.

E-mail address: drhogul@gmail.com (H. Ogul).