

live donor it reaches 5%–13%⁷ and this increase is probably due to the hyperplasia and intimal fibrosis at the anastomotic sites, with compression and torsion of the anastomosis caused by the regeneration of the implant.⁸ We believe that, despite the absence of anastomosis, the growth of the lobe remaining after the second procedure⁹ can cause rotation given the presence of a large empty right subphrenic space and the lack of natural means of fixation that were divided during surgery. In addition, rapid hypertrophy with much earlier reoperation decreases the number of adhesions in collaboration with mobilization. The increasing use of new methods of liver resection may be associated with an increase in the diagnosis of this type of complications. To clarify, in this case it is possible that partial resection of the vena cava at the origin of the right and middle HV favors the development of this complication by partially reducing the caliber of the vena cava. Fixation of the falciform ligament should be considered in order to maintain correct anatomical position. Logically, the experience in this type of resection is generally limited, and time will tell which technical steps should be improved to minimize the number of negative outcomes.

The diagnosis and early treatment of a twisted suprahepatic vein is key and can be approached safely by hemodynamics. This complication should be kept in mind in patients with major resections and consequent contralateral hepatic hypertrophy.¹⁰

REFERENCES

- Schadde E, Ardiles V, Slankamenac K, Tschuor C, Sergeant G, Amacker N, et al. ALPPS offers a better chance of complete resection in patients with primarily unresectable liver tumors compared with conventional-staged hepatectomies: results of a multicenter analysis. *World J Surg.* 2014;38:1510–9.
- Robles R, Parrilla P, López-Conesa A, Brusadin R, de la Peña J, Fuster M, et al. Tourniquet modification of the associating liver partition and portal ligation for staged hepatectomy procedure. *Br J Surg.* 2014;101:1129–34. <http://dx.doi.org/10.1002/bjs.9547>. discussion 1134.
- Morales D, Robles R, Mañín C, Capel A, Vazquez V, Reus M, et al. Utilidad del cálculo del volumen hepático con tomografía computarizada en la planificación de resecciones

hepáticas mayores en pacientes no cirróticos. *Cir Esp.* 2004;76:152–8.

- Ogata S, Kianmanesh R, Belghiti J. Doppler assessment after right hepatectomy confirms the need to fix the remnant left liver in the anatomical position. *Br J Surg.* 2005;92:592–5.
- Umehara M, Narumi S, Sugai M, Toyoki Y, Ishido K, Kudo D, et al. Hepatic venous outflow obstruction in living donor liver transplantation: balloon angioplasty or stent placement? *Transplant Proc.* 2012;44:768–71.
- Shimara Y, Yamaoka Y. Vascular complications in hepatobiliary surgery pitfalls of surgery for advanced tumors. *Jpn Vasc Surg.* 2002;11:687–92.
- Umehara M, Narumi S, Sugai M, Toyoki Y, Ishido K, Kudo D, et al. Hepatic venous outflow obstruction in living donor liver transplantation: balloon angioplasty or stent placement? *Transplant Proc.* 2012;44:768–71.
- Egawa H, Tanaka K, Uemoto S, Someda H, Moriyasu F, Sano K, et al. Relief of hepatic vein stenosis by balloon angioplasty after living-related donor liver transplantation. *Clin Transplant.* 1993;7:306–11.
- Bertens KA, Hawel J, Lung K, Buac S, Pineda-Solis K, Hernandez-Alejandro R. ALPPS: challenging the concept of unresectability – a systematic review. *Int J Surg.* 2015;13:280–7. <http://dx.doi.org/10.1016/j.ijsu.2014.12.008>.
- Benesch M, Urban C, Deutschmann H, Hausegger KA, Hollwarth M. Management of Budd-Chiari syndrome by hepatic vein stenting after extended right hepatectomy. *J Gastrointest Surg.* 2010;14:910–2.

Enzo Giordano, Alvaro Alcaraz, Franco Jose Signorini, Marcos Marani, Lucio Ricardo Obeide

Departamento de Cirugía General, Hospital Privado Universitario de Córdoba, Córdoba, Argentina

*Corresponding author.

E-mail address: fransign@hotmail.com (F.J. Signorini).

2173-5077/

© 2018 AEC. Published by Elsevier España, S.L.U. All rights reserved.

Intestinal Obstruction Secondary to Hypogastric Artery Aneurysm[☆]

Obstrucción intestinal secundaria a aneurisma de arteria hipogástrica



Aneurysms of the iliac vessels are relatively uncommon, representing 0.4%–7%¹ of abdominal aneurysms. The

symptoms caused by this entity are related to vascular symptoms, such as pain or hemodynamic alterations. The

[☆] Please cite this article as: Gil Vázquez PJ, Gutierrez García F, Olivares Ripoll V, Ferreras Martínez D, Cánovas López SJ. Obstrucción intestinal secundaria a aneurisma de arteria hipogástrica. *Cir Esp.* 2018;96:593–595.

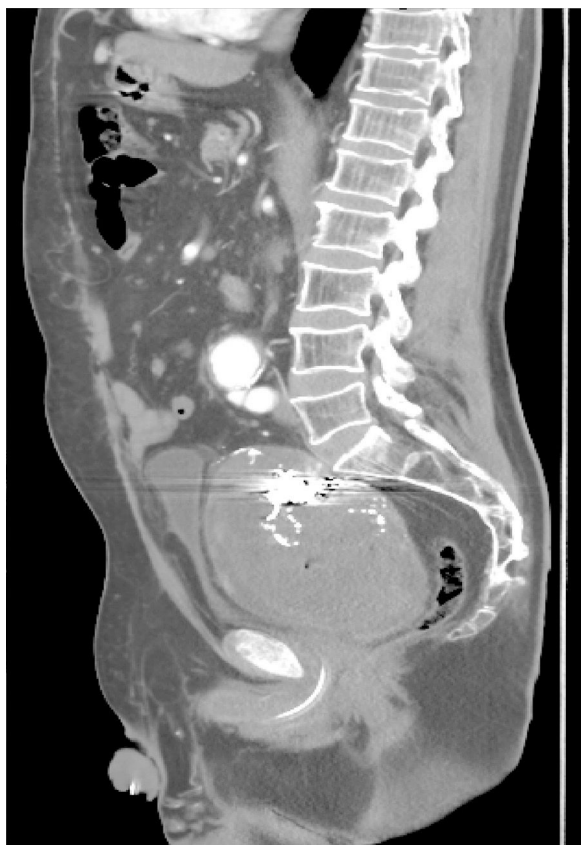

Fig. 1 – CT: aneurysm of the hypogastric artery compressing the rectum (sagittal view).

clinical symptoms of constipation and intestinal obstruction secondary to extrinsic compression of the colon or rectum by a vascular mass are extremely rare.

We present the case of a 71-year-old male patient who had been diagnosed 2 years earlier with abdominal aortic aneurysm and thrombosed left hypogastric artery aneurysm, treated with aortic-aortic bypass and ligation and exclusion of the latter. One year later, due to pain in the left iliac fossa, an endoleak of the hypogastric aneurysm was discovered; the sac was closed and embolized using interventional radiology (coils and biological glue), a procedure that needed to be repeated 8 months later for the same reason. Three months later, the patient consulted in the emergency department, this time for symptoms of constipation (but no difficulties for eliminating gas from the anus) and oliguria in the previous 3 weeks, with no other symptoms. A pelvic mass was palpated by rectal examination, which was compressing the rectal ampulla on the anterior and left sides; it was not pulsatile, suggestive of extrinsic compression, with no pathological products. Abdominal radiography showed mild dilatation of a few small intestine loops and the colon up to the descending colon. Ultrasound and angio-CT were performed, which demonstrated a pelvic mass compatible with a large thrombosed aneurysm of the left hypogastric artery filled with coils, which was compressing the rectum and bladder, and mild left hydronephrosis (Fig. 1). The patient was scheduled for surgery. Through an abdominal incision, the peritoneum was retracted

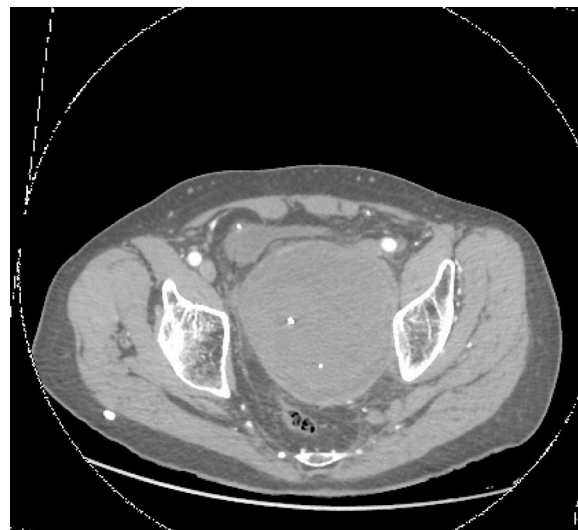


Fig. 2 – CT: aneurysm of the hypogastric artery compressing the rectum (axial view).

until the retroperitoneum was reached. An incision was made in the aneurysmal sac and the contents were extracted and cleaned, and a bleeding point in the sac was sutured as well (Fig. 2). On the first postoperative day, the patient was re-operated due to bleeding in the psoas muscle, and hemostasis was achieved. Pulmonary thromboembolism was also diagnosed, requiring the placement of a temporary filter in the vena cava and anticoagulation with low-molecular-weight heparins. Afterwards, the patient progressed favorably and was discharged.

Aneurysms of the iliac system usually occur more frequently in the common iliac vessels and usually as multiple aneurysms.¹ Isolated aneurysms of the internal iliac artery are rare (2%–7% of abdominal aneurysms^{1–3}). Many are due to arteriosclerosis, although it has been suggested that the replacement of an aortic aneurysm with a graft predisposes patients for hypogastric artery aneurysms.³ These are more frequent in older men. Urinary symptoms may appear as a result of the extrinsic compression on the bladder or ureters, or due to perianeurysmal fibrosis.⁴

Intestinal symptoms derived from this disease are uncommon, and may be due to intestinal adhesions or stenosis after the surgery of the aneurysm, postoperative intestinal ischemia, or bowel obstruction due to extrinsic compression.⁵ This last mechanism is extremely rare, and only 4 cases^{2,3,6–10} have been reported in the consulted literature. It should be suspected in patients with constipation and a pulsatile mass during digital rectal examination, although this sign is only found in 55% of internal iliac artery aneurysms.¹ This was not the case in our patient since the aneurysm was already thrombosed and treated endovascularly.

Endovascular treatment or surgery is recommended (resection, ligation of arterial branches and vascular reconstruction), since its natural course is progressive expansion and rupture.² In fact, when the latter occurs, there is high mortality, since they are usually located deep within the pelvis and difficult to resolve during bleeding. In our patient with bowel obstruction due to mass effect, repeating the

endovascular treatment did not make sense, so we opted for surgery. This disease must be considered in the differential diagnosis of intestinal obstruction. They should be considered abdominal emergencies, and elective surgery should be performed in those that are 3.5 cm in diameter.³

REFERENCES

- Richardson JW, Greenfield LJ. Natural history and management of iliac aneurysms. *J Vasc Surg.* 1988;8:165-71.
- Tasoglu I, Imren Y, Iriz E, Erer D. Rectal obstruction attributable to bilateral iliac aneurysms. *Surgery.* 2007;141:279-80.
- Gladman MA, Sayer GL. Clinical challenges and images in GI. Chronic constipation secondary to bilateral internal iliac artery aneurysms. *Gastroenterology.* 2008;134:1294-636.
- Netto R Jr, Caserta Lemos G, Ikari O, Bastouly M. Urologic aspects associated with isolated hypogastric artery aneurysm. *Urology.* 1986;28:486-8.
- Lane T, Bentley P. Rectal strictures following abdominal aortic aneurysm surgery. *Ann R Coll Surg Engl.* 2000;82:421-3.
- Sugimoto A, Haga M, Motohashi S, Takahashi Y, Kanazawa H, Nakazawa S. A case of rectal obstruction caused by bilateral internal iliac artery aneurysms. *Ann Vasc Surg.* 2011;25:267-315.
- Ufuk Ö, Vatansev C, Durgut K, Özülkü M, Yaşı Görmüş N. An internal iliac artery aneurysm causing a colonic obstruction: report of a case. *Surg Today.* 2001;31:839-41.

- Morita S, Yamaguchi M, Yamagiwa T, Inokuchi S. Constipation following bilateral internal iliac artery aneurysms. *J Emer Med Trauma Acute Care.* 2012;25:1-3.
- Mencia AJ, Hines GL. Internal iliac artery aneurysm presenting as severe constipation. A case report. *Vasc Endovascular Surg.* 1999;33:313-6.
- Elkouri S, Blair JF, Beaudoin N, Bruneau L. Ruptured solitary internal iliac artery aneurysm: a rare cause of large-bowel obstruction. *Can J Surg.* 2008;51:E122-3.

Pedro José Gil Vázquez^a, Francisco Gutierrez García^b, Vicente Olivares Ripoll^a, David Ferreras Martínez^a, Sergio J. Cánovas López^b

^aServicio de Cirugía General y Aparato Digestivo, Hospital Clínico Universitario Virgen de la Arrixaca, El Palmar, Murcia, Spain

^bServicio de Cirugía Cardiovascular, Hospital Clínico Universitario Virgen de la Arrixaca, El Palmar, Murcia, Spain

*Corresponding author.

E-mail address: pedro_jgv@hotmail.com (P.J. Gil Vázquez).

2173-5077/

© 2018 AEC. Published by Elsevier España, S.L.U. All rights reserved.

Bilateral Retroperitoneal Hibernoma Identified by I-MIBG SPECT/GT in a Patient With Single Pheochromocytoma[☆]



Hibernoma retroperitoneal bilateral identificado por I-MIBG SPECT/TC en un paciente con feocromocitoma unilateral

Hibernomas are extremely rare benign tumors that arise from vestigial remnants of brown adipose tissue. Their characteristic color is due to the presence of numerous pleomorphic mitochondria and significant vascular irrigation.¹ In adults, hibernomas are more common in men, with a maximum incidence in the third and fourth decades of life. Their function is thermoregulatory, and they are found more frequently in the central parts of the body, where brown adipocytes accumulate²: mediastinal, retroperitoneal, cervical, axillary and interscapular.³ In most cases, hibernomas present as asymptomatic masses. However, they may present as incidental findings on imaging tests, rarely causing symptoms

related to the compression of adjacent structures.⁴ Unlike adipose tissue, brown fat contains abundant phospholipids and glycogen, which are metabolized⁵ and supply energy, which is obtained in the form of heat. This capability depends on the presence of abundant mitochondria and the expression of UCP1 (uncoupling protein 1). In addition, it also differs from adipose fat by having significant innervation. Pheochromocytoma, a pathological condition characterized by high adrenergic activation, has been associated with hibernomas,⁶ and most cases are discovered incidentally on contrast imaging tests, which indicates that the expression of UCP1 can be induced in certain tumors⁷ and metabolic alterations.⁸

[☆] Please cite this article as: Lévano-Linares DC, Ruiz-Tovar J, García Muñoz-Najar A, Familiar V, Durán Poveda M. Un caso raro de hibernoma retroperitoneal bilateral identificado por ¹²³I-MIBG SPECT/TC en un paciente con feocromocitoma unilateral. *Cir Esp.* 2018;96:595-597.