



## Image of the Month

Appendiceal Diverticulitis as a Cause of Acute Appendicitis<sup>☆</sup>

## Diverticulitis apendicular como causa de apendicitis aguda

Vicent Primo Romaguera,<sup>a,\*</sup> Abel Gregorio Hernández,<sup>b</sup> Elena Bragin,<sup>c</sup>  
Juan José Arroyo Martín<sup>a</sup>

<sup>a</sup> Servicio de Cirugía General y Digestiva, Hospital de Dénia Marina-Salud, Dénia, Alicante, Spain

<sup>b</sup> Servicio de Radiología, Hospital de Dénia Marina-Salud, Dénia, Alicante, Spain

<sup>c</sup> Servicio de Anatomía Patológica, Hospital de Dénia Marina-Salud, Dénia, Alicante, Spain

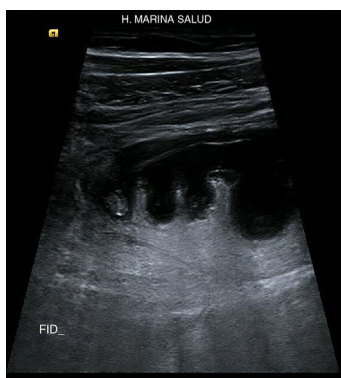

Fig. 1

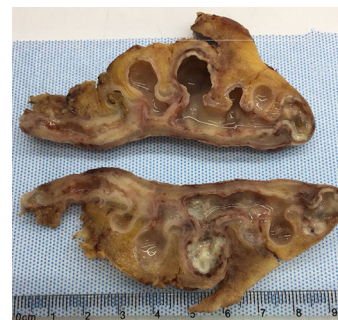


Fig. 2

A 69-year-old male patient was referred to the emergency department for a symptoms compatible with acute appendicitis over the previous 3 days. Blood work detected leukocytosis. Abdominal ultrasound revealed a fixed tubular structure in the right iliac fossa with loss of layer differentiation, showing an axial diameter of 13 mm and associated inflammatory signs of the pericecal fat, compatible with acute appendicitis. Ultrasound also detected the presence of appendiceal diverticula (Fig. 1).

During laparoscopic appendectomy, diverticulitis of the appendix was observed, a finding that was confirmed in the pathology report. Fig. 2 shows the presence of diverticula in the wall of the cecal appendix in the histological study.

## Authorship

Vicent Primo Romaguera: clinical evaluation, data collection, composition and supervision.

Abel Gregorio: diagnostic technique.

Elena Bragin: diagnostic technique and study review.

Juan José Arroyo: review and coordination.

<sup>☆</sup> Please cite this article as: Primo Romaguera V, Hernández AG, Bragin E, Arroyo Martín JJ. Diverticulitis apendicular como causa de apendicitis aguda. Cir Esp. 2019;97:53.

\* Corresponding author.

E-mail address: [sentopr@gmail.com](mailto:sentopr@gmail.com) (V. Primo Romaguera).