



## Image of the month

Amyand Hernia<sup>☆</sup>

## Hernia de Amyand

María Luisa Nieto Morales,<sup>\*</sup> Yasmín El Khatib Ghzal, Efrén Santana Medina

Hospital Universitario Nuestra Señora de Candelaria, Santa Cruz de Tenerife, Spain

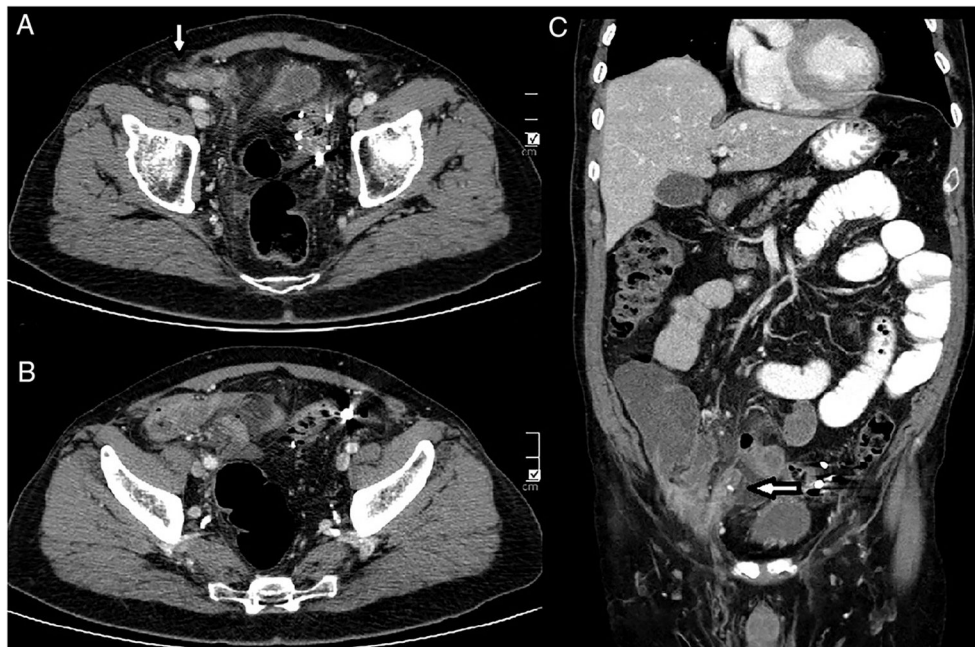


Fig. 1

Our patient had a history of diverticulosis and came to the Emergency Department due to hypogastric abdominal pain that had been progressing for 3 days, associated with vomiting and fever. During physical examination, pain and guarding were evident in that region.

We decided to operate after an imaging study (Fig. 1) revealed an indirect inguinal hernia and a swollen appendix within the herniated tissue (Amyand hernia).

The presence of the cecal appendix inside the inguinal hernia sac is called De Garengeot hernia (1% prevalence worldwide), while a hernia sac containing the appendix is known as Amyand hernia (0.13% worldwide prevalence), which can simulate a strangulated hernia.

Although Amyand hernia is a rare entity, one must be aware of its existence and suspect its presence in cases with a complicated right inguinal hernia in order to make a correct preoperative diagnosis.

<sup>☆</sup> Please cite this article as: Nieto Morales ML, El Khatib Ghzal Y, Santana Medina E. Hernia de Amyand. Cir Esp. 2019;97:408.

<sup>\*</sup> Corresponding author.

E-mail address: [luisaradazul@yahoo.es](mailto:luisaradazul@yahoo.es) (M.L. Nieto Morales).