

## REFERENCES

1. Huang L, Jansen L, Balavarca Y, Babaei M, Van der Geest L, Lemmens V, et al. Stratified survival of resected and overall pancreatic cancer patients in Europe and the USA in the early twenty-first century: a large, international population-based study. *BMC Med.* 2018;16:125. <http://dx.doi.org/10.1186/s12916-018-1120-9>.
2. Pancreatic adenocarcinoma clinical guidelines in Oncology. National Comprehensive Cancer Network. NCCN; April 2019.
3. Yang SJ, Hwang HK, Kang Ch M, Lee WJ. Preoperative defining system for pancreatic head cancer considering surgical resection. *World J Gastroenterol.* 2016;22:6076-82. <http://dx.doi.org/10.3748/wjg.v22i26.6076>.
4. Ardengh JC, Lopes CV, de Lima-Filho ER, Kemp R, dos Santos JS. Impact of endoscopic ultrasound-guided fine-needle aspiration on incidental pancreatic cysts. A prospective study. *Scand J Gastroenterol.* 2014;49:114-20. <http://dx.doi.org/10.3109/00365521.2013.854830>.
5. Hirono S, Tani M, Kawai M, Okada H, Miyazawa M, Shimizu A, et al. Identification of the lymphatic drainage from the pancreatic head guided by indocyanine green fluorescence imaging during pancreaticoduodenectomy. *Dig Surg.* 2012;29:132-9. <http://dx.doi.org/10.1159/000337306>.
6. He M, Jiang Z, Wang C, Hao Z, An J, Shen J. Diagnosis value of near-infrared or fluorescent indocyanine green guided sentinel lymph node mapping in gastric cancer: a systematic review and meta-analysis. *J Surg Oncol.* 2018;118:1243-56. <http://dx.doi.org/10.1002/jso.25285>.
7. Guo J, Yang H, Wang S, Cao Y, Liu M, Xie F, et al. Comparison of sentinel lymph node biopsy guided by indocyanine green, blue dye and their combination in breast cancer patients: a prospective cohort study. *World J Surg Oncol.* 2017;15:196. <http://dx.doi.org/10.1186/s12957-017-1264-7>.
8. Rho SY, Kim JS, Chong JU, Hwang HK, Yoon DS, Lee WJ, et al. Indocyanine green perfusion imaging-guided laparoscopic pancreaticoduodenectomy: potential application in retroperitoneal margin dissection. *J Gastrointest Surg.* 2018;22:1470-4. <http://dx.doi.org/10.1007/s11605-018-3760-7>.
9. Paiella S, de Pastena M, Landoni L, Esposito A, Casetti L, Miotto M, et al. Is there a role for near-infrared technology in laparoscopic resection of pancreatoneuroendocrine tumors? Results of the COLPAN "color and resect the pancreas" study. *Surg Endosc.* 2017;31:4478-84. <http://dx.doi.org/10.1007/s00464-017-5501-5>.
10. Dasari B, Pasquali S, Vohra R, Smith A, Taylor M, Sutcliffe R, et al. Extended versus standard lymphadenectomy for pancreatic head cancer: meta-analysis of randomized controlled trial. *J Gastrointest Surg.* 2015;19:1725-32. <http://dx.doi.org/10.1007/s11605-015-2859-3>.
11. Van den broeck A, Sergeant G, Ectors N, van Steenberg W, Aerts R, Topal B. Patterns of recurrence after curative resection of pancreatic ductal adenocarcinoma. *Eur J Surg Oncol.* 2009;35:600-4. <http://dx.doi.org/10.1016/j.ejso.2008.12.006>.
12. Kanda M, Fujii T, Nagai S, Kodera Y, Kanzaki A, Sahin TT, et al. Pattern of lymph node metastasis spread in pancreatic cancer. *Br J Cancer.* 2011;40:951-5. <http://dx.doi.org/10.1097/MPA.0b013e3182148342>.
13. Baiocchi GL, Diana M, Boni L. Indocyanine green-based fluorescence imaging in visceral and hepatobiliary and pancreatic surgery: state of the art and future directions. *World J Gastroenterol.* 2018;24:2921-30. <http://dx.doi.org/10.3748/wjg.v24.i27.2921>.

Carlota Matallana\*, Fernando Pardo, Francisco Espín, Manel Cremades, Esteban Cugat

Unidad de Cirugía Hepatobiliopancreática, Hospital Universitari Germans Trias i Pujol, Badalona (Barcelona), Spain

\*Corresponding author.

E-mail address: [carlota.matallana@gmail.com](mailto:carlota.matallana@gmail.com)

(C. Matallana).

2173-5077/

© 2020 AEC. Published by Elsevier España, S.L.U. All rights reserved.

## Uterine Incisional Hernia in a Pregnant Patient<sup>☆</sup>

### Eventración uterina en paciente gestante



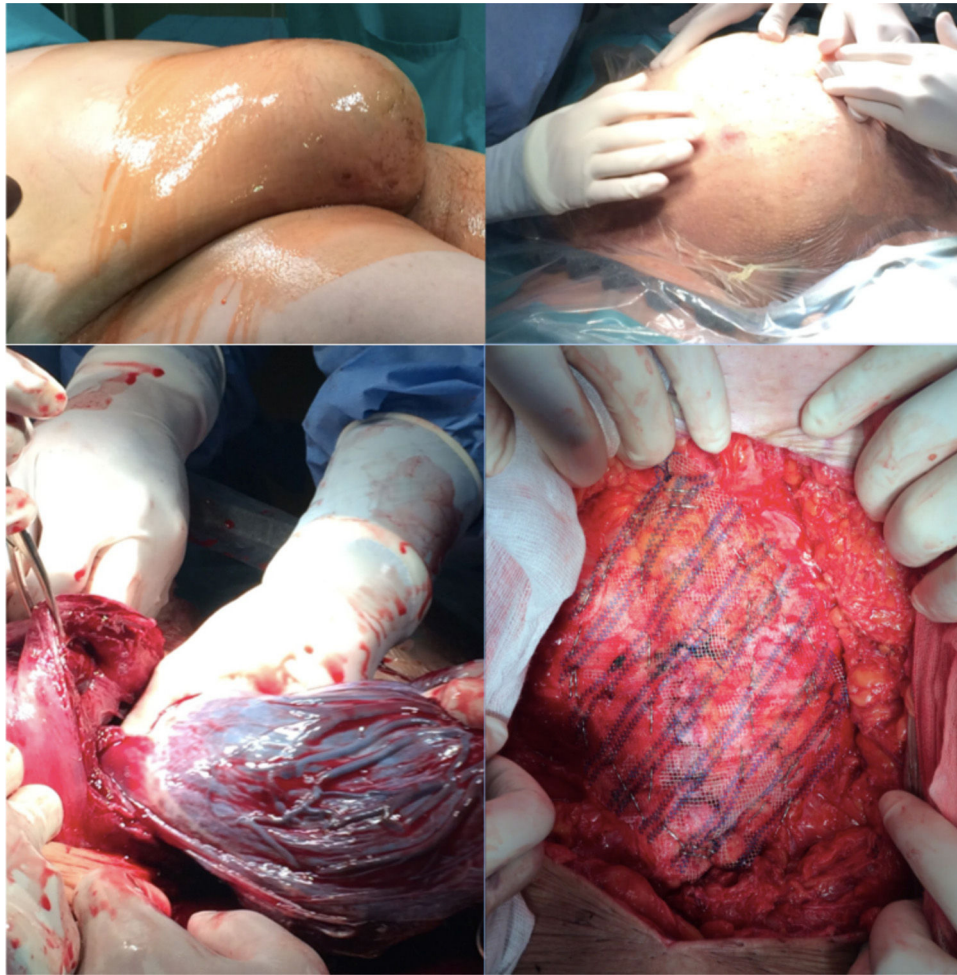
Incisional hernia after abdominal surgery has an incidence between 5% and 15%.<sup>1</sup> Pregnancy after abdominal surgery is an independent risk factor for the development of an incisional hernia,<sup>2</sup> and herniation of the gravid uterus through an incisional hernia is very rare.<sup>3</sup>

Complications associated with the appearance of this condition during pregnancy as a possible incarceration or

strangulation are a serious obstetric problem with important consequences for both the mother and the fetus.

Due to its low incidence, there is no consensus regarding management, which requires individualized treatment.<sup>4</sup> In uncomplicated hernias, initial conservative management with abdominal wall repair either intrapartum or in a second stage seems to be a good option.<sup>5</sup>

<sup>☆</sup> Please cite this article as: Camacho Marente V, Olivares Oliver C, Marchal Santiago A, Martín Cartes JA, Bustos Jiménez M. Eventración uterina en paciente gestante. *Cir Esp.* 2020;98:303-305.



**Fig. 1 – Incisional hernia with uterus inside, delivery and placement of preaponeurotic mesh.**

We present a case of incisional hernia of a gravid uterus in a 34-year-old pregnant patient, who was referred to our unit at week 30 + 1 for suspected uterine herniation. The patient had a history of a previous cesarean section with an infraumbilical midline laparotomy and grade III obesity (weight: 135.4 kg and BMI: 49.1) and was being monitored for her high risk of gestational diabetes.

The first trimester of pregnancy passed without incident, but in week 20 of gestation the patient experienced hypogastric pain that prevented her from sitting. During examination, an irreducible tumor was detected at the level of the cesarean section scar. An ultrasound of the abdomen during an office visit revealed a uterine hernia, with no alterations in the fetus.

At week 30 + 1, our team was contacted for evaluation. During the examination, we observed an abdomen corresponding to the weeks of gestation and an incisional hernia through the infraumbilical scar, which became more evident with Valsalva maneuvers. The presence of uterine herniation was confirmed by follow-up ultrasound. Given the complexity of the case, we opted for a multidisciplinary approach with the gynecology team, proposing elective cesarean section, tubal

ligation at the express request of the patient, and incisional hernia repair during the same operation, scheduled for week 38 of pregnancy.

Access was created through the previous incision, and the hernia sac was opened to access the uterus placed in forced anteversion position, which required manipulation to visualize the lower segment and conduct hysterotomy using a Kerr incision (transverse incision of the lower segment). The cesarean section was uneventful, giving birth to a live female fetus in transverse position; bilateral tubal occlusion was performed by simple ligation and partial salpingectomy. In the second stage of surgery, an M4W2 incisional hernia was observed (European Hernia Surgery classification) with an aponeurotic defect measuring 15 cm in length and 7 cm wide. Given the laxity of the abdominal wall, a repair was performed with primary closure using continuous suture of a caliber 0 slow-absorbing monofilament suture material following a 4:1 ratio, placement of a 25 cm × 15 cm polypropylene mesh onlay with a wide pore (1.5 mm) and low weight (60 g/m<sup>2</sup>), affixed with a double crown of non-absorbable fascia tacks and a minimum overlap of 5 cm, followed by the placement of 2 subcutaneous suction drains, all of which proceeded without

incident (Fig. 1). The postoperative period was favorable, and the patient was discharged on the 8th postoperative day after confirming no drain discharge.

Two years after the procedure, the patient had a follow-up office visit, at which time there was no evidence of hernia recurrence.

The incidence of incisional hernia during pregnancy is unknown, but it is very rare in Western countries.<sup>3</sup> For this reason, there is not enough evidence about its management, so individualized management should be based on the characteristics of the mother, fetus and gestation.

The most frequent symptoms and signs are abdominal pain, vomiting and the appearance of a mass in the region of the previous scar. During examination, a palpable defect can be found in the wall with either reducible or non-reducible content and sometimes abdominal distension.<sup>5-7</sup> To complete the study, abdominal ultrasound is usually sufficient to determine which structures are contained in the hernia sac. However, sometimes MRI is indicated when the ultrasound does not provide a clear diagnosis.

Once the diagnosis has been made, it is essential to monitor the pregnancy in order to detect uterine changes that could result in delayed intrauterine growth of the fetus. Risk factors associated with this complication have been described, including advanced age, polyhydramnios and multiple gestation.

Although the literature includes approaches during the first months of gestation, both anesthesia and surgery can lead to an increased risk of complications for the mother and the fetus. Therefore, most authors advocate repair during elective cesarean section or in a second phase. In the case of complications, emergency surgery is mandatory. Uterine strangulation in full-term pregnancies is an indication for urgent laparotomy, cesarean section and wall repair in the same operation. When the complication occurs in the early stages of pregnancy, urgent repair of the defect is indicated, assessing fetal viability and continuing gestation if possible.<sup>5,7</sup>

## Funding

This publication has not required any type of funding.

## REFERENCES

1. Lopez Cano M. Cirugía basada en la evidencia y hernia incisional. *Cir Esp*. 2013;1:18-26.
2. Oma E, Jensen KK, Jorgensen LN. Increased risk of ventral hernia recurrence after pregnancy: a nationwide register-based study. *Am J Surg*. 2017;214:474-8. <http://dx.doi.org/10.1016/j.amjsurg.2017.03.044>.
3. Augustin G, Matosevic P, Kekez T, Majerovic M, Delmis J. Abdominal hernias in pregnancy. *J Obstet Gynaecol Res*. 2009;35:203-11.
4. Uchenna EG, Chukwuneme OB, Ejike ES, Mbanefo OP, Benjamin ET. Herniated near-term pregnancy through an incisional hernia treated with polypropylene mesh: a case report. *Niger Med J*. 2014;55:271-3.
5. Saha PK, Rohilla M, Prasad GR, Dhaliwal LK, Gupta I. Herniation of gravid uterus: report of two cases and review of literature. *MedGenMed*. 2006;8:14.
6. Punguyire D, Iserson KV, Apanga S. Fullterm pregnancy in umbilical hernia. *Pan Afr Med J*. 2011;8:6.
7. Ray KK, Aggarwal S, Banerjee K, Karan S, Charu C. Gravid uterus in an incisional hernia leading to burst abdomen. *Internet J Gynecol Obstet*. 2005;5:2-5.

Violeta Camacho Marente<sup>a,\*</sup>, Claudia Olivares Oliver<sup>b</sup>, Amando Marchal Santiago<sup>c</sup>, Juan Antonio Martin Cartes<sup>d</sup>, Manuel Bustos Jimenez<sup>d</sup>

<sup>a</sup>Servicio de Cirugía General y del Aparato Digestivo, Hospital Universitario Puerta del Mar, Cádiz, Spain

<sup>b</sup>Servicio de Cirugía General y del Aparato Digestivo, Hospital San Juan de Dios del Aljarafe, Sevilla, Spain

<sup>c</sup>Servicio de Cirugía General y del Aparato Digestivo, Hospital Infanta Margarita, Córdoba, Spain

<sup>d</sup>Servicio de Cirugía General y del Aparato Digestivo, Hospital Universitario Virgen del Rocío, Sevilla, Spain

\*Corresponding author.

E-mail address: [violeta.camachomarente@gmail.com](mailto:violeta.camachomarente@gmail.com) (V. Camacho Marente).

2173-5077/

© 2020 AEC. Published by Elsevier España, S.L.U. All rights reserved.