



Image of the month

Sister Mary Joseph's Nodule as Initial Presentation of Pancreatic Adenocarcinoma[☆]



Nódulo de la hermana María José como presentación inicial de adenocarcinoma pancreático

Blanca Capdevila,^a Montserrat Guasch,^{b,*} Enric Sebastián-Valverde,^b Pere Gris^b

^a Servicio de Cirugía Pediátrica, Hospital Sant Joan de Déu Barcelona, Esplugues de Llobregat, Barcelona, Spain

^b Servicio de Cirugía General y del Aparato Digestivo, Parc Sanitari Sant Joan de Déu, Sant Boi de Llobregat, Barcelona, Spain

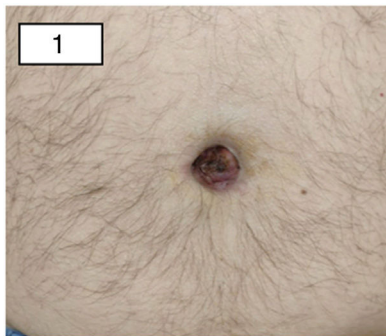


Figure 1

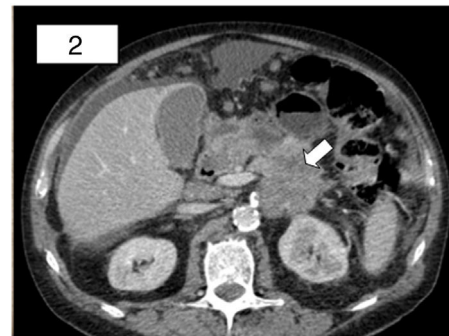

Figure 2

A 60-year-old man came to the emergency department due to persistent omphalitis, treated with antibiotic therapy, that had been progressing for 4 months. He reported lower back pain with no evident toxic symptoms. On examination, a hard umbilical mass was observed with seropurulent discharge (Fig. 1).

Computed tomography revealed a pancreatic tumor with extensive local invasion (Fig. 2), as well as peritoneal carcinomatosis with multiple implants, one in the umbilical region. The pathology results of the umbilical nodule identified adenocarcinoma of pancreatic–biliary origin, which confirmed the diagnosis of Sister Mary Joseph's nodule. After evaluation by the multidisciplinary committee, treatment with palliative chemotherapy was started.

[☆] Please cite this article as: Capdevila B, Guasch M, Sebastián-Valverde E, Gris P. Nódulo de la hermana María José como presentación inicial de adenocarcinoma pancreático. Cir Esp. 2020;98:293.

* Corresponding author.

E-mail address: guasch333@gmail.com (M. Guasch).