



## Video of the month

# Choledochal Varices: An Uncommon Cholangioscopic Finding<sup>☆</sup>

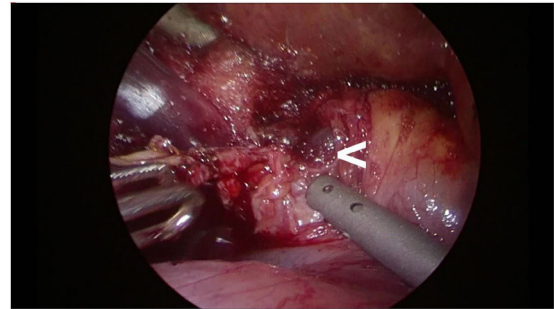


## Varices coledocianas: un hallazgo colangioscópico infrecuente

Fátima Senra Lorenzana,\* Lalin Navaratne, Alberto Martínez Isla

Servicio de Cirugía General y del Aparato Digestivo, St Mark's Hospital and Academic Institute, London, UK

The patient is 74-year-old woman with a history of acute pancreatitis with calculi and portal cavernoma due to chronic portal thrombosis. With a suspected diagnosis of symptomatic cholelithiasis and choledocholithiasis based on ultrasound findings, elevated enzymes associated with cholestasis and bilirubin, cholecystectomy was indicated with intraoperative exploration of the laparoscopic bile duct. During the procedure, varicose veins were observed in the hepatic hilum. Bile duct stones were extracted through the cystic duct, and varicose veins were found in its lumen. Hemorrhage occurred during transection of the cystic duct, which was controlled by suturing. Postoperative evolution was favorable. Choledochal varices are an uncommon, late manifestation of portal hypertension.



### Diagnosis

Choledochal varicose veins due to cavernous transformation of the portal vein.

### Appendix A. Supplementary Data

Supplementary material related to this article can be found, in the online version, at doi:<https://doi.org/10.1016/j.ciresp.2019.12.010>.

<sup>☆</sup> Please cite this article as: Senra Lorenzana F, Navaratne L, Martínez Isla A. Varices coledocianas: un hallazgo colangioscópico infrecuente. Cir Esp. 2020;98:361.

\* Corresponding author.

E-mail address: [fatimassenra664@gmail.com](mailto:fatimassenra664@gmail.com) (F. Senra Lorenzana).