



Image of the month

Gastric Diverticulum as an Incidental Finding in a 16-year-old Patient[☆]



Divertículo gástrico congénito como hallazgo casual en paciente de 16 años

Carlos Leganés Villanueva,^{a,*} Mireia Fernández Castilla,^a Juan Carlos Pernas Canadell,^b Ilaria Goruppi^a

^a Servicio de Pediatría, Sección de Cirugía Pediátrica, Hospital Universitario de la Santa Creu i Sant Pau, Barcelona, Spain

^b Servicio de Radiología, Hospital Universitario de la Santa Creu i Sant Pau, Barcelona, Spain

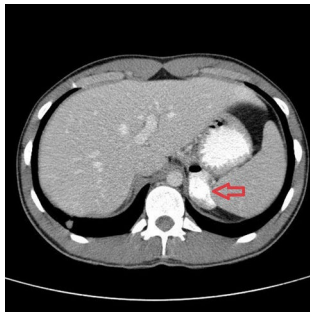


Fig. 1

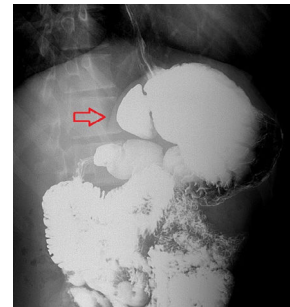


Fig. 2

A 16-year-old male patient came to the emergency department with multiple trauma injuries. During physical examination, abrasions were observed on the abdomen. Laboratory test results were normal, including urine levels.

A possible gastric diverticulum was identified on computed tomography scan (Fig. 1). The diagnosis was confirmed with an upper GI series (Fig. 2).

Gastric diverticulum is a condition with a low incidence and few reported cases (almost none in the pediatric population). They are usually located in the gastric fundus and are congenital in origin. Management is usually conservative, although surgical or endoscopic resection are the most accepted treatments for cases with accompanying symptoms. Diagnosis: Incidental finding of congenital gastric diverticulum.

[☆] Please cite this article as: Leganés Villanueva C, Fernández Castilla M, Pernas Canadell JC, Goruppi I. Divertículo gástrico congénito como hallazgo casual en paciente de 16 años. Cir Esp. 2020;98:360.

* Corresponding author.

E-mail address: cleganes@santpau.cat (C. Leganés Villanueva).