

- children: a review of medical and surgical management at a tertiary care center. *Pediatrics*. 2006;118:1109-17.
4. Lenders JWM, Duh Q-Y, Eisenhofer G, Gimenez-Roqueplo AP, Grebe SK, Murad MH, et al. Endocrine Society. Pheochromocytoma and paraganglioma: an endocrine society clinical practice guideline. *J Clin Endocrinol Metabolism*. 2014;99:1915-42.
 5. Giavarini A, Chedid A, Bobrie G, Ploulin PF, Hagege A, Amar L, et al. Acute catecholamine cardiomyopathy in patients with phaeochromocytoma or functional paraganglioma. *Heart*. 2013;99:1438-44.
 6. Banfi C, Juthier F, Ennezat PV, de Saint Denis T, Carnaille B, Leteurtre E, et al. Central extracorporeal life support in pheochromocytoma crisis. *Ann Thorac Surg*. 2012;93:1303-5.
 7. Plouin PF, Fitzgerald P, Rich T, Ayala-Ramirez M, Perrier ND, Baudin E, et al. Metastatic pheochromocytoma and paraganglioma: focus on therapeutics. *Horm Metab Res*. 2012;44:390-9.

María Asunción Acosta-Mérida^a,
José Silvestre-Rodríguez^{a,*}, José Miguel Hernández-Ramírez^b,
Cristian Godoy^b, Joaquín Marchena-Gómez^a

^aServicio de Cirugía General y Digestiva, Hospital Universitario de Gran Canaria Dr. Negrín, Gran Canaria, Spain

^bServicio de Cardiología, Hospital Universitario de Gran Canaria Dr. Negrín, Gran Canaria, Spain

*Corresponding author.

E-mail address: drsilvestre@gmail.com

(J. Silvestre-Rodríguez).

2173-5077/

© 2019 AEC. Published by Elsevier España, S.L.U. All rights reserved.

Thoracoscopic Approach of Iatrogenic Superior Vena Cava Perforation After Dialysis Catheter Placement[☆]



Abordaje toracoscópico de perforación iatrogénica de vena cava superior por catéter de diálisis

Central venous catheters for hemodialysis provide reliable access for dialysis in end-stage patients with chronic kidney disease¹ using a less invasive, percutaneous approach. Iatrogenic injury to venous vessels can occur during placement of these catheters. Rupture or perforation of the superior vena cava (SVC) is an uncommon but potentially fatal complication.

We present the case of a 59-year-old woman with a history of hypertension, dyslipidemia, secondary hyperparathyroidism and adult polycystic liver disease with stage V chronic kidney disease requiring dialysis. She was admitted for the placement of a tunneled catheter through the right jugular vein, after which she suddenly began to have pleuritic chest pain. Given the clinical manifestations, contrast medium was introduced through the catheter under fluoroscopic control, which showed extravasation to the right hemidiaphragm. We decided to perform computed tomography angiography (CT angiogram) (Fig. 1), which showed that the catheter had perforated the vein at the right jugular-subclavian junction, with associated hemothorax. The patient was transferred to the intensive care unit for monitoring and evacuation of the hemothorax through a chest tube, while remaining hemody-

namically stable. After multidisciplinary assessment by vascular surgery and thoracic surgery specialists, a video-assisted surgical procedure was performed (Fig. 2A) with two ports: one optical trocar, and one minithoracotomy.

Once the extravasation point was located, hemostatic control was established using Prolene[®] 3/0 sutures proximal and distal to the perforated catheter. This allowed for it to be removed proximally, with closure of the defect (Fig. 2B and C). After confirmation of hemostasis, placement of Surgicel[®] on the venous suture and evacuation of the hemothorax, we proceeded with chest tube insertion and closure of the assistance minithoracotomy.

The patient progressed well. The thoracic drain tube was removed on the 2nd postoperative day, and the patient was discharged from the intensive care unit on the 4th day. After follow-up in the hospital without incidents, she was discharged on the 7th postoperative day.

Although the placement of central venous catheters is a therapeutic possibility in patients in need of dialysis, the technique is not without risks. Venous vessel rupture is an uncommon but possible and potentially life-threatening com-

[☆] Please cite this article as: Sánchez Matás C, Manresa Manresa F, Andrades Sardiña D, López Villalobos JL, Bataller de Juan ME. Abordaje toracoscópico de perforación iatrogénica de vena cava superior por catéter de diálisis. *Cir Esp*. 2020;98:364-366.

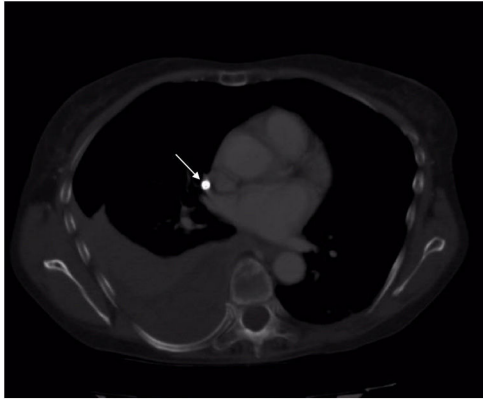

Fig. 1 – Thoracic CT angiogram with extravasation of the central venous catheter (arrow) and associated hemothorax.

plication, especially when the SVC is compromised. To prevent these complications, ultrasound-guided catheter insertion has been shown to increase the safety of the procedure.^{2,3}

The manifestations of SVC perforation, such as hemothorax or cardiac tamponade, will lead to the need for urgent treatment to save the patient's life when they cause hemodynamic instability. However, it is possible to adapt both the time of the intervention and the technique when the clinical situation allows it. The diagnosis is based on the

injection of contrast through the catheter under radiological control, which shows evidence of extravasation,^{2,4,5} or by means of high-resolution imaging tests (CT angiography). In addition, transesophageal/trans thoracic bedside ultrasound is an alternative in unstable patients that provides diagnostic confirmation and facilitates the initiation of therapeutic measures (pericardiocentesis).^{2,4,6}

The aim of treatment is to repair the injured vessel and recover cardiac function, when compromised.⁴ Open SVC repair requires median sternotomy, which is an aggressive and complex alternative for many of our patients.^{5,7} To reduce the morbidity associated with this approach, therapeutic alternatives such as the endovascular approach^{4,8} have been described, with the placement of stents providing good results. Likewise, in certain stable patients with no signs of cardiac tamponade, conservative management could be a therapeutic modality.⁹ In the case of cardiac tamponade, pericardiocentesis should have priority over the vessel repair.⁴

Although endovascular repair is a therapeutic alternative in patients with ruptured SVC, the location of the injury may determine its chances of success. In our case, given the confluence of the jugular vein with the subclavian vein in the perforation area, the VATS approach was considered the first therapeutic option in a hemodynamically stable patient with no signs of cardiac tamponade.

Based on our review of the literature, this is the third case report^{7,10} that includes VATS as a therapeutic option in the treatment of SVC rupture. Although it has been considered

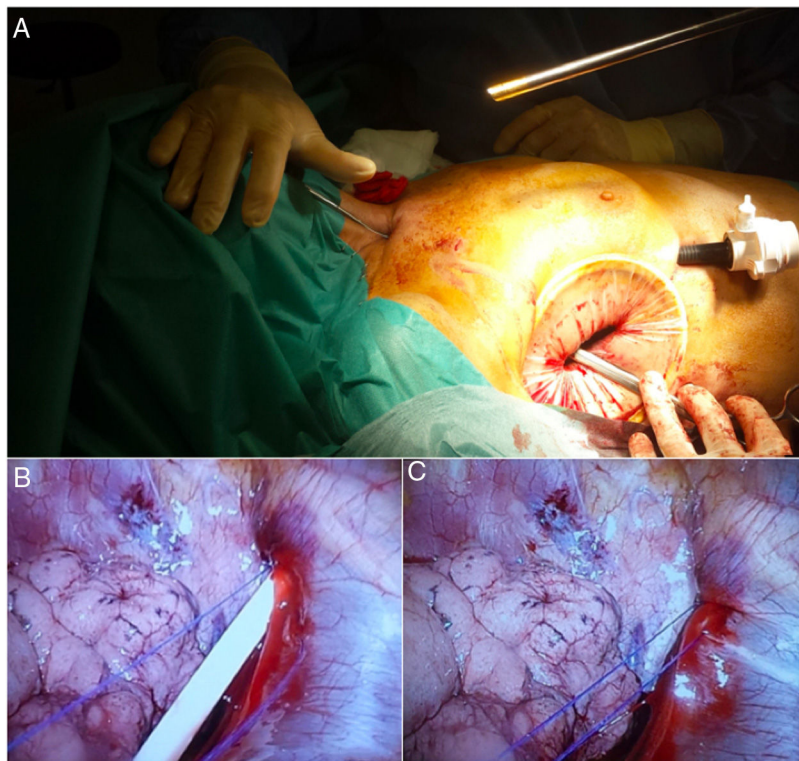


Fig. 2 – (A) Minithoracotomy in the right-side 5th intercostal space and trocar access for optics in the right-side 7th intercostal space, (B) Exit point of the central venous catheter through the lateral vena cava at its confluence with the innominate vein trunk, right subclavian vein and right jugular vein. Prolene®3/0 sutures proximal and distal to the perforated catheter prior to its removal, (C) Closure of the defect after removal of the catheter.

contraindicated in unstable patients, Cheli et al.¹⁰ associated the traditional thoracotomy approach with the use of 30° optics due to the inability to visualize and access the bleeding point. Kuzniec et al.⁷ presented the repair of a ruptured SVC using VATS in a stable patient as the first approach to treatment, with good results.

In our opinion, and although the experience is limited, VATS for the repair of a ruptured SVC secondary to the insertion of a central venous catheter in stable patients without cardiac tamponade is an alternative that provides direct visualization of the affected hemithorax in order to control the bleeding point, remove the venous catheter, directly repair the SVC and evacuate the hemothorax with good results.

Acknowledgements

The authors would like to thank the Vascular Surgery Department for their time, dedication.

REFERENCES

1. Sznajder JJ, Zvebil FR, Bitterman H, Weiner P, Bursztein S. Central vein catheterization. Failure and complication rates by three percutaneous approaches. *Arch Intern Med*. 1986;146:259-61.
2. Wang C-Y, Liu K, Chia Y-Y, Chen C-H. Bedside ultrasonic detection of massive hemothorax due to superior vena cava perforation after hemodialysis catheter insertion. *Acta Anaesthesiol Taiwanica*. 2009;47:95-8.
3. Albrecht K, Nave H, Breitmeier D, Panning B, Tröger HD. Applied anatomy of the superior vena cava-the carina as a landmark to guide central venous catheter placement. *Br J Anaesth*. 2004;92:75-7.
4. Stevens DC, Butty S, Johnson MS. Superior vena cava rupture and cardiac tamponade complicating the endovascular treatment of malignant superior vena cava syndrome: a case report and literature review. *Semin Intervent Radiol*. 2015;32:439-44.
5. Burket M. Challenging cases: superior vena cava rupture. *Endovasc Today*. 2003;2:11-3.
6. Tsang TS, Freeman WK, Sinak LJ, Seward JB. Echocardiographically guided pericardiocentesis: evolution and state-of-the-art technique. *Mayo Clin Proc*. 1998;73:647-52.
7. Kuzniec S, Natal SRB, Werebe E, de C, Wolosker N. Videothoroscopic-guided management of a central vein perforation during hemodialysis catheter placement. *J Vasc Surg*. 2010;52:1354-6.
8. Azizzadeh A, Pham MT, Estrera AL, Coogan SM, Safi HJ. Endovascular repair of an iatrogenic superior vena caval injury: a case report. *J Vasc Surg*. 2007;46:569-71.
9. Kabutey N-K, Rastogi N, Kim D. Conservative management of iatrogenic superior vena cava (SVC) perforation after attempted dialysis catheter placement: case report and literature review. *Clin Imaging*. 2013;37:1138-41.
10. Cheli M, Alberti D, Adriana T, Zaranko E, Colusso M, Arnoldi R, et al. Successful bleeding control by a combined conventional surgical approach and video-assisted surgery: a case report. *Ann Thorac Cardiovasc Surg*. 2009;15:253-6.

Carmen Sánchez Matás^{a,*}, Francisco Manresa Manresa^b, Daniel Andrades Sardiña^a, José Luis López Villalobos^a, Maria Enriqueta Bataller de Juan^b

^aCirugía Torácica, UGC de Unidad Médico-Quirúrgica de Enfermedades Respiratorias, Hospital Universitario Virgen del Rocío, Sevilla, Spain

^bUGC de Angiología y Cirugía Vascular, Hospital Universitario Virgen del Rocío, Sevilla, Spain

*Corresponding author.

E-mail address: nem.csm@gmail.com (C. Sánchez Matás).

2173-5077/

© 2019 AEC. Published by Elsevier España, S.L.U. All rights reserved.

Posttraumatic Thoracobiliary Fistula[☆]

Fístula biliorráica postraumática



Thoracobiliary fistula is a rare entity that can be caused spontaneously by hepatobiliary infections or, even less frequently, secondary to surgical manipulation or trauma.

A 20-year-old patient was admitted to the emergency department with a gunshot wound. The entry wound was in

the left paravertebral area of L2, and the exit wound was through the fifth intercostal space on the midline of the right clavicle. Chest radiography showed grade 2 right hemothorax, for which a right pleural drainage catheter was inserted. Subsequently, a thoracoabdominal CT scan revealed findings

[☆] Please cite this article as: Semaan L, Muñoz W, Villafañe D, García Franco CE. Fístula biliorráica postraumática. *Cir Esp*. 2020;98:366-367.