



Image of the Month

Gastric Burst Due to Occlusion Ccaused by an Intra-gastric Balloon[☆]

Estallido gástrico secundario a oclusión producida por un balón intragástrico

David Fernández-SanMillán,^{*} Fidel García Anguiano-Duque, Ángel Sánchez Álvarez, Juan Ramón Hernández Hernández

Servicio de Cirugía General y Aparato Digestivo, Complejo Hospitalario Universitario Insular Materno-Infantil, Las Palmas de Gran Canaria, Las Palmas, Spain

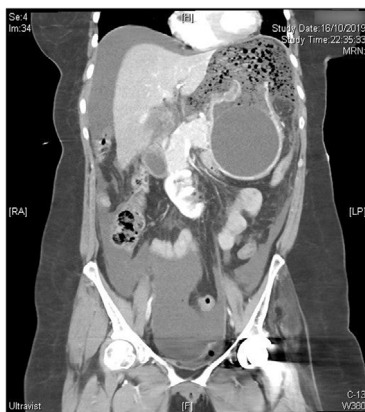

Figure 1

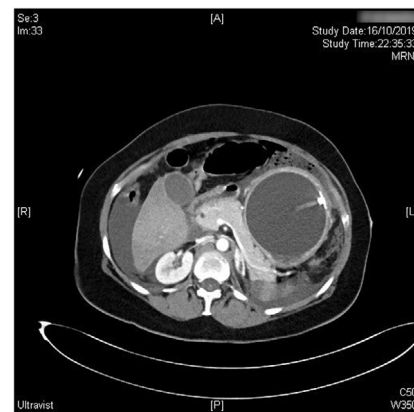


Figure 2

A 53-year-old woman came to the emergency room reporting diffuse abdominal pain and vomiting in the previous 16 h. She reported insertion of an Orbera[®] intra-gastric balloon (IGB) 4 months earlier, with no incidents. Computed axial tomography revealed a rupture in the gastric fundus, with pneumoperitoneum and abundant food content observed in the abdominal cavity (Fig. 1).

The surgical approach involved an atypical laparotomy resection of the fundus with a linear stapler (Echelon-Flex[™], loaded with 60 mm gold staples) reinforced with silk suture, abdominal lavage and Blake drains. The patient was discharged one week later (Fig. 2).

The use of IGB as an intermediate or definitive treatment in a weight loss protocol is considered a safe procedure. The most common complications are vomiting, abdominal pain and intestinal occlusion due to balloon rupture. Gastric rupture is a rare entity that should be considered.

[☆] Please cite this article as: Fernández-SanMillán D, García Anguiano-Duque F, Sánchez Álvarez Á, Hernández Hernández JR. Estallido gástrico secundario a oclusión producida por un balón intragástrico. Cir Esp. 2020;98:484.

^{*} Corresponding author.

E-mail address: san_millan@yahoo.es (D. Fernández-SanMillán).