



## Image of the month

## The value of indocyanine green (ICG) fluorescence for the identification of peritoneal carcinomatosis<sup>☆</sup>



### Valor de la fluorescencia con verde de indocianina (ICG) en la identificación de la carcinomatosis peritoneal

Teresa Rubio Sánchez,<sup>\*</sup> Ana Fluixá Pelegri, Salvador Morales-Conde

Unidad de Innovación en Cirugía Mínimamente Invasiva, Servicio de Cirugía General y Digestiva, Hospital Universitario Virgen del Rocío, Universidad de Sevilla, Sevilla, Spain

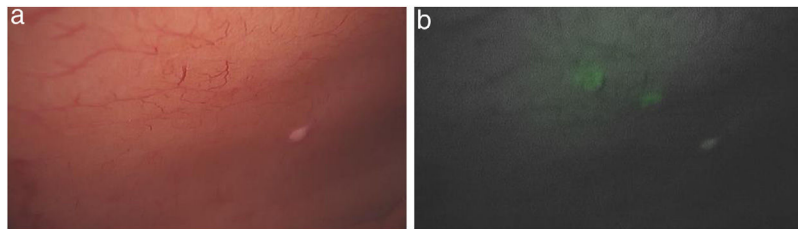


Fig. 1

The patient is a 34-year-old man with altered bowel movement and abdominal pain. Colonoscopy revealed a nodular lesion measuring 3 cm that deformed the ileocecal valve. CT scan demonstrated a cecal mass with extramural and mesenteric extension, as well as adjacent mesenteric lymphadenopathies.

Laparoscopy was initiated with the intention of performing a right hemicolectomy. Once the colon was mobilized medially and the vessels were ligated, peritoneal implants were identified on the lateral wall and biopsies were taken. After the administration of indocyanine green (ICG), we observed that some implants were only visible with ICG (Fig. 1a and b), which gave us an overall idea of the extent of the carcinomatosis. We decided to complete the right hemicolectomy and refer the patient to oncology for possible peritonectomy with hyperthermic chemotherapy. The pathological diagnosis was neuroendocrine tumor with metastasis in the wall implants.

Indocyanine green fluorescence-guided surgery is expanding its field of applications beyond the assessment of perfusion or to identify the bile duct, as it also provides visualization of macroscopically invisible structures, such as carcinomatosis implants. In this case, not only was it useful to verify the correct vascularization of the anastomosis, but it also helped detect peritoneal implants that had not been visible without ICG, confirming extension.

<sup>☆</sup> Please cite this article as: Rubio Sánchez T, Fluixá Pelegri A, Morales-Conde S. Valor de la fluorescencia con verde de indocianina (ICG) en la identificación de la carcinomatosis peritoneal. Cir Esp. 2020;98:558.

<sup>\*</sup> Corresponding author.

E-mail address: [terubios@gmail.com](mailto:terubios@gmail.com) (T. Rubio Sánchez).