



Image of the month

Hematoma of a Nissen fundoplication[☆]

Hematoma de la funduplicatura de Nissen

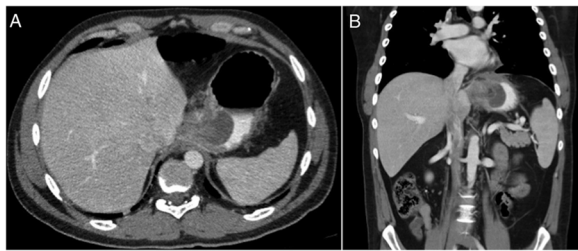
Ignacio Fuente,^{a,*} Sebastián Duran,^b Axel Beskow,^a Fernando Wright^a^a Servicio de Cirugía General, Hospital Italiano de Buenos Aires, Buenos Aires, Argentina^b Servicio de Gastroenterología, Hospital Italiano de Buenos Aires, Buenos Aires, Argentina

Fig. 1

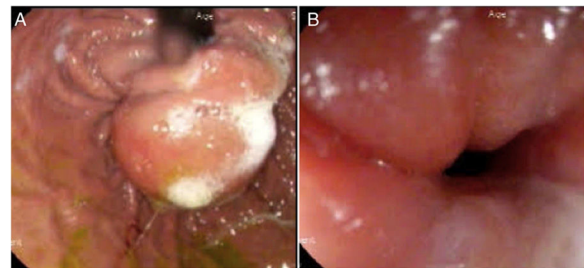


Fig. 2

A 32-year-old patient was evaluated for gastroesophageal reflux disease at our hospital, and laparoscopic Nissen fundoplication was performed. He was discharged 24 h later, with no complications. Seven days after surgery, he reported having progressive dysphagia and chest pain. Computed tomography scans of the thorax, abdomen and pelvis revealed a homogeneous collection measuring 40 × 32 mm in the thickness of the gastric wall (Fig. 1). Upper gastrointestinal endoscopy showed a subepithelial collection in the area of the fundoplication (Fig. 2).

After treatment with corticosteroids, the patient evolved favorably and was discharged 24 h later, showing good tolerance to a liquid diet.

Hematoma is a rare complication of Nissen fundoplication that should be included in the differential diagnosis of a recently operated patient with dysphagia.

[☆] Please cite this article as: Fuente I, Duran S, Beskow A, Wright F. Hematoma de la funduplicatura de Nissen. Cir Esp. 2021;99:63.

* Corresponding author.

E-mail address: ignacio.fuente@hospitalitaliano.org.ar (I. Fuente).