



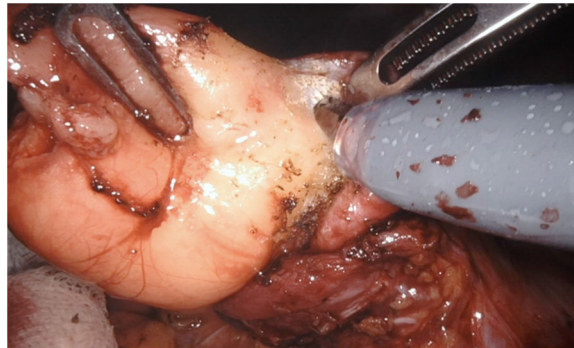
## Video of the month

# Resection of submucosal lipoma in the prepyloric region by roboti surgery<sup>☆</sup>

## Resección de lipoma submucoso en región prepilórica mediante cirugía robótica

Ana Pinillos Somalo,<sup>\*</sup> Alfredo Escartín Arias, Marta González Duaigues, Jorge Juan Olsina Kissler

Hospital Universitario Arnau de Vilanova, Lleida, Spain



Gastrointestinal lipomas are rare lesions whose prevalence is 4% of benign tumors of the gastrointestinal tract. Most are asymptomatic, although one of the most frequent manifestations is bleeding.

Surgical treatment is indicated based on size and the presence of symptoms. There are not many publications in the literature about the robotic approach in this type of tumors.

We present the case of a patient who was diagnosed with a submucosal lipoma in the pre-pyloric antral region after an episode of upper gastrointestinal bleeding, treated with a robotic surgical approach.

### Appendix A. Supplementary data

Supplementary material related to this article can be found, in the online version, at doi: <https://doi.org/10.1016/j.cireng.2021.01.013>.

<sup>☆</sup> Please cite this article as: Pinillos Somalo A, Escartín Arias A, González Duaigues M, Olsina Kissler JJ. Resección de lipoma submucoso en región prepilórica mediante cirugía robótica. Cir Esp. 2021;99:152.

<sup>\*</sup> Corresponding author.

E-mail address: [anapinillosomalo@gmail.com](mailto:anapinillosomalo@gmail.com) (A. Pinillos Somalo).