



Image of the month

Proximal jejuno-jejunal intussusception due a giant jejunal polyp[☆]



Invaginación yeyuno-yeyunal proximal por pólipo gigante yeyunal

Miguel Barrionuevo Gálvez,^{a,*} Antonio Enrique Calvo Durán,^a Manuel Balbuena García,^a Ángela Hens Pérez^b

^a Servicio de Cirugía General y del Aparato Digestivo, Hospital Universitario de Puerto Real, Puerto Real, Cádiz, Spain

^b Departamento de Anatomía Patológica, Facultad de Medicina, Universidad de Cádiz, Cádiz, Spain

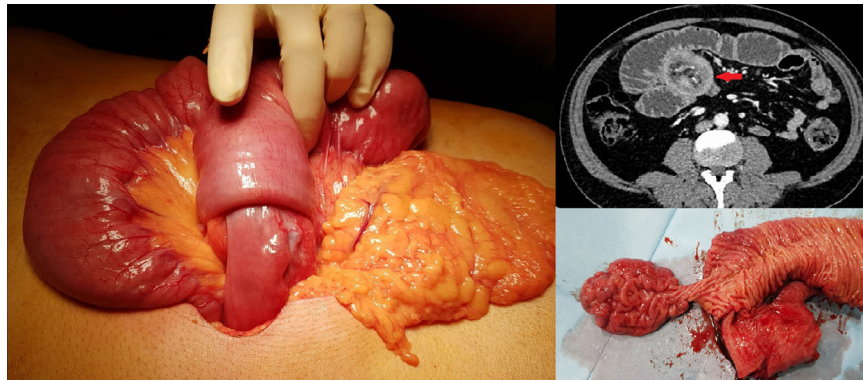


Figure 1

A 54-years-old male without relevant health issues is admitted in the ER for acute abdominal pain and vomits in the last 5 days. The physical examination shows epigastric pain and abdominal distension. An urgent CT scan describes a case of intestinal obstruction secondary to a jejunum-jejunal intussusception of a proximal segment 30 cm long with retrograde dilatation. An exploratory laparotomy is performed identifying a great intussuscepted segment of proximal jejunum, resecting it and creating a latero-lateral anastomosis 20 cm from Treitz's angle. At the examination of the resected bowel a giant polyp was identified as the cause of the intussusception (Fig. 1).

Acknowledgements

To the emergency team of the HUPR surgical block.

[☆] Please cite this article as: Barrionuevo Gálvez M, Calvo Durán AE, Balbuena García M, Hens Pérez Á. Invaginación yeyuno-yeyunal proximal por pólipo gigante yeyunal. Cir Esp. 2021;99:309.

* Corresponding author.

E-mail address: miguelbg94@gmail.com (M. Barrionuevo Gálvez).