



## Image of the month

Ureteroinguinal hernia: Better safe than sorry<sup>☆</sup>

## Hernia ureteroinguinal: más vale prevenir que curar

Clara Gené Škrabec,<sup>\*</sup> Christian Herrero Vicente, Albert Caballero Boza, Pau Moreno Santabàrbara

Servicio de Cirugía General y Digestiva, Hospital Germans Trias i Pujol, Badalona, Barcelona, Spain

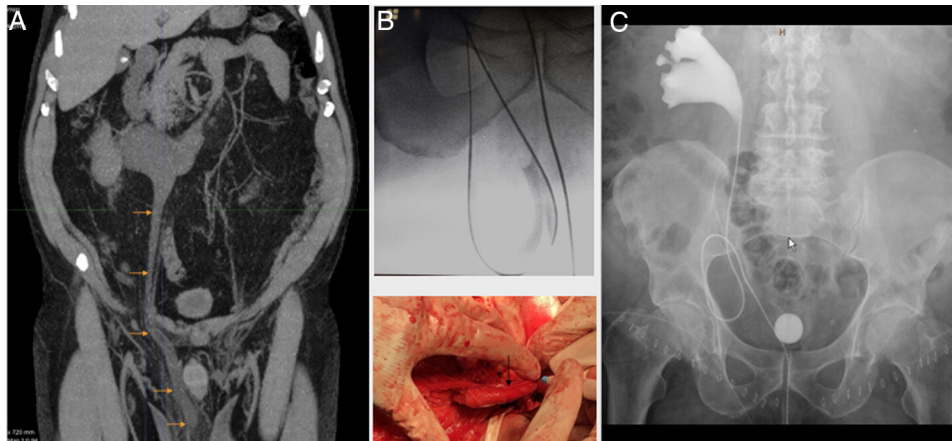


Fig. 1

A 66-year-old patient presented with voluminous bilateral inguinal hernias of elastic consistency; Abdominal CT was performed to rule out testicular masses. The CT showed bilateral inguinal hernias with fat content and right ureterohydronephrosis due to an atypical and elongated right ureter that was herniated into the scrotal bag (Fig. 1-a). The placement of a ureteral catheter allowed the safe identification of the ureter throughout Lichtenstein-type hernioplasty (Fig. 1b). Subsequent urography showed the ureter still elongated but positioned in the abdominal cavity (Fig. 1c). In complex or atypical inguinal hernias, preoperative CT can avoid surgical iatrogenesis.

### Acknowledgments

We appreciate doctors Eva Barluenga Torres, Anna Colomer, Fernando Agreda and Mauro Bernardello for their participation and collaboration in this case.

<sup>☆</sup> Please cite this article as: Gené Škrabec C, Herrero Vicente C, Caballero Boza A, Moreno Santabàrbara P. Hernia ureteroinguinal: más vale prevenir que curar. Cir Esp. 2020. <https://doi.org/10.1016/j.ciresp.2020.11.013>

<sup>\*</sup> Corresponding author.

Correo electrónico: [clgenesk@gmail.com](mailto:clgenesk@gmail.com) (C. Gené Škrabec).