



Video of the month

Reconstructive phase for laparoscopic duodenopancreatectomy. A technical challenge[☆]

Fase reconstructiva en la duodenopancreatectomía cefálica laparoscópica. Un reto técnico

Jaume Tur-Martínez,^{a,*} María Isabel García-Domingo,^a Manel Cremades Pérez,^b Esteban Cugat-Andorra^{a,b}

^a Servicio de Cirugía General y Aparato Digestivo, Unidad Cirugía Hepatobiliopancreática, Hospital Universitari Mútua Terrassa, Terrassa, Barcelona, Spain

^b Servicio de Cirugía General y Aparato Digestivo, Unidad Cirugía Hepatobiliopancreática, Hospital Germans Trias i Pujol, Badalona, Barcelona, Spain

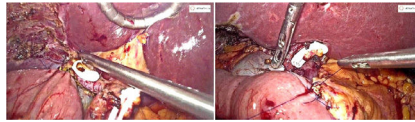


Fig. 1

After the publication of the Miami International Evidence-Based Guidelines for Minimally Invasive Pancreatic Resection Surgery,¹ clearly there is still a long way to go to establish laparoscopy as the approach of choice for pancreaticoduodenectomy, as it is limited to hospitals with greater experience in pancreatic surgery and advanced laparoscopy procedures.

The following video explains the main steps of the reconstructive phase of laparoscopic pancreaticoduodenectomy for the treatment of a patient with ampullary cancer (Fig. 1).

Acknowledgements

The authors would like to thank Melissa Arias-Avilés for her contribution in translating the video.

Appendix A. Supplementary data

Supplementary material related to this article can be found, in the online version, at doi: <https://doi.org/10.1016/j.cireng.2021.04.001>.

REFERENCE

1. Asbun HJ, Moekotte AL, Vissers FL, Kunzler F, Cipriani F, Alseidi A, et al. The Miami international evidence-based guidelines on minimally invasive pancreas resection. *Ann Surg.* 2020;271:1–14.

[☆] Please cite this article as: Tur-Martínez J, García-Domingo MI, Cremades Pérez M, Cugat-Andorra E. Fase reconstructiva en la duodenopancreatectomía cefálica laparoscópica. Un reto técnico. *Cir Esp.* 2021;99:380.

* Corresponding author.

E-mail address: jaume.tur.martinez@gmail.com (J. Tur-Martínez).