



# CIRUGÍA ESPAÑOLA

[www.elsevier.es/cirugia](http://www.elsevier.es/cirugia)



## Video of the month

# Laparoscopic pancreatoduodenectomy. Resective phase step by step in celiac-mesenteric trunk variant<sup>☆</sup>

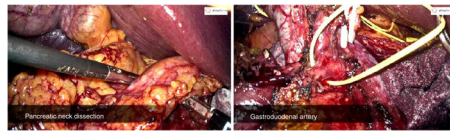


## Duodenopancreatectomía cefálica laparoscópica. Fase resectiva paso a paso en variación de tronco celíaco-mesentérico

Èric Herrero-Fonollosa,<sup>a</sup> Judith Camps-Lasa,<sup>a</sup> Alba Zárate-Pinedo,<sup>b</sup> Jaume Tur-Martínez,<sup>a,\*</sup> Esteban Cugat-Andorra<sup>a,b</sup>

<sup>a</sup> Servicio de Cirugía General y Aparato Digestivo, Unidad Cirugía Hepatobiliopancreática, Hospital Universitari Mútua Terrassa, Terrassa, Barcelona, Spain

<sup>b</sup> Servicio de Cirugía General y Aparato Digestivo, Unidad Cirugía Hepatobiliopancreática, Hospital Germans Trias i Pujol, Badalona, Barcelona, Spain



Pancreatoduodenectomy is one of the most complex surgical techniques and presents the highest morbidity and mortality in pancreatic surgery. The laparoscopic approach is still not performed in most hospitals because extensive experience in pancreatic surgery and advanced laparoscopic surgery is necessary. Likewise, it usually requires longer surgical time, and there is still little evidence regarding its benefits in terms of morbidity and mortality rates.

The following video presents the main steps of the resection phase of laparoscopic pancreatoduodenectomy in the treatment of a patient with ampullary cancer.

### Conflict of interests

The authors have no conflicts of interests to declare, have received no public or private funding for this study.

### Acknowledgments

The authors would like to thank Melissa Arias-Avilés for her contribution in translating the video.

### Appendix A. Supplementary data

Supplementary material related to this article can be found, in the online version, at doi: <https://doi.org/10.1016/j.cireng.2021.04.002>.

<sup>☆</sup> Please cite this article as: Herrero-Fonollosa È, Camps-Lasa J, Zárate-Pinedo A, Tur-Martínez J, Cugat-Andorra E. Duodenopancreatectomía cefálica laparoscópica. Fase resectiva paso a paso en variación de tronco celíaco-mesentérico. Cir Esp. 2021;99:379.

\* Corresponding author.

E-mail address: [jaume.tur.martinez@gmail.com](mailto:jaume.tur.martinez@gmail.com) (J. Tur-Martínez).