



Image of the month

Incidental finding of a gastrointestinal stromal tumor in a complicated inguinal hernia ☆



Hallazgo incidental de un tumor del estroma gastrointestinal en una hernia inguinal complicada

Cristian Agustín Angeramo,* Francisco Laxague, Julieta Andrea Giacone Aguiar, Pablo Capitanich

Servicio de Cirugía General, Hospital Alemán de Buenos Aires, Buenos Aires, Argentina

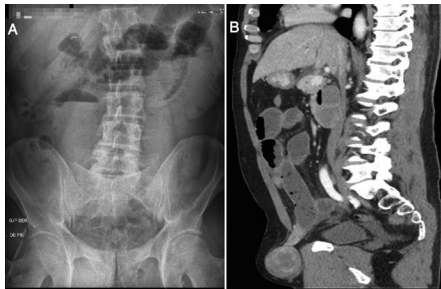


Fig. 1

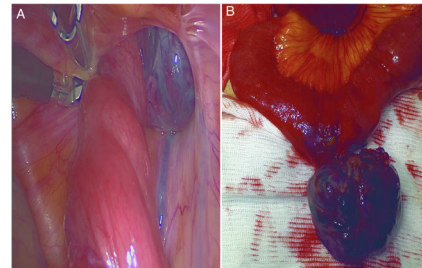


Fig. 2

Case report

The patient is a 59-year-old man who consulted for symptoms of intestinal obstruction. Physical examination revealed an irreducible right inguinal hernia that was painful on palpation. Standing abdominal X-ray revealed dilation of the intestinal loops (Fig. 1A). Computed tomography scan showed a right inguinoscrotal hernia (Fig. 1B). Exploratory laparoscopy revealed a mass associated with the herniated intestinal loop (Fig. 2A). We performed the inguinal repair laparoscopically, and enterectomy of the intestinal segment associated with the tumor was performed through a midline mini-laparotomy (Fig. 2B). The postoperative recovery transpired without complications. The patient was discharged from hospital on the 4th postoperative day. The pathology report identified the mass as a gastrointestinal stromal tumor (GIST).

☆ Please cite this article as: Angeramo CA, Laxague F, Giacone Aguiar JA, Capitanich P. Hallazgo incidental de un tumor del estroma gastrointestinal en una hernia inguinal complicada. Cir Esp. 2020. <https://doi.org/10.1016/j.ciresp.2020.09.015>

* Corresponding author.

Correo electrónico: cangeramo@hospitalaleman.com (C.A. Angeramo).