



Video of the month

Stump appendicitis: An unusual and preventable entity after laparoscopic appendectomy[☆]

Apendicitis del muñón: una entidad inusual y prevenible tras apendicectomía laparoscópica

Yoelimar Guzmán,^{a,*} Carolina González,^a César Ginestà,^b Xavier Morales^c

^a Servicio de Cirugía General y Digestiva, Hospital Clínic, Universitat de Barcelona, Barcelona, Spain

^b Departamento de Cirugía Hepatobiliopancreática, Servicio de Cirugía General y Digestiva, Hospital Clínic, Universitat de Barcelona, Barcelona, Spain

^c Departamento de Cirugía Gastrointestinal, Servicio de Cirugía General y Digestiva, Hospital Clínic, Universitat de Barcelona, Barcelona, Spain

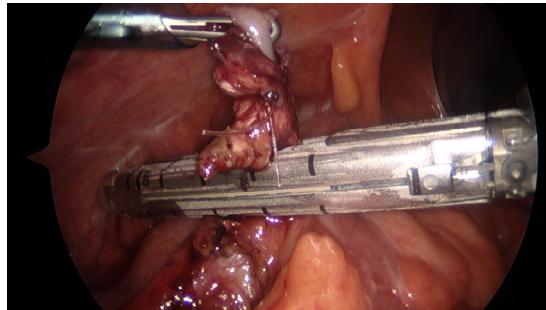


Fig. 1

The patient is a 38-year-old male who had undergone laparoscopic appendectomy one month earlier and was now experiencing pain in the right iliac fossa and nausea for the past 24 h. Upon examination in the Emergency Department, he presented guarding in the lower right quadrant. Laboratory tests revealed leukocytosis and elevated acute phase reactants. A computed tomography scan showed a 25-mm

appendiceal remnant, which was increased in caliber, and trabeculation of the adjacent fat.

Diagnostic laparoscopy (Appendix B, Video 1) confirmed the presence of an inflamed appendiceal stump with absorbable suture (ENDOLOOP®) at its distal end. As the procedure was a reoperation, the remnant was divided with an endostapler as it is a fast, efficient and safe method (Fig. 1).

[☆] Please cite this article as: Guzmán Y, González C, Ginestà C, Morales X. Apendicitis del muñón: una entidad inusual y prevenible tras apendicectomía laparoscópica. Cir Esp. 2021. <https://doi.org/10.1016/j.ciresp.2021.02.013>

* Corresponding author.

E-mail address: yoelimargj@gmail.com (Y. Guzmán).