



Video of the month

Laparoscopic resection of duodenal GIST[☆]



Resección laparoscópica de GIST duodenal

Giulia Vitiello,^{*} Jing Huang Ye Zhou, Sonia Fernandez-Ananin, Carmen Balague-Ponz

Servicio de Cirugía General y Digestiva, Hospital de la Santa Creu i Sant Pau, Barcelona, Spain

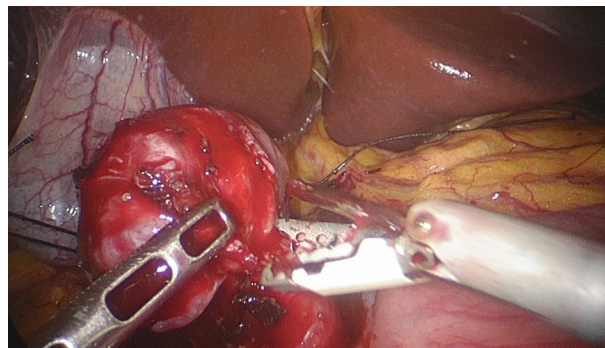


Fig. 1 – Excision of the tumor.

Laparoscopic surgery has been shown to be safe and effective in the treatment of gastrointestinal stromal tumors (GIST). It is true that the majority are gastric and their location in other anatomical areas requires the surgeon to be more technically skilled.

We present the case of a GIST located on the anterior side of the first part of the duodenum.

Intraoperatively, local laparoscopic resection with macroscopically correct margins was considered feasible.

The pathology analysis identified the mass as a low-risk GIST (3.5 cm in diameter, 4 mitoses \times 50CGA) and confirmed the integrity of the capsule as well as the negative margins (Fig. 1).

Appendix A. Supplementary data

Supplementary material related to this article can be found, in the online version, at doi:<https://doi.org/10.1016/j.cireng.2021.09.011>.

[☆] Please cite this article as: Vitiello G, Ye Zhou JH, Fernandez-Ananin S, Balague-Ponz C. Resección laparoscópica de GIST duodenal. Cir Esp. 2021. <https://doi.org/10.1016/j.ciresp.2021.02.014>

^{*} Corresponding author.

E-mail address: giuliavit4@gmail.com (G. Vitiello).