



Image of the month

Gastrocystic fistula secondary to prepyloric peptic ulcer[☆]

Fístula gastroquística secundaria a úlcera péptica prepilórica

Ester Alonso Batanero,^{*} Raquel Rodríguez Uría, María Moreno Gijón,
Lourdes María Sanz Álvarez

Servicio de Cirugía General y del Aparato Digestivo, Hospital Universitario Central de Asturias, Oviedo, Asturias, Spain

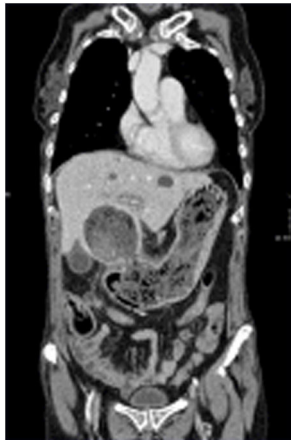

Fig. 1

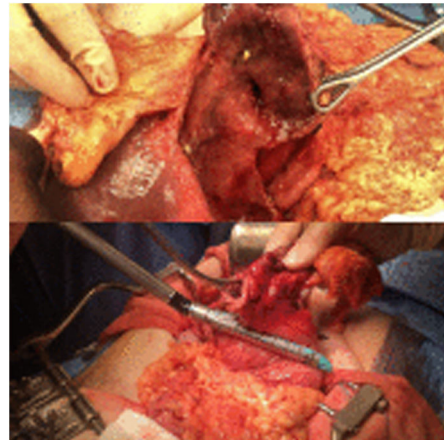


Fig. 2

A 61-year-old woman with a double-lung transplant and anemia (hemoglobin 5.9 g/dL) was diagnosed with a fistula between the lesser curvature of the stomach and a previously observed simple hepatic cyst by computed tomography (Fig. 1). Intraoperatively, after unroofing the cyst, the fistula was confirmed. We therefore conducted atypical gastrectomy below the angular incisure (Fig. 2), and the pathology study confirmed an extensive gastric ulcer.

Gastrohepatic fistulae are rare. Our case is the first to show a communication with a simple cyst. The complexity of the surgery is determined by the location of the ulcer.

[☆] Please cite this article as: Alonso Batanero E, Rodríguez Uría R, Moreno Gijón M, Sanz Álvarez LM. Fístula gastroquística secundaria a úlcera péptica prepilórica. Cir Esp. 2022. <https://doi.org/10.1016/j.ciresp.2021.03.008>

^{*} Corresponding author.

E-mail address: estherab91@gmail.com (E. Alonso Batanero).