



Image of the month

Bryant sign, an atypical presentation of an acute severe pancreatitis[☆]

Signo de Bryant como presentación inicial de un caso de pancreatitis aguda grave

Joan Ferreres Serafini,^{*} Jordi Elvira López, Robert Memba Ikuga, Rosa Jorba Martín

Servicio de Cirugía General y del Aparato Digestivo, Hospital Universitario de Tarragona Joan XXIII, Tarragona, Spain

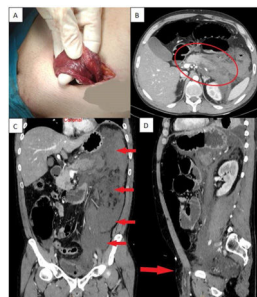


Fig. 1

A 41-year-old man with a history of alcoholism came to the emergency department for abdominal pain and a non-reducible left inguinoscrotal tumour, with purplish discolouration of the scrotum, for which urgent surgery was decided. Intraoperative findings of dark serohematic fluid at the level of the inguinal cord dissecting down to the scrotum, with no evidence of inguinal hernia (Fig. 1). In view of a clinical and analytical worsening at 24 h, a CT scan was performed (Fig. 1) which showed signs of acute pancreatitis with significant peripancreatic and retroperitoneal oedema. Cutaneous ecchymosis secondary to pancreatitis occurs in 3% of patients, usually in the most severe cases.

Diagnosis: Severe acute pancreatitis of alcoholic aetiology with Bryant's sign and inguinoscrotal tumour as initial presentation.

Acknowledgements

Our thanks to doctors Mihai-Calin Pavel, Laia Estalella, Erik Llàcer, Elisabet Julià and Alba Martínez who jointly participated with the authors in the management of this patient on the surgical ward.

Also to Dr Víctor Iranzo, on-call urologist who assessed the patient's cremaster, inguinal canal and scrotum intraoperatively once inguinal hernia was ruled out.

Joan Ferreres, Jordi Elvira, Robert Memba and Rosa Jorba participated in the redaction of this article.

[☆] Please cite this article as: Ferreres Serafini J, Elvira López J, Memba Ikuga R, Jorba Martín R. Signo de Bryant como presentación inicial de un caso de pancreatitis aguda grave. Cir Esp. 2021. <https://doi.org/10.1016/j.ciresp.2021.09.005>

^{*} Corresponding author.

E-mail address: joanfs8@gmail.com (J. Ferreres Serafini).