



Image of the month

Cecal volvulus due to degenerated uterine leiomyoma ☆

Volvulación de ciego secundaria a fibroma uterino degenerado

Laura Peñate Pérez,* José Luis Colombo García, Rafael Torrejón Cardoso

Servicio de Ginecología y Obstetricia, Hospital Puerta del Mar, Cádiz, Spain

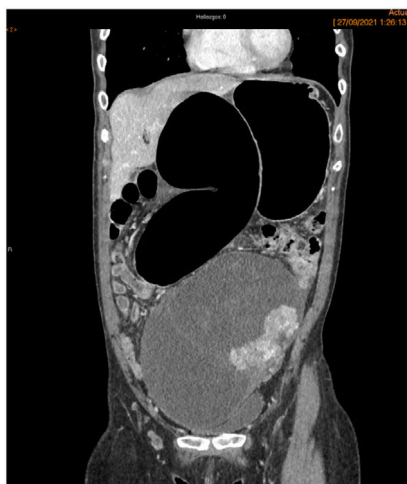

Fig. 1

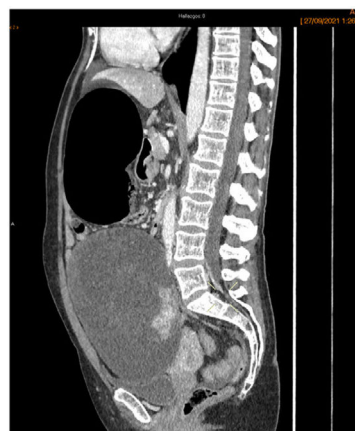


Fig. 2

A 57-year-old woman with no past medical history consulted for abdominal pain of hours' duration, afebrile and with preserved intestinal transit. Examination revealed a distended abdomen and a painful mass in the right hemiabdomen. Laboratory tests showed mild leukocytosis and an anodyne rest.

The abdominal X-ray showed intestinal dilatation and the abdominal CT scan showed dilatation of the right colon (11 cm) compatible with cecal volvulus and a voluminous mass (16 cm) adjacent to the pelvis with probable dependence on the left ovary (Figs. 1 and 2). Surgery was performed with right hemicolectomy and hysterectomy with double adnexectomy.

Definitive anatomopathological diagnosis: uterine fibroma with hyaline degeneration.

☆ Please cite this article as: Peñate Pérez L, Colombo García JL, Torrejón Cardoso R. Volvulación de ciego secundaria a fibroma uterino degenerado. Cir Esp. 2022;100:644–644.

* Corresponding author.

E-mail address: laurapenate17@gmail.com (L. Peñate Pérez).