



Image of the month

Giant leiomyoma with bizarre nuclei

Leiomioma gigante con núcleos bizarros

Leire Guerrico Tome,^{a,*} Ainhoa Andres Imaz,^a Raúl Jiménez Agüero,^a
Maddi Garmendia Irizar^b

^aServicio de Cirugía General, Hospital Universitario Donostia, San Sebastián, Guipúzcoa, Spain

^bServicio de Anatomía Patológica, Hospital Universitario Donostia, San Sebastián, Guipúzcoa, Spain

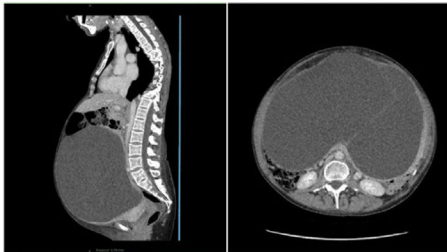

Fig. 1

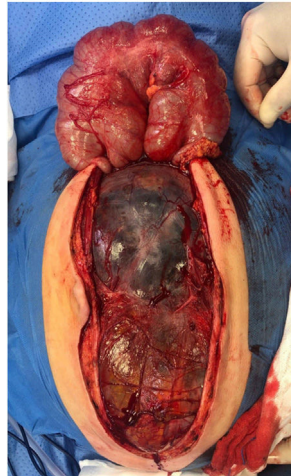


Fig. 2

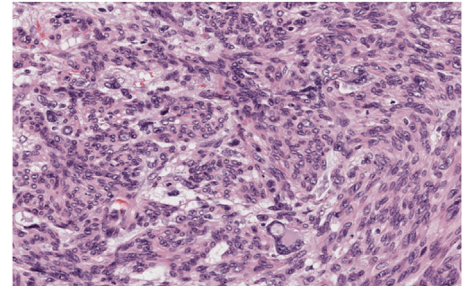


Fig. 3

Forty-nine-year-old woman with progressive increase in abdominal perimeter, dyspnoea and oedema in the lower limbs. Computed tomography (Fig. 1) revealed a large multiseptated cystic mass displacing intra-abdominal organs. Intraoperatively, a cystic tumour adherent to the uterus and mesosigmoid with no clear organ dependence was confirmed (Fig. 2); en bloc resection with hysterectomy and sigmoidectomy was performed and it turned out to be a leiomyoma with bizarre nuclei of probable uterine origin (Fig. 3).

Leiomyoma with bizarre nuclei is a rare benign variant of smooth muscle neoplasia, and is considered a distinct entity by the WHO 2014 classification. It presents features of histological atypia, requiring differential diagnosis with leiomyosarcoma.

Diagnosis

Leiomyoma with bizarre nuclei.

* Corresponding author.

E-mail address: leireguerrico@gmail.com (L. Guerrico Tome).