



Image of the month

Incarcerated hernia or appendicitis? Garengoet's hernia



¿Hernia encarcerada o apendicitis? Hernia de Garengoet

Silvia Martín-Arroyo,* Raquel Escalera-Pérez, Carlos Medina-Achirica, Francisco José García-Molina

Servicio de Cirugía General, Hospital de Especialidades de Jerez de la Frontera, Cádiz, Spain

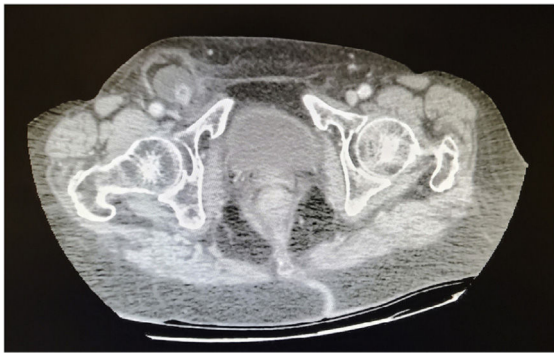

Fig. 1

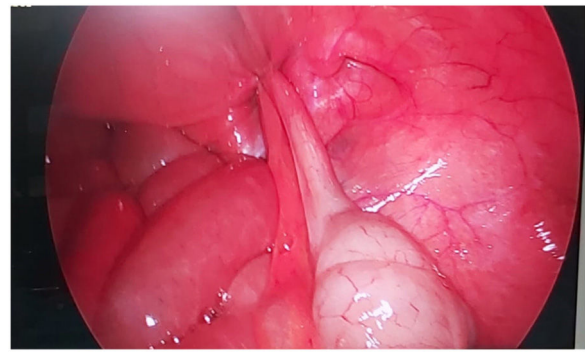


Fig. 2

Eight-three-year-old patient with no previous history, who attended the emergency department with fever and right inguinal pain. On examination, the abdomen was soft and depressible with an irreducible right crural hernia.

Given the current pandemic situation, the study was completed with ultrasound; the radiologist decided to transfer the patient to CT and found evidence of a crural hernia containing an appendix with signs of appendicitis (Fig. 1).

A laparoscopic approach was decided (Fig. 2), performing appendectomy and TAPP.

With this case we wish to contribute to the literature by presenting a rare case of appendicitis in an incarcerated crural hernia (Garengoet's hernia).

* Corresponding author.

E-mail address: smartin2910@gmail.com (S. Martín-Arroyo).

<http://dx.doi.org/10.1016/j.cireng.2022.09.006>

2173-5077/© 2022 AEC. Published by Elsevier España, S.L.U. All rights reserved.