



Image of the month

Portal gas and gastric pneumatosis. A story with happy ending

Gas portal y neumatosis gástrica. Una historia con final feliz

Sergio Hernández-Villafranca,* Mario Martín Sánchez, Carmen Sánchez, Pedro Villarejo Campos

Servicio de Cirugía General y del Aparato Digestivo, HU Fundación Jiménez Díaz, Madrid, Spain

An 86-year-old woman with multiple comorbidities attended the emergency department for incoercible vomiting, revealing an incarcerated umbilical hernia. Abdominal computed tomography showed a distal stomach with gastric pneumatosis and portal gas (Fig. 1). Exploratory laparotomy was performed, finding a herniated antropyloric region, with no signs of distress (Fig. 2). Umbilical hernioplasty was performed and the patient was discharged without complications. Portal and gastric pneumatosis are usually ominous signs due to their frequent association with massive intestinal ischaemia and emphysematous gastritis; however, they are radiological signs that can be associated with different aetiologies such as mechanical intestinal obstruction, with a better prognosis.

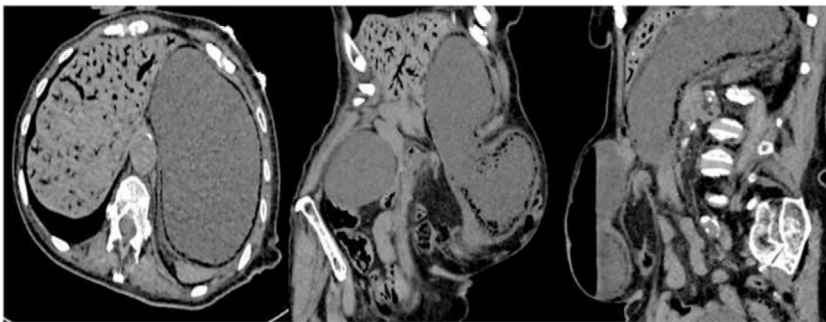


Fig. 1

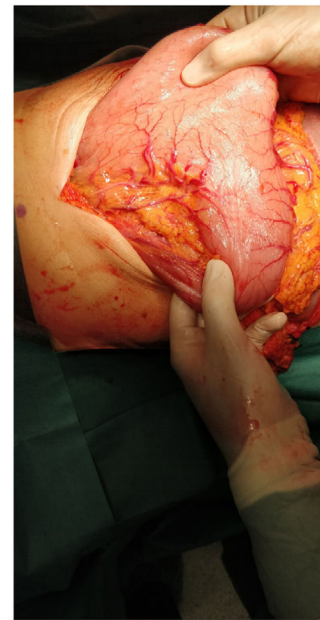

Fig. 2

* Corresponding author.

E-mail address: hernandezvillafranca@hotmail.com (S. Hernández-Villafranca).

<http://dx.doi.org/10.1016/j.cireng.2022.09.012>

2173-5077/© 2022 AEC. Published by Elsevier España, S.L.U. All rights reserved.