



Image of the month

Extraluminal foreign body after ingestion

Cuerpo extraño extraluminal tras ingesta



Núria Llorach-Perucho,* Juan Carlos García-Pacheco, Anna Serracant-Barrera, Salvador Navarro-Soto

Servicio de Cirugía General y Aparato Digestivo, Corporació Sanitària Parc Taulí, Universidad Autónoma de Barcelona, Sabadell, Barcelona, Spain

A 38-year-old patient consulted for pain in the left hypochondrium one week after the accidental ingestion of an orthodontic wire. The abdominal X-ray apparently showed a radiopaque image in the colon without pneumoperitoneum (Fig. 1a).

Due to persistent pain, a CT scan was performed, which revealed an extraluminal foreign body anterior to the greater gastric curvature, between the hepatic angle of the colon and the left hepatic lobe, without pneumoperitoneum or free fluid (Fig. 1b).

The foreign body was removed laparoscopically without incident (Fig. 1c).

In the case of accidental ingestion of foreign bodies, the CT scan pinpoints their location and complications.

Diagnosis: extraluminal foreign body.

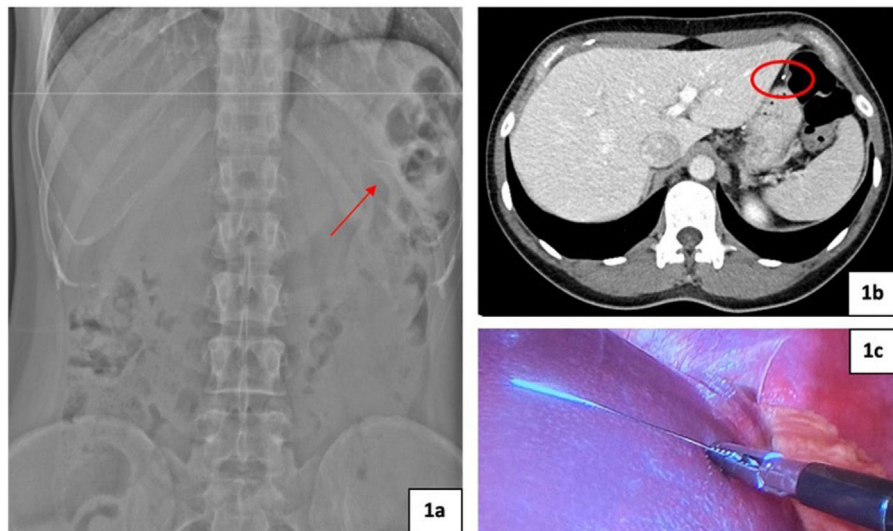


Fig. 1

* Corresponding author.

E-mail address: nuriallorachperucho@gmail.com (N. Llorach-Perucho).

<http://dx.doi.org/10.1016/j.cireng.2022.09.020>

2173-5077/© 2022 AEC. Published by Elsevier España, S.L.U. All rights reserved.