



Video of the month

Laparoscopic Heller's esophagomyotomy: treatment of achalasia in a patient with situs inversus

Esofagomiotomía de Heller laparoscópica: tratamiento de la acalasia en un paciente con situs inversus

Ester Ferrer-Inaebnit,* Alessandro Bianchi, José Antonio Martínez Córcoles,
Alberto Pagán Pomar

General and Digestive Surgery Service, Hospital Universitario Son Espases, Palma de Mallorca, Spain

A 56-year-old male, with history of situs inversus, presented dysphagia and vomiting, secondary to type II Achalasia.

The barium swallow showed a difficulty in its passage to the stomach, with incomplete relaxation of the lower esophageal sphincter (Image 1). The manometry reported the absence of primary peristalsis in the esophageal body. The gastroscopy showed a dilated and hypokinetic morphology in the esophagus, and closed cardias with resistance to passage.

Given the failure of endoscopic treatment, it was decided to perform laparoscopic Heller's esophagomyotomy with an anterior Dor hemifundoplication of 180°.

Post-operative course was uneventful, with immediate symptoms resolution and correct oral tolerance.

Appendix A. Supplementary data

Supplementary material related to this article can be found, in the online version, at doi:<https://doi.org/10.1016/j.ciresp.2022.11.006>.

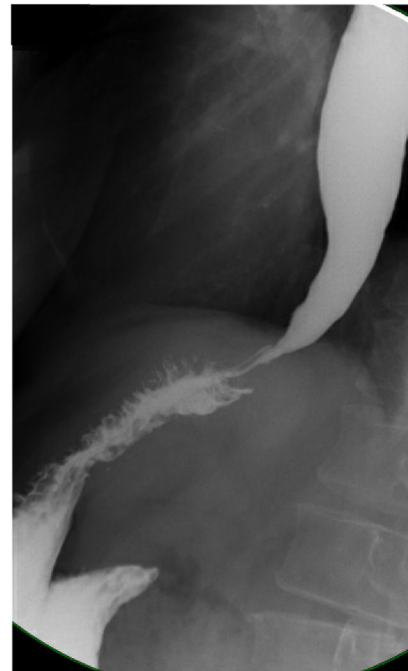


Image 1

* Corresponding author.

E-mail address: esterinaebnit@gmail.com (E. Ferrer-Inaebnit).

<http://dx.doi.org/10.1016/j.ciresp.2022.11.014>

2173-5077/© 2022 Published by Elsevier España, S.L.U. on behalf of AEC.