



Image of the month

Major bilateral inguinal hernia involving both kidneys

Hernia inguinal bilateral gigante que abarca ambos riñones

Alexandre Henrard,* Lucía González González, Virginie Poulain, Juan Santiago Azagra

Department of General and Minimally Invasive Surgery (Laparoscopy and Robotic), Centre Hospitalier de Luxembourg, Luxembourg City, Luxembourg

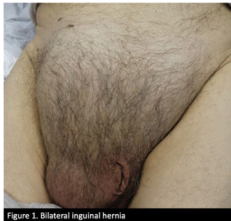

Fig. 1

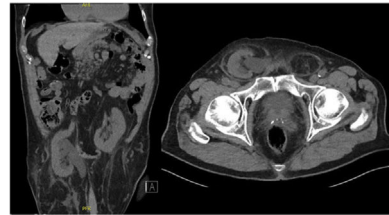


Fig. 2

A 82-years-old man presented to the emergency room for a right inguinal pain associated with renal failure. On clinical examination, we found a voluminous non reducible bilateral inguinal hernia (Fig. 1). A computerized tomography scan (Fig. 2) found a bilateral inguinal hernia containing both orthotopic kidneys causing chronic renal failure secondary to bilateral hydronephrosis.

Considering patient's age, his medical history, and the lack of visceral perfusion deficiency, a conservative attitude has been adopted with clinical and biological monitoring. Kidneys involvement in inguinal hernias is extremely rare and limited to a few case reports.

Authors' contribution

All authors have collaborated in the writing of the article.

Funding

No financial support has been received in the form of scholarships, or in any other way, to carry out the study.

This "image of the month" has not been presented in any congress or magazine before.

Conflict of interest

All authors declare that they have no conflict of interest.

* Corresponding author.

E-mail address: Alexandrehenrard003@gmail.com (A. Henrard).

<http://dx.doi.org/10.1016/j.cireng.2022.03.023>

2173-5077/© 2022 AEC. Published by Elsevier España, S.L.U. All rights reserved.