

## SCIENTIFIC LETTERS

### Rare adverse effect of discontinuation of levothyroxine treatment for $^{131}\text{I}$ ablation of thyroid remnant in a patient with differentiated thyroid cancer<sup>☆</sup>

#### Efecto adverso excepcional de la suspensión del tratamiento con levotiroxina para la ablación con I-131 del remanente tiroideo en una paciente con cáncer diferenciado de tiroides

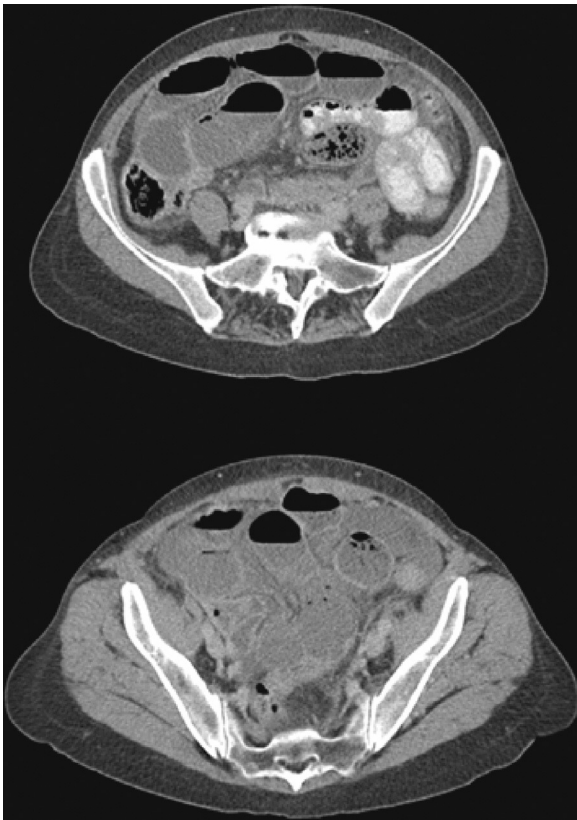
#### Introduction

Constipation and hyporexia are the most common gastrointestinal clinical manifestations in hypothyroid patients. They result from a generalized decrease in gastrointestinal tract motility, and on rare occasions may trigger a pseudo-obstructive picture that usually responds to the administration of thyroid hormone.<sup>1</sup> Thus, the occurrence of gastrointestinal complications requiring surgery is anecdotal.<sup>2</sup> Thyroid remnant ablation after surgery in patients with differentiated thyroid cancer (DTC) requires stimulation with TSH, which may be performed by administering recombinant human TSH  $\alpha$  or after discontinuation of levothyroxine treatment with the resultant elevation in endogenous TSH. This iatrogenic hypothyroid state is symptomatic in a significant number of cases, impairing patient quality of life,<sup>3</sup> but clinical symptoms are transient and usually well tolerated in most cases. However, constipation secondary to bowel hypomotility is one of the most commonly reported secondary manifestations.<sup>3</sup> The case of a female patient who experienced acute abdomen as an exceptional complication following preparation in a hypothyroid state for ablation with  $^{131}\text{I}$  after surgery for DTC is reported below.

<sup>☆</sup> Please cite this article as: Luque-Ramírez M, Gómez Ramírez J, Azcárate Villalón A, Martín Pérez E, Larrañaga Barrera E. Efecto adverso excepcional de la suspensión del tratamiento con levotiroxina para la ablación con I-131 del remanente tiroideo en una paciente con cáncer diferenciado de tiroides. *Endocrinol Nutr.* 2013;60:412–414.

A 59-year-old female patient attended the emergency room of our hospital reporting continuous pain in the right side of the abdomen with colic-like exacerbations lasting for 72 h, dysthermic sensation and chills, nausea, bile-stained vomiting, and no defecation during the episode. Her personal history included no surgery or abdominal or pelvic trauma, nor prior chronic or intermittent abdominal symptoms. Five months earlier she had undergone total thyroidectomy for a 15-mm unifocal papillary thyroid carcinoma, and seven days before attending the emergency room she had received ablation therapy with  $^{131}\text{I}$  in a hypothyroid state (TSH 58 mIU/L, undetectable FT4) after the discontinuation of suppressing levothyroxine treatment for four weeks. A whole body scan performed after ablation showed thyroid bed uptake only. On physical examination, the patient was afebrile and hemodynamically stable, but had a poor general status. An abdominal examination revealed decreased air-fluid sound and generalized bloating in a distended and diffusely tender abdomen with no masses or visceromegalies and with signs of peritoneal irritation. The only remarkable result of laboratory tests performed in the emergency room was leukocytosis (17,070 cells/mm<sup>3</sup>) with 94% neutrophils. An abdominal CT scan (Fig. 1) showed a dilatation of the small bowel loops from the jejunum to the ileum except for the distal 20–30 cm, where a change in size with no identifiable cause was seen, intraperitoneal free fluid, and a gastric cavity distended with oral contrast. Based on these findings, an exploratory laparotomy was performed, revealing dilated small bowel loops up to the distal ileum, which was rotated and obstructed by a congenital web that caused vascular compromise and signs of non-reversible intestinal ischemia. A resection of 15 cm of the compromised ileum was performed, followed by side-to-side anastomosis and abdominal cavity washing, and normal retrograde emptying of loops was seen with no other findings. At the histopathological examination, a small bowel segment with ischemic necrosis and signs of severe peritonitis was found. The early postoperative course was uneventful, and food tolerance and oral levothyroxine treatment started at 72 h. Since surgery, the patient has not had new abdominal symptoms or evidence of any persistence or recurrence of thyroid neoplasm.

To our knowledge, no case has been reported where these two rare conditions concur: paralytic ileus secondary to hypothyroidism after discontinuation of levothyroxine



**Figure 1** Abdominal CT scan after administration of oral and IV contrast showing a dilatation of the small bowel loops from the jejunum to the ileum except for the distal 20–30 cm, where a change in size with no identifiable cause is seen.

treatment for administration of  $^{131}\text{I}$  in a patient with DTC, which leads to incarcerated intestinal hernia on a previously unknown and asymptomatic congenital web. Increased oral-cecal transit time,<sup>4</sup> decreased esophageal persistalsis,<sup>5</sup> slower gastric emptying,<sup>6</sup> and bowel hypomotility mainly affecting the large bowel<sup>4</sup> occur in hypothyroid patients. These symptoms are usually mild and improve with the administration of levothyroxine.<sup>7</sup> However, severe, prolonged hypothyroidism may be associated with paralytic ileus or pseudo-obstructive conditions reversible with hormone treatment,<sup>8</sup> and may very occasionally lead to intestinal ischemia that may, in turn, occasionally be fatal.<sup>9</sup> The underlying cause of this hypomotility has yet to be elucidated. Colonic atony may be mediated by two mechanisms: submucosal myxedematous infiltration with separation of muscle fibers of the lymph nodes of Auerbach's plexus,<sup>8</sup> and a severe autonomic neuropathy of extrinsic nerve fibers of the colon and myenteric plexus.<sup>9</sup>

Intestinal obstruction by a congenital web originating from embryonic structures such as the vitelline duct, artery and veins, and the urachus, or from an abnormal coupling of peritoneal layers during embryogenesis<sup>10</sup> is uncommon in children and exceptional in adults.<sup>11</sup> This represents a significant diagnostic dilemma before surgery due to its low

frequency, but should be considered in differential diagnosis of any patient with an obstructive condition and an unremarkable abdominal history. The most common location is between the ascending colon and the terminal ileum, followed by the Treitz ligament and the terminal ileum,<sup>10</sup> and may cause both small bowel strangulation and abdominal pain in patients with functional bowel disease. There are no specific imaging tests, but CT, MRI, and barium meal tests, if feasible, suggest diagnosis. Diagnostic-therapeutic surgical treatment using open laparotomy or laparoscopy consists of resection of the web and the necrotic bowel segment. In our patient, bowel dilatation and atony caused by hypothyroidism triggered torsion and incarceration of the proximal bowel segment over the congenital web axis, requiring surgical resection of the necrotic segment.

To sum up, an exceptional and potentially fatal complication of preparation in a hypothyroid state for  $^{131}\text{I}$  ablation therapy in patients with DTC is reported. Differential diagnosis of an abdominal condition in a myxedematous patient should include the uncommon presence of a congenital web unmasked by bowel hypomotility caused by hypothyroidism.

## References

1. Ebert EC. The thyroid and the gut. *J Clin Gastroenterol.* 2010;44:402–6.
2. Kumar N, Wheeler MH. Hypothyroidism presenting as acute abdomen. *Postgrad Med J.* 1997;73:373–4.
3. Pacini F, Ladenson PW, Schlumberger M, Driedger A, Luster M, Kloos RT, et al. Radioiodine ablation of thyroid remnants after preparation with recombinant human thyrotropin in differentiated thyroid carcinoma: results of an international, randomized, controlled study. *J Clin Endocrinol Metab.* 2006;91:926–32.
4. Tobin MV, Fisker RA, Diggory RT, Morris AI, Gilmore IT. Orocaecal transit time in health and in thyroid disease. *Gut.* 1989;30:26–9.
5. Eastwood GL, Braverman LE, White EM, Vander Salm TJ. Reversal of lower esophageal sphincter hypotension and esophageal aperistalsis after treatment for hypothyroidism. *J Clin Gastroenterol.* 1982;4:307–10.
6. Kahraman H, Kaya N, Demirçali A, Bernay I, Tanyeri F. Gastric emptying time in patients with primary hypothyroidism. *Eur J Gastroenterol Hepatol.* 1997;9:901–4.
7. Rahman Q, Haboubi NY, Hudson PR, Lee GS, Shah IU. The effect of thyroxine on small intestinal motility in the elderly. *Clin Endocrinol (Oxf).* 1991;35:443–6.
8. Borrie MJ, Cape RD, Troster MM, Fung ST. Myxedema megacolon after external neck irradiation. *J Am Geriatr Soc.* 1983;31:228–30.
9. Wells I, Smith B, Hinton M. Acute ileus in myxoedema. *Br Med J.* 1977;1:211–2.
10. Akgür FM, Tanyel FC, Büyükpamukçu N, Hiçsönmez A. Anomalous congenital bands causing intestinal obstruction in children. *J Pediatr Surg.* 1992;27:471–3.
11. Habib E, Elhadad A. Small bowel obstruction by a congenital band in 16 adults. *Ann Chir.* 2003;128:94–7.

Manuel Luque-Ramírez<sup>a,\*</sup>, Joaquín Gómez Ramírez<sup>b,d</sup>,  
Andrea Azcárate Villalón<sup>a,c</sup>, Elena Martín Pérez<sup>b,d</sup>,  
Eduardo Larrañaga Barrera<sup>b</sup>

<sup>a</sup> Servicio de Endocrinología y Nutrición, Hospital Universitario de La Princesa, Madrid, Spain

<sup>b</sup> Servicio de Cirugía General y Aparato Digestivo, Hospital Universitario de La Princesa, Madrid, Spain

<sup>c</sup> Current address: Endocrinología y Nutrición, Hospital Sanitas La Moraleja, Madrid, Spain

<sup>d</sup> Current address: Servicio de Cirugía General. Cuello y Mama, Hospital Fundación Jiménez Díaz, Madrid, Spain

\* Corresponding author.

E-mail addresses: [manuel.luque@salud.madrid.org](mailto:manuel.luque@salud.madrid.org), [manuluque@gmail.com](mailto:manuluque@gmail.com) (M. Luque-Ramírez).

## Papillary thyroid microcarcinoma diagnosed based on cyst-like mediastinal metastasis<sup>☆</sup>

### Microcarcinoma papilar de tiroides diagnosticado por una metástasis quística en el mediastino

#### Introduction

Papillary thyroid microcarcinoma (PMC) is defined as a papillary carcinoma 1 cm or less in size. PMC is a variant of papillary carcinoma, the most common thyroid cancer, which has a very good prognosis and in which distant metastases and death (0.4–1% per year) are exceptional.<sup>1</sup>

We report a patient who was diagnosed with metastasis of a papillary microcarcinoma as the result of an evaluation of a mediastinal mass. This was an asthmatic patient aged 38 years with no history of neck irradiation or family history of thyroid cancer. The surgery department referred the patient to the endocrinological department after surgery for a cystic tumor, 7 cm in diameter, in the posterosuperior mediastinum (Figs. 1 and 2) after the histological study reported the finding in an intraoperative biopsy of a cystic wall of fibrous tissue with thyroid follicles without atypia and associated lymphocyte infiltrate consistent with pharyngeal pouch abnormalities. The final pathological study showed a cystic formation with a wall consisting of fibrous stroma with thyroid follicles, many of them with involutive phenomena, while others showed slight anisonucleosis and some “frosted glass” nuclei. Lymphoid tissue sectors coexisted with histiocyte clusters and calcification foci. The final diagnosis was metastasis from a papillary carcinoma in the cyst-like lymph node. The patient was clinically euthyroid, with a normal thyroid gland on palpation and no adenopathies on physical examination. Ultrasound examination of the thyroid and neck showed a hypoechoic image 5.7 mm × 3.1 mm in size in the left lobe with no pathological nodes. The functional thyroid study was within normal parameters, with negative antithyroid antibodies. Additional surgery performed in this case consisted of total thyroidectomy with bilateral level VI lymph node excision and the examination of both jugular

chains. A delayed biopsy revealed a thyroid papillary microcarcinoma in the right lobe, 2 mm in diameter limited by the gland and a small 5-mm follicular adenoma in the left lobe, with bilateral recurrent lymph nodes negative for metastasis. In a hypothyroid state with a TSH level of 85 mIU/L and stimulated thyroglobulin level of 2.55 ng/mL with negative antithyroid antibodies as measured by an ultra-

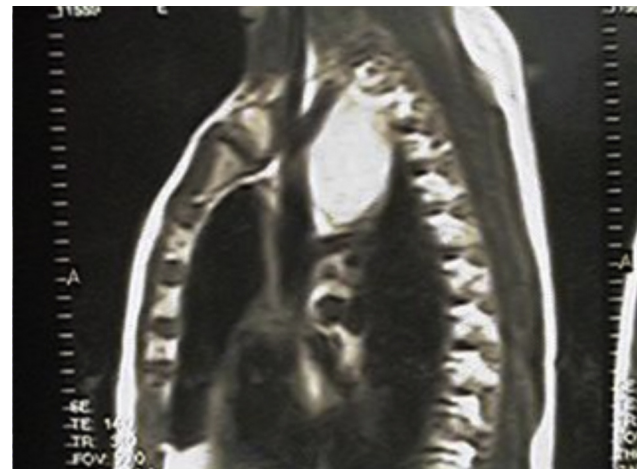


Figure 1 Preoperative MRI of the chest showing an image in the posterosuperior mediastinum.

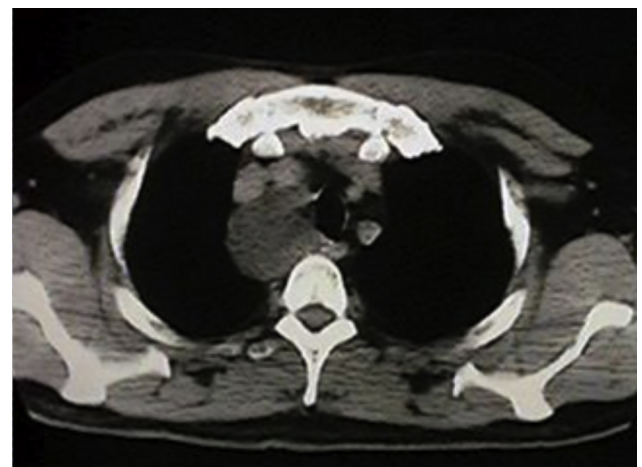


Figure 2 Preoperative MRI of the chest showing an image in the posterosuperior mediastinum.

<sup>☆</sup> Please cite this article as: Faure EN, González AJ, Schwarzstein D, Lutfi RJ, Puig-Domingo ML. Microcarcinoma papilar de tiroides diagnosticado por una metástasis quística en el mediastino. *Endocrinol Nutr.* 2013;60:414–416.