

In our case we opted for surgical treatment of the left carotid aneurysm due to its large size and consequent high risk of embolisms. The decision to use open surgery was based on the low surgical risk and the accessible anatomy.

References

1. Rittenhouse EA, Radke HM, Summer DS. Carotid artery aneurysm: review of the literature and report of a case with rupture into the oropharynx. *Arch Surg.* 1972;105:786–9.
2. Corteguera Torres D, Eliseo Mussenden O, Peguero Bringuez Y, García Lisame M, Díaz Hernández O. Aneurisma de la carótida extracraneal, Reporte de 2 casos. *Rev Cubana Ang.* 2007;8: 127–30.
3. Zhou W, Lin PH, Bush RL, Peden E, Guerrero MA, Terramani T, et al. Carotid artery aneurysm: evolution of management over two decades. *J Vasc Surg.* 2006;43:493–6.
4. Esteban-Jiménez O, Piñol-Ripoll G, González-Rubio F, Mauri-Llerda A, Navarro-Peman C, Mostacero-Miguel E. Ictus isquémico en un paciente con aneurismas gigantes de carótida interna. *Rev Neurol.* 2008;46:344–6.
5. Estevan Solano JM. Tratado de aneurismas. In: *Aneurismas de carótida extracraneal.* Uriach ed. Barcelona: Cayfosa; 1997.
6. Lee CC, Hsieh TC, Wang YC, Lo YL, Lee ST, Yang TC. Ruptured symptomatic internal carotid artery dorsal wall aneurysm with rapid configuration alchange. Clinical experience and management outcome: an original article. *Eur J Neurol.* 2010;17:1277–84.
7. Rossi P, Mirallie E, Pittaluga P, Chaillou P, Patra P. Bilateral extracranial aneurysm of the internal carotid artery. A case report. *J Cardiovasc Surg.* 1997;38:27–31.
8. May J, White HG, Richard W, Brennan J. Endoluminal repair of internal carotid aneurysm: a feasible but hazardous procedure. *J Vasc Surg.* 1997;26:1055–66.
9. Nishinari K, Wolosker N, Yazbek G, Vinicius C, Zottele A. Covered Stent Treatment for an aneurysm of a saphenous vein graft to the common carotid artery. *Ann Vasc Surg.* 2010;24:9–12.

N. Argilés Mattes, E. Hernández-Osma*, C. Berga Fauria, V. Sanchez Salvador

Servicio de Angiología, Cirugía Vasculay Endovascular, Hospital Universitario Joan XXIII, Tarragona, Spain

*Corresponding author.

E-mail address: eho51@hotmail.com

(E. Hernández-Osma).

doi:10.1016/j.nrleng.2011.02.003

REM sleep behaviour disorder and “pure” autonomic failure: Presentation of two cases[☆]

Trastorno de conducta del sueño REM y fallo autonómico ¿puro? A propósito de 2 casos

Sir,

The need for a diagnosis in the early stages of Parkinson's disease (PD) has led to increasingly more studies about early-stage signs and symptoms being published. A stereotyped and orderly progression of Lewy bodies in the brains of patients with PD¹ has been reported, but this α -synuclein deposit is not necessarily correlated with neuronal dysfunction or death and, therefore, with the symptoms. Thus, the first symptoms of PD can be very varied.² Longitudinal studies have shown that REM sleep behaviour disorder (RBD) can precede the diagnosis of a neurodegenerative disease (α -synucleinopathies), preferentially PD,³ in up to 45% of cases. It is known that autonomic failure is a late complication of PD and dementia with Lewy bodies (DLB), although it can sometimes constitute the presentation symptom.^{4,5} We recently described how a carrier of a mutation in the gene for α -synuclein (SNCA) presented dysautonomia as a sign of onset of her disease.⁶

We present the cases of 2 patients with idiopathic RBD and peripheral autonomic failure without signs or symptoms of neurodegenerative disease. We discuss the risk of developing synucleinopathies and the implications of an early diagnosis.

Case 1. This patient was a 66-year-old male with no family history of neurodegenerative diseases. In 2004, he attended consultation for a sleep disorder consisting of nightmares, restless sleep and falling from the bed, which the patient referred having suffered for years. A polysomnography recorded during REM sleep found increased phasic phenomena and a loss of the physiological atonia of this phase. We gave a diagnosis of RBD, which improved with clonazepam (0.5 mg). Six months later he suffered cough syncope. A vegetative nervous system study showed a fixed heart rate unchanged by the Valsalva manoeuvre, administration of ephedrine or standing. There was also orthostatic hypotension (supine position 148/80 mmHg, HR 53; standing 120/65 mmHg, HR 53). He presented noradrenaline values while lying of 26 pg/ml (VN: 100–750), which rose to 124 pg/ml (VN: 200–1700) when standing. Olfactory deficit was not detected (11/12 items identified correctly in the Brief Smell Identification Test, BSIT). There was a marked uptake decrease in myocardial-MIBG SPECT I (Fig. 1). A brain CT (MRI could not be performed due to the presence of metal particles) was normal. A 123-I-FP-CIT SPECT found no striatal uptake defects (Fig. 1). This exploration was repeated 2 years later and showed normal values, although the striated/occipital lobe uptake ratios had decreased discretely.

Case 2. This patient was a 60-year-old woman who attended consultation due to repeated syncope and orthostatic intolerance, of 10 years' evolution. She described

[☆] Please cite this article as: Tijero B, et al. Trastorno de conducta del sueño REM y fallo autonómico ¿puro? A propósito de 2 casos. *Neurología.* 2011;27:55–7.

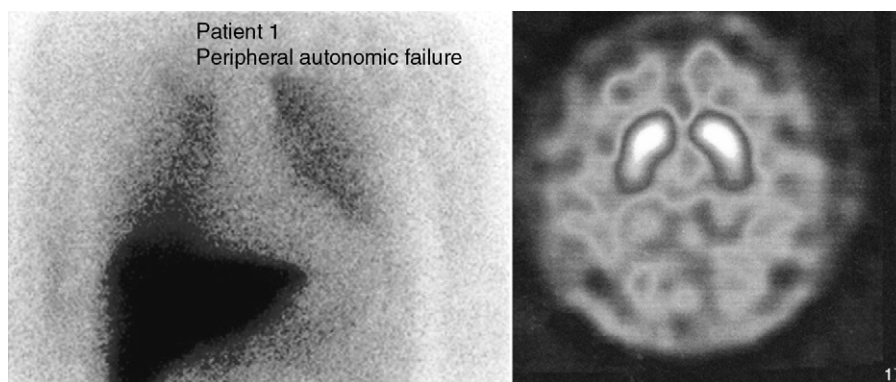


Figure 1 Nuclear medicine tests in the first case. The left part of the cardiac-MIBG SPECT shows a significantly low cardiac uptake. The right 123-I-FP-CIT SPECT (DAT-SCAN) is normal.

other dysautonomic symptoms such as constipation and voiding problems: tenesmus and nocturia. She also presented a decrease in olfaction (7/12 in the BSIT). She reported vivid dreams and movement during sleep and the polysomnography found a loss of atonia during REM sleep. The dysautonomic study detected orthostatic hypotension on the tilting table (standing: 103/54 mmHg, HR 66; supine position 66/34 mmHg, HR 55) and nocturnal arterial hypertension in her blood pressure Holter results. Catecholamine study revealed a significant depletion of noradrenaline (supine position 17 pg/ml; standing, 31 pg/ml) with an increase of vasopressin during postural changes (supine position 3.9 pg/ml, standing 5.1 pg/ml). Both the Valsalva ratio (1.8) and the variability of heart rate with breathing were at the lower limit of normality. The reflex-sympathetic skin test was pathological in the lower limbs. The cranial MRI did not detect abnormalities that indicated the presence of multisystem atrophy (MSA). We performed a cardiac-MIBG SPECT with a myocardial/mediastinum ratio at 4 h of 1.8 (VN > 1.7), while the 123-I-FP-CIT SPECT was normal.

The 2 patients described met the criteria for the diagnosis of RBD. The study results of both patients pointed towards a primary autonomic failure with sympathetic and parasympathetic postganglionic involvement.⁷ This entity includes 3 neurodegenerative diseases: pure autonomic failure (PAF), Parkinson's disease (PD) and multisystem atrophy (MSA).⁸ Autonomic dysfunction in MSA is due to the degeneration of the preganglionic neurons, with α -synuclein cytoplasmic inclusions being found in neurons and glial cells of the brain stem and spine.⁹ The sympathetic ganglia and postganglionic terminals are not affected. In contrast, the involvement of the vegetative nervous system in PD and PAF is predominantly postganglionic. Lewy bodies and neurites are found in the sympathetic ganglia and myenteric plexuses¹⁰ and, to a lesser extent, in the intermediolateral horns.¹¹

There have been reports of reduced cardiac MIBG uptake in patients with RBD¹² without other additional symptoms, unlike the cases described above, with no clinical signs of dysautonomia. This shows that hypoperfusion in cardiac-MIBG SPECT may be an early finding and precede the onset of motor manifestations. Olfaction deficit, with the same characteristics as in PD patients, has also been reported in this group of patients.¹³

The hypothesis that neurodegeneration in PD and DLB may begin in the postganglionic autonomic neurons¹⁰ has important therapeutic and diagnostic implications, given that the study of the vegetative nervous system can be a useful tool in identifying patients in premotor stages, prior to neuronal degeneration of the substantia nigra. Recently, synuclein inclusions have been detected in the nerve fibres of cutaneous sweat glands in patients with pure autonomic failure.¹⁴ The administration of drugs with neuroprotective effects, such as rasagiline, could be indicated in this group of patients. However, we believe that this should be preceded, firstly, by prospective studies that define the values of different biomarkers in these disorders¹⁵ and, secondly, by long-term clinical trials with these indications (RBD and pure autonomic failure).

References

1. Braak H, del Tredici K, Rub U, de Vos RA, Jansen Steur EN, Braak E. Staging of brain pathology related to sporadic Parkinson's disease. *Neurobiol Aging*. 2003;24:197–211.
2. Tolosa E, Gaig C, Santamaria J, Compta Y. Diagnosis and the premotor phase of Parkinson disease. *Neurology*. 2009;72:S12–20.
3. Iranzo A, Molinuevo JL, Santamaria J, Serradell M, Marti MJ, Valldeoriola F, et al. Rapid-eye-movement sleep behaviour disorder as an early marker for a neurodegenerative disorder: a descriptive study. *Lancet Neurol*. 2006;5:572–7.
4. Kaufmann H, Nahm K, Purohit D, Wolfe D. Autonomic failure as the initial presentation of Parkinson disease and dementia with Lewy bodies. *Neurology*. 2004;63:1093–5.
5. Goldstein DS, Holmes C, Li ST, Bruce S, Metman LV, Cannon 3rd RO. Cardiac sympathetic denervation in Parkinson disease. *Ann Intern Med*. 2000;133:338–47.
6. Tijero B, Gomez-Esteban JC, Llorens V, Lezcano E, Gonzalez-Fernandez MC, de Pancorbo MM, et al. Cardiac sympathetic denervation precedes nigrostriatal loss in the E46K mutation of the alpha-synuclein gene (SNCA). *Clin Auton Res*. 2010;20:267–9.
7. Bannister R, Mathias C. Clinical features and evaluation of the primary chronic autonomic failure syndromes. In: Mathias C, Bannister R, editors. *Autonomic failure. A textbook of clinical disorders of the autonomic nervous system*. 4th ed. New York: Oxford University Press; 1999. p. 307–17.
8. Kaufmann H. Primary autonomic failure: three clinical presentations of one disease? *Ann Intern Med*. 2000;133:382–4.

9. Benarroch EE, Smithson IL, Low PA, Parisi JE. Depletion of catecholaminergic neurons of the rostral ventrolateral medulla in multiple systems atrophy with autonomic failure. *Ann Neurol*. 1998;43:156–63.
10. Minguez-Castellanos A, Chamorro CE, Escamilla-Sevilla F, Ortega-Moreno A, Rebollo AC, Gomez-Rio M, et al. Do alpha-synuclein aggregates in autonomic plexuses predate Lewy body disorders?: a cohort study. *Neurology*. 2007;68:2012–8.
11. Benarroch EE, Schmeichel AM, Parisi JE. Involvement of the ventrolateral medulla in Parkinsonism with autonomic failure. *Neurology*. 2000;54:963–8.
12. Miyamoto T, Miyamoto M, Inoue Y, Usui Y, Suzuki K, Hirata K. Reduced cardiac I-MIBG scintigraphy in idiopathic REM sleep behavior disorder. *Neurology*. 2006;2236–8.
13. Fantini ML, Postuma RB, Montplaisir J, Ferini-Strambi L. Olfactory deficit in idiopathic rapid eye movements sleep behavior disorder. *Brain Res Bull*. 2006;70:386–90.
14. Shishido T, Ikemura M, Obi T, Yamazaki K, Terada T, Sugiura A, et al. Alpha-synuclein accumulation in skin nerve fibers

revealed by skin biopsy in pure autonomic failure. *Neurology*. 2010;74:608–10.

15. Iranzo A, Lomena F, Stockner H, Valldeoriola F, Vilaseca I, Salamero M, et al. Decreased striatal dopamine transporter uptake and substantia nigra hyperechogenicity as risk markers of synucleinopathy in patients with idiopathic rapid-eye-movement sleep behaviour disorder: a prospective study [corrected]. *Lancet Neurol*. 2010;9:1070–7.

B. Tijero*, J.C. Gómez-Esteban, K. Berganzo, J.J. Zarranz
Servicio de Neurología, Hospital de Cruces, Baracaldo, Bilbao, Spain

* Corresponding author.

E-mail address: beatriz.tijero@hotmail.com (B. Tijero).

doi:10.1016/j.nrleng.2011.03.008

Comments on the published Letter to the Editor by Martínez-Lapiscina et al.: "Epileptic seizure and lipoma of the corpus callosum: Cause or finding"*

Comentarios a la carta del editor publicada por Martínez-Lapiscina et al: «Crisis epiléptica y lipoma del cuerpo calloso: causa o hallazgo»

Sir,

We read with great interest the recent article by Martínez-Lapiscina et al., "Epileptic seizures and lipoma of the corpus callosum: cause or finding".¹ As the authors demonstrate, "intracranial lipomas can cause epileptic seizures and their correct diagnosis has prognostic and therapeutic implications".

Some years ago we published a case of lipoma of the corpus callosum in a 42-year-old male who died suddenly due to food aspiration as a result of an epileptic seizure while he was dining. A neuropathological study revealed two curvilinear lipomas located at the top of the genu of the corpus callosum (2.5 cm × 0.7 cm and 1.5 cm × 0.5 cm, respectively). These consisted of mature adipose tissue and were very well vascularised. They were not associated with developmental abnormalities of the corpus callosum.²

It is noteworthy that our patient had presented two previous seizures at 28 and 40 years of age, so he had undergone EEG, CT and MRI scans; these showed "brain fat", as reported by the family (we did not have access to medical records). The patient was not following anticonvulsant therapy, since no clinical indication was considered.

This fact was confirmed by a negative result in the chemical-toxicological analysis performed.

Recently, we had another case of lipoma of the corpus callosum as an incidental finding during the autopsy of a 41-year-old woman who died suddenly due to digestive pathology. It was a tubulonodular lipoma measuring 2 cm × 4 cm, of interhemispheric location, situated in the anterior corpus callosum. It was not associated to any dysgenesis or other neuronal migration abnormalities (Fig. 1). Although the patient had not presented epileptic seizures, she had a history of headache and mild psychomotor retardation. The facies was somewhat coarse, with frontal prominence and low-set ears, suggesting a defect in the development of the midline, as other authors have mentioned.^{3–5} Intracranial lipomas are rare congenital malformations, representing only 0.03–0.08% of all intracranial masses.^{2,3} In the past 6–1/2 years, we have performed a total of 6011 legal autopsies at our department and found

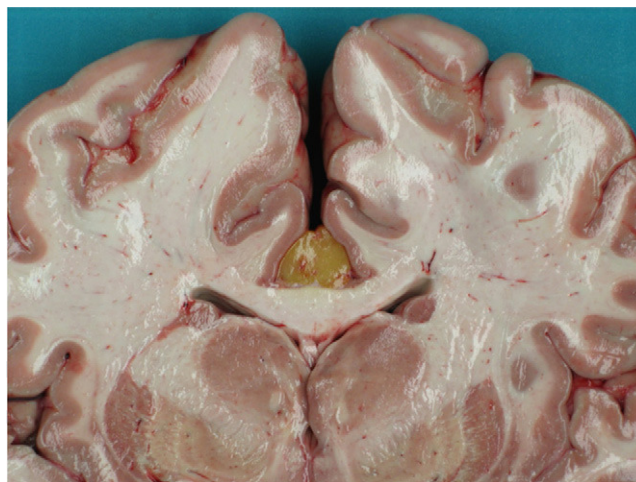


Figure 1 Fresh coronal section of the brain at the level of the basal ganglia. It is possible to observe an interhemispheric lipoma located in the anterior part of the corpus callosum.

* Please cite this article as: Lucena Romero JS, et al. Comentarios a la carta del editor publicada por Martínez-Lapiscina et al: «Crisis epiléptica y lipoma del cuerpo calloso: causa o hallazgo». *Neurología*. 2011;27:57–8.