

LETTERS TO THE EDITOR

Retrograde venous cerebral air embolism as a cause of stroke ☆☆☆

Embolia aérea por mecanismo venoso retrógrado como causa de ictus isquémico

Sir,

Aerial, arterial or venous embolisms are usually a complication derived from invasive medical procedures.^{1,2} One of the most common causes of aerial venous embolism is the insertion, maintenance or removal of a central venous catheter (CVC).^{3,4} The entry of air may occur if central venous pressure is less than atmospheric pressure, a condition that occurs in the superior vena cava when patients have an elevated chest position or during Valsalva manoeuvres.⁵ The neurological symptoms due to air embolism are non-specific and include altered level of consciousness, comitial seizures and stroke.⁶

We describe the case and neuroimaging of a patient with ischaemic stroke due to air embolism during manipulation of a CVC.

The patient was a 76-year-old male admitted due to acute renal failure in the context of an anaphylactic reaction which required the placement of a right, central, venous jugular catheter to perform haemodialysis. Immediately after removal of the catheter, which was performed in a sitting position, the patient suffered a sudden loss of consciousness with conjugate gaze deviation to the right side and tetraparesis. Neither hypotension nor hypoxia was detected. An urgent cranial CT scan (Fig. 1), obtained 1 h after onset of symptoms, revealed areas of hypodensity in the right superficial cortical veins and extensive collections of gas in the right jugular vein, in both cavernous sinuses (Fig. 2) and in subcutaneous structures. No images of acute ischaemia were found in the diffusion sequences of a magnetic resonance imaging (MRI) scan performed 30 min later. The patient presented gradual clinical improvement with persistence of paresis of the left upper

limb. A cranial MRI at 72 h (Fig. 3) revealed restriction areas in diffusion sequences and hyperintense areas in T2 sequences located in the cortical sulci where gas bubbles had previously been observed, suggestive of venous stroke. A transesophageal echocardiogram and a transcranial Doppler with air-saline contrast did not show the presence of right-to-left shunt.

At the systemic level, the haemodynamic manifestations of a venous embolism are attributed to the massive inflow of air at the level of the right ventricle and the pulmonary circulation, leading to hypoxia with pulmonary hypertension, right ventricular failure, arrhythmias and cardiac failure.^{1,2} Cerebral ischaemic lesions due to venous air embolism may be secondary to paradoxical embolism by air with entry to the venous circuit and passage to the arterial circuit through a cardiac or pulmonary right-to-left shunt, or through massive venous air embolism overflowing the pulmonary filter. Exceptional cases with a retrograde venous mechanism have also been described.^{7,8} Recent research has shown that an air embolism through a standard venous catheter has a high possibility of ascending through a retro-

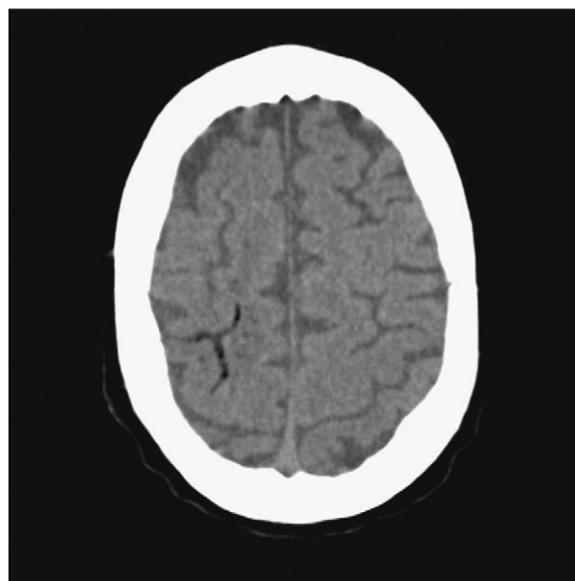


Figure 1 Brain CT scan performed 1 h after the onset of symptoms. Serpiginous images with air density in the parietal cortical area.

☆ This work was partly presented as a poster at the 19th ESC in Stockholm, in 2009.

☆☆ Please cite this article as: Pellisé A, et al. Embolia aérea por mecanismo venoso retrógrado como causa de ictus isquémico. *Neurología*. 2011;27:119–21.

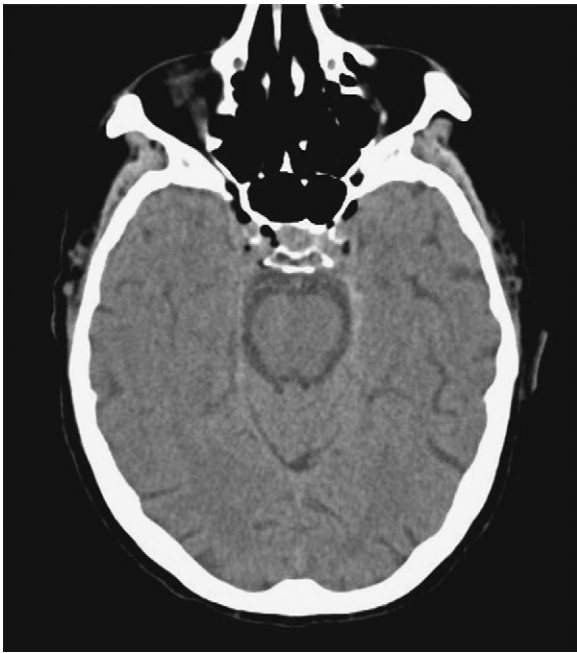

Figure 2 Air collections at the level of both cavernous sinuses.

grade pathway by the venous circulation, depending on the size of the bubbles, the diameter of the catheter and the ejection fraction.^{9,10} Air embolism ischaemia is caused by several mechanisms: obstruction of blood flow, vasospasm and thrombus formation by platelet activation. The temporal relationship between the procedure and the stroke facilitates its diagnostic suspicion. Neuroimaging tests must be carried out immediately to detect the presence of gas;

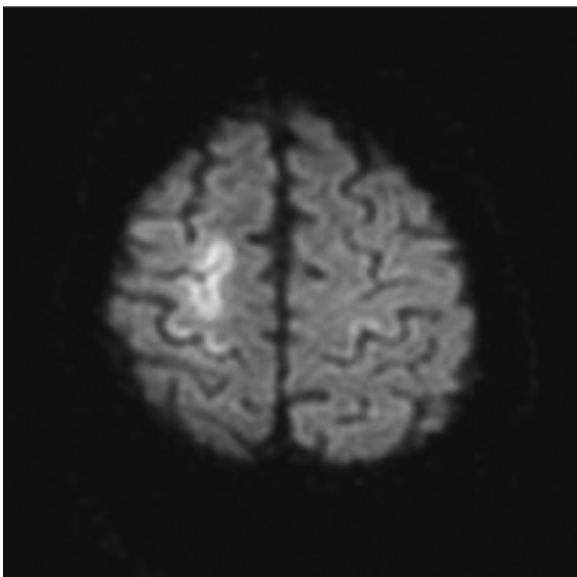


Figure 3 Brain MRI performed 72 h after the onset of symptoms. Diffusion weighted imaging: cortical areas with restricted diffusion and serpiginous shape, suggestive of recent venous stroke.

there is a predilection for frontal cortical involvement and especially for the border areas of the anterior and middle cerebral arteries.¹¹ Upon suspicion of retrograde air embolism, patients must be placed in the Trendelenburg position and in the left lateral decubitus position, with the aim of promoting the return of the bubbles to the central venous circulation. Oxygen should be administered both to treat hypoxia and to eliminate the gas by establishing a diffusion gradient. There have been various reports with good prognosis after receiving hyperbaric oxygen, and it has been proposed as the treatment of choice.^{12,13}

This case illustrates the pathophysiological mechanism of a retrograde venous pathway due to the presence of air in cervical and cranial venous structures, the absence of proven left–right shunt and the onset of cerebral venous stroke in the cortical folds in whose veins there was air detected in the early neuroimaging scans.

Air embolism must be suspected in patients with unexplained cardiovascular or neurological symptoms and CVC. Early diagnosis and treatment are essential. The retrograde venous mechanism should be considered in patients without right-to-left shunt.

References

- Muth CM, Shank ES. Gas embolism. *N Engl J Med.* 2000;342:476–82.
- Van Hulst RA, Klein J, Lachmann B. Gas embolism: pathophysiology and treatment. *Clin Physiol Funct Imaging.* 2003;23:237–46.
- Hsiung GY, Swanson PD. Cerebral air embolism after central venous catheter removal. *Neurology.* 2000;55:1063–4.
- Brouns R, De Surgeloose D, Neetens I, De Deyn PP. Fatal venous cerebral air embolism secondary to a disconnected central venous catheter. *Cerebrovasc Dis.* 2006;21:212–4.
- Brockmeyer J, Simon T, Seery J, Johnson E, Armstrong P. Cerebral air embolism following removal of central venous catheter. *Mil Med.* 2009;174:878–81.
- Heckmann J, Lang C, Kindler K, Huk W, Erbguth F, Neundörfer B. Neurologic manifestations of cerebral air embolism as a complication of central venous catheterization. *Crit Care Med.* 2000;28:1621–5.
- Fracasso T, Kargel B, Schmidt P, Reinbold WD, Pfeiffer H. Retrograde venous cerebral air embolism from disconnected central venous catheter: an experimental model. *J Forensic Sci.* 2011;56:S101–4.
- Zickler P, Hartung HP, Janssen H. “Bubbles in the brain”: retrograde venous air embolism in the cavernous sinus. *Eur Neurol.* 2009;61:318.
- Schlimp CJ, Loimer T, Rieger M, Lederer W, Schmidts MB. The potential of venous air embolism ascending retrograde to the brain. *J Forensic Sci.* 2005;50:1–4.
- Schlimp CJ, Loimer T, Rieger M, Schmidts MB, Lederer W. Pathophysiological mechanism and immediate treatment of retrograde cerebral air embolism. *Intensive Care Med.* 2006;32:945.
- Jeon SB, Kim JS, Lee DK, Kang DW, Kwon SU. Clinicoradiological characteristics of cerebral air embolism. *Cerebrovasc Dis.* 2007;23:459–62.
- Gibson AJ, Davis FM. Hyperbaric oxygen therapy in the treatment of post cardiac surgical strokes—a case series and review of the literature. *Anaesth Intensive Care.* 2010 Jan;38:175–84.
- Balsara ZN, Burks DD. Hyperbaric oxygen therapy for arterial air embolism. *AJR Am J Roentgenol.* 2007;188:W98.

A. Pellisé^{a,*}, X. Ustrell^a, V. Ruiz^b, A. Guedea^c

^a *Servicio de Neurología, Hospital Universitari Joan XXIII, IISP, Universitat Rovira i Virgili, Tarragona, Spain*

^b *Servicio de Nefrología, Hospital Universitari Joan XXIII, IISP, Universitat Rovira i Virgili, Tarragona, Spain*

^c *Servicio de Radiología, Hospital Universitari Joan XXIII, IDI, Tarragona, Spain*

*Corresponding author.

E-mail address: apellise.hj23.ics@gencat.cat (A. Pellisé).

doi:10.1016/j.nrleng.2011.05.002

Letter with reference to the article "Importance of electromyographic studies in the diagnosis of orthostatic tremor"[☆]

Carta en relación con el artículo «Importancia del estudio electromiográfico en el diagnóstico del temblor ortostático»

Sir,

We read with great interest the article published recently by Yagüe et al.¹ about the importance of electromyographic study in the diagnosis of orthostatic tremor. Our intention is not to assess the pathophysiological-diagnostic aspect of the article, brilliantly exposed by the authors who provide electromyographic concepts that demonstrate the growing and undeniable importance of electrophysiological analysis in the study of movement disorders. As the authors note, orthostatic tremor is an idiopathic motor disorder, although its possible association with pons lesions² or cerebellar degeneration^{3,4} has been reported. Both of these constitute symptomatic forms of orthostatic tremor. It has been speculated that these anatomical structures (brainstem and cerebellum) could be directly involved in the pathogenesis and modulation of orthostatic tremor,^{5,6} in a manner similar to what might happen in essential tremor.⁷⁻⁹ We have noted that, in the case presented by Yagüe et al.,¹ the patient presented a deficiency of vitamin B12 in her medical history, and this has motivated us to write this letter to highlight the possible association existing between orthostatic tremor and vitamin B12 deficiency. Eleven years ago, our group published the case of a patient with orthostatic tremor who also suffered vitamin B12 deficiency.¹⁰ While we recognise that this association is difficult to justify from the standpoint of biological plausibility, the fact that, following the reinstatement of the deficient vitamin, the tremor disappeared does strengthen this causal association. Since then, other cases have been published in which vitamin B12 deficiency has been associated with tremor.^{11,12} Furthermore, several neuroimaging studies have revealed abnormalities in the cerebellum and pons of patients with vitamin B12 deficiency.^{13,14} We believe these studies lend plausibility to the hypothesis of there being a causal inference between vitamin B12 deficiency and orthostatic tremor.

[☆] Please cite this article as: Labiano-Fontcuberta A, Benito-León J. Carta en relación con el artículo «Importancia del estudio electromiográfico en el diagnóstico del temblor ortostático». *Neurología*. 2011;27:121-2.

References

1. Yagüe S, Veciana M, Pedro J, Campdelacreu J. Importancia del estudio electromiográfico en el diagnóstico del temblor ortostático. *Neurología*. 2011;26:53-4.
2. Benito-León J, Rodríguez J, Ortí-Pareja M, Ayuso-Peralta L, Jiménez-Jiménez FJ, Molina JA. Symptomatic orthostatic tremor in pontine lesions. *Neurology*. 1997;49:1439-41.
3. Benito-León J, Rodríguez J. Orthostatic tremor with cerebellar ataxia. *J Neurol*. 1998;245:815.
4. Manto MU, Setta F, Legros B, Jaquy J, Godeaux E. Resetting of orthostatic tremor associated with cerebellar cortical atrophy by transcranial magnetic stimulation. *Arch Neurol*. 1999;56:1497-500.
5. Piboolnurak P, Yu QP, Pullman SL. Clinical and neurophysiologic spectrum of orthostatic tremor: case series of 26 subjects. *Mov Disord*. 2005;20:1455-61.
6. Spiegel J, Fuss G, Krick C, Dillmann U. Impact of different stimulation types on orthostatic tremor. *Clin Neurophysiol*. 2004;115:569-75.
7. Benito-León J, Louis ED. Clinical update: diagnosis and treatment of essential tremor. *Lancet*. 2007;369:1152-4.
8. Benito-León J, Louis ED. Essential tremor: emerging views of a common disorder. *Nat Clin Pract Neurol*. 2006;2:666-78.
9. Benito-León J, Alvarez-Linera J, Hernández-Tamames JA, Alonso-Navarro H, Jiménez-Jiménez FJ, Louis ED. Brain structural changes in essential tremor: voxel-based morphometry at 3-Tesla. *J Neurol Sci*. 2009;287:138-42.
10. Benito-León J, Porta-Etessam J. Shaky-leg syndrome and vitamin B12 deficiency. *N Engl J Med*. 2000;342:981.
11. Koussa S, Taher A, Sayegh R. Postural and kinetic tremor associated with vitamin B12 deficiency. *Rev Neurol (Paris)*. 2003;159:1173-4.
12. Kumar S. Vitamin B12 deficiency presenting with an acute reversible extrapyramidal syndrome. *Neurol India*. 2004;52:507-9.
13. Katsaros VK, Glocker FX, Hemmer B, Schumacher M. MRI of spinal cord and brain lesions in subacute combined degeneration. *Neuroradiology*. 1998;40:716-9.
14. Morita S, Miwa H, Kihira T, Kondo T. Cerebellar ataxia and leukoencephalopathy associated with cobalamin deficiency. *J Neurol Sci*. 2003;216:183-4.

A. Labiano-Fontcuberta^{a,b}, J. Benito-León^{a,b,c,*}

^a *Servicio de Neurología, Hospital Universitario 12 de Octubre, Madrid, Spain*

^b *Departamento de Medicina, Facultad de Medicina, Universidad Complutense, Madrid, Spain*

^c *Centro de Investigación Biomédica en Red sobre Enfermedades Neurodegenerativas (CIBERNED), Madrid, Spain*

*Corresponding author.

E-mail address: jbenitol@meditex.es (J. Benito-León).

doi:10.1016/j.nrleng.2011.03.010