

## Sulcal hyperintensity on FLAIR-MRI in a case of idiopathic intracranial hypertension<sup>☆,☆☆</sup>

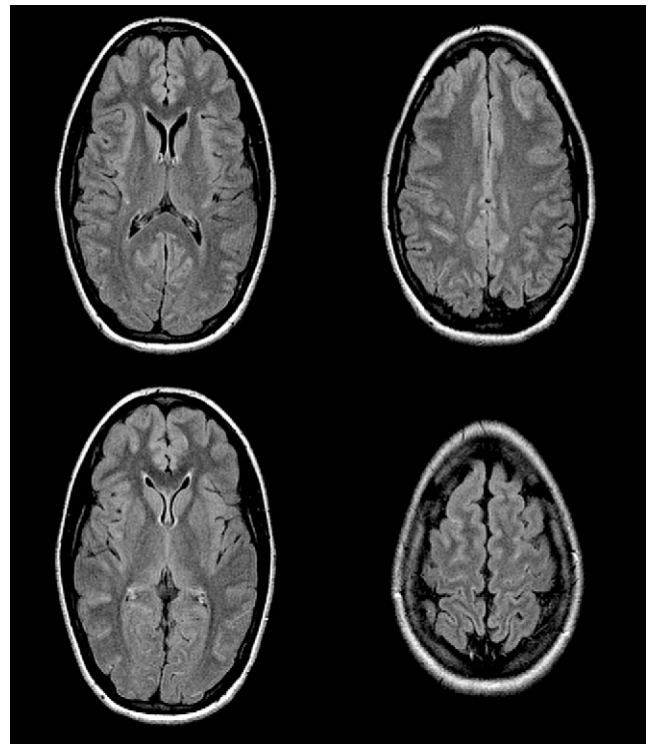
### Hiperintensidad de surcos en FLAIR en un caso de hipertensión intracraneal idiopática

Dear Editor:

Neuroimaging has traditionally been used in idiopathic intracranial hypertension (IIH) for the purpose of ruling out other causes of increased intracranial pressure. Nevertheless, in recent years researchers have described radiological signs associated with this entity, such as flattening of the globe, horizontal tortuosity of the optic nerve, and enlarged optic nerve sheath, among others.<sup>1</sup>

We present the case of a 15-year-old female who had been treated with isotretinoin during the preceding 7 months. She requested a medical consultation due to experiencing headache, blackouts, and loss of visual acuity during the course of one week. The physical examination found bilateral papilloedema, decreased visual acuity, peripheral visual field constriction, and enlarged blind spot. We performed a cranial CT which showed normal results. Magnetic resonance imaging revealed sulcal hyperintensity on FLAIR images, especially in the bilateral frontal and occipital convexities (Fig. 1). We observed no significant alterations in the gradient echo sequence and no signs of venous thrombosis after injection of contrast. We then performed a lumbar puncture. Cerebrospinal fluid (CSF) opening pressure was 56 cm of water, with a red blood cell count of 1/μL, leukocytes 2/μL, glucose 56 mg/dL and proteins 21 mg/dL, with no xanthochromia. The patient was diagnosed with IIH<sup>2</sup> according to current diagnostic criteria, and treated with acetazolamide. Clinical progress was good.

Sulcal hyperintensity on FLAIR (fluid-attenuated inversion recovery) magnetic resonance images is mainly associated with subarachnoid haemorrhage, meningitis, and meningeal carcinomatosis. Focal sulcal hyperintensity has also been described in mass effect lesions and diffuse sulcal hyperintensity in vascular lesions.<sup>3</sup> The phenomenon has also been reported in association with high doses of propofol and oxygen.<sup>4</sup> Likewise, the increase of venous pressure in cases of venous thrombosis may explain the presence of this radiological sign. However, our search of the literature revealed no links between sulcal hyperintensity on FLAIR images and IIH which might be relevant to the differential diagnosis. IIH may be another cause of this radiological sign, possibly because of an alteration in vascular dynamics, including slower CSF flow and a small amount of localised



**Figure 1** Magnetic resonance image (FLAIR) showing sulcal hyperintensity of the convexity in the frontal and occipital parasagittal regions.

protein leakage, according to the most widely accepted current pathogenic theory about IIH.<sup>2</sup> These alterations could also cause a failure to suppress CSF signal on FLAIR imaging.

## References

1. Degnan AJ, Levy LM. Pseudotumor cerebri: brief review of clinical syndrome and imaging findings. *American Journal of Neuroradiology*. 2011;32:1986–93.
2. Dhungana S, Sharrack B, Woodroffe N. Idiopathic intracranial hypertension. *Acta Neurologica Scandinavica*. 2010;121:71–82.
3. Taoka T, Yuh WTC, White ML, Quets JP, Maley JE, Ueda T. Sulcal hyperintensity on Fluid-Attenuated Inversion Recovery MR images in patients without apparent cerebrospinal fluid abnormality. *American Journal of Roentgenology*. 2001;176:519–24.
4. Maeda M, Yagishita A, Yamamoto T, Sakuma H, Takeda K. Abnormal hyperintensity within the subarachnoid space evaluated by fluid-attenuated inversion-recovery MR imaging: a spectrum of central nervous system diseases. *European Radiology*. 2003;13 Suppl. 4:L192–201.

J.A. Matias-Guiu\*, R. Barahona, M. Jorquera Moya, J. Porta-Etessam

*Hospital Clínico San Carlos, Madrid, Spain*

\*Corresponding author.

*E-mail address: jordimatiassguu@hotmail.com*  
(J.A. Matias-Guiu).

doi:10.1016/j.nrleng.2011.12.007

<sup>☆</sup> Please cite this article as: Matias-Guiu JA, et al. Hiperintensidad de surcos en FLAIR en un caso de hipertensión intracraneal idiopática. *Neurología*. 2012;27:313.

<sup>☆☆</sup> This study was presented in poster format at the 35th Annual Meeting of the Spanish Society of Neurology (Barcelona, 15–19 November 2011).