


NEUROLOGÍA

www.elsevier.es/neurologia



LETTERS TO THE EDITOR

Whipple's disease: Multiple systemic and neurological relapses[☆]

Enfermedad de Whipple: Múltiples recaídas sistémicas y neurológicas

Dear Editor:

Whipple's disease (WD) is an uncommon condition caused by persistent infection with *Tropheryma whipplei* (TW). Clinical manifestations vary greatly, and may include digestive, articular, ocular, cardiac, renal, pulmonary, and nervous system symptoms. We present the hospital reports for a 78-year old male patient who had been suffering numerous recurring and remitting febrile episodes with migratory polyarthritides since the age of 33. WD was diagnosed by duodenal biopsy when the patient was 53 and had been experiencing recurring diarrhoea over several months. The patient was then treated with oral trimethoprim/sulfamethoxazole (TS) for more than 6 years. In 1994, he presented with unstable gait due to normal pressure hydrocephalus, which was treated surgically. Results from the cytochemical analysis of CSF were normal (Fig. 1, (A) hydrocephalus and periventricular oedema and (B) resolution of hydrocephalus following ventriculo-atrial shunting). Patient was treated with TS for an additional 6 years. He remained asymptomatic until the age of 70, when he suffered 3 episodes of transient dysarthria in 6 months. At the age of 72, he developed an acute confusional state. Brain MRI revealed hyperintensities in the left hemisphere and asymmetrical ventricular dilation (Fig. 1C). CSF analysis showed normal cell counts and glucose and a very high protein level (2.5 g/L); both specific and non-specific cultures were negative. He underwent placement of a second cerebral shunt and during the procedure, doctors performed a biopsy on the periventricular region and intraventricular adhesions; PCR testing of the sample revealed PAS⁺ macrophages (Fig. 2, 1) and TW (Fig. 2, 2). Doctors also examined the sample with an electron microscope and found macrophage inclusions with trilaminar membranes and resembling bacilli.

Treatment with continuous sulfamethoxazole and trimethoprim was reinstated (800 mg and 160 mg, respectively, twice daily) in addition to intramuscular ceftriaxone (1g twice daily) for 2 months. Symptoms disappeared and a brain MRI taken when the patient was 77 showed no lesions (Fig. 1D). The patient was asymptomatic as of his last check-up in 2010, and on treatment with equal doses of trimethoprim and sulfamethoxazole. This clinical history was presented in poster format at the 86th Annual Meeting of the American Association of Neuropathologists, held from 9 to 13 June 2010. It was also published as an abstract.¹ Our current objective is to publish the case in Spanish.

Diagnosing WD may be difficult in patients who did not experience digestive symptoms from the onset. Polyarthralgias are the cardinal symptoms in half of all cases of the disease.² In the case described here, both of those characteristics were present. Central nervous system disorders may appear as communicating hydrocephalus, vertical gaze palsy, cerebrovascular events, convulsions, confusional state, progressive cognitive impairment, and very characteristic signs such as oculomasticatory myorhythmia.^{3,4} The case we describe presented with 3 of the neurological manifestations listed above. In patients with WD, macrophages have an abnormally acidic pH, which permits survival of TW within the cytoplasm.^{5–7} Prior to the development of antibiotics (ATBs), WD was fatal. The first ATBs used in WD treatment were penicillin and tetracyclines, but recurrences were very common. In recent decades guidelines have recommended ATBs that cross the blood–brain barrier, such as TS, which has been used since the 1970s. Recent suggestions include parenteral ceftriaxone and oral TS. Additional recommendations include oral cephalosporins and doxycycline as long-term treatment and hydroxychloroquine to modify the pH in macrophages,^{8–10} but these recommendations are based on infrequent case studies and not on controlled trials. Treatment time with ATB for cases of WD with neurological complications has not been established, and prolonged administration may be a reasonable option. Throughout this patient's long observation period, we have found that nervous system symptom relapses tended to appear after TS treatment had been suspended or reduced, or possibly after failure of prolonged TS treatment,¹¹ almost as if TW were waiting for lower concentrations of the bacteriostatic agent. When treating patients with WD and neurological manifestations, we suggest that the antibiotic that improves their condition should not be reduced or discontinued.

[☆] Please cite this article as: Domínguez RO, et al. Enfermedad de Whipple: Múltiples recaídas sistémicas y neurológicas. Neurología. 2013;28:57–9.

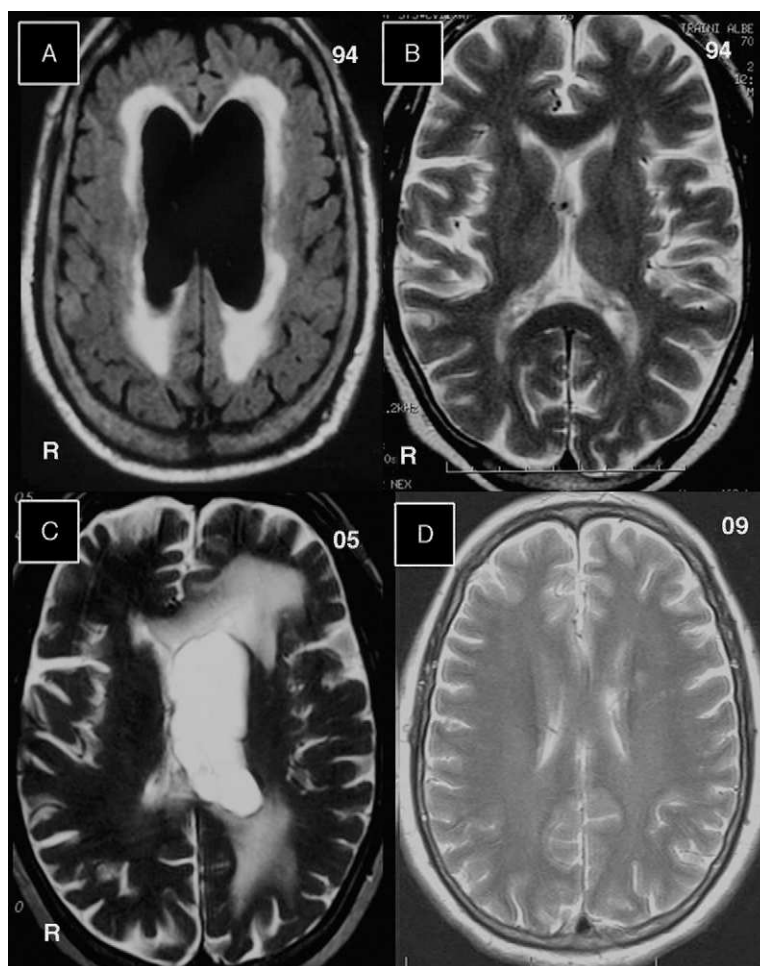


Figure 1 Brain MR images without gadolinium contrast enhancement. (A) In this FLAIR image from 1994, we see bilateral ventricular dilation with hyperintensities around ventricular cavities. (B) T2-weighted image taken 1 month after (A) and after placement of the ventriculo-atrial shunt. The ventricular cavities returned to normal. (C) T2-weighted image from 2005 showing dilation of the lateral ventricle in the left hemisphere and hyperintensities surrounding that ventricle. (D) T2-weighted image from 2009 showing normal-sized lateral ventricles and no changes to the cerebral parenchyma.

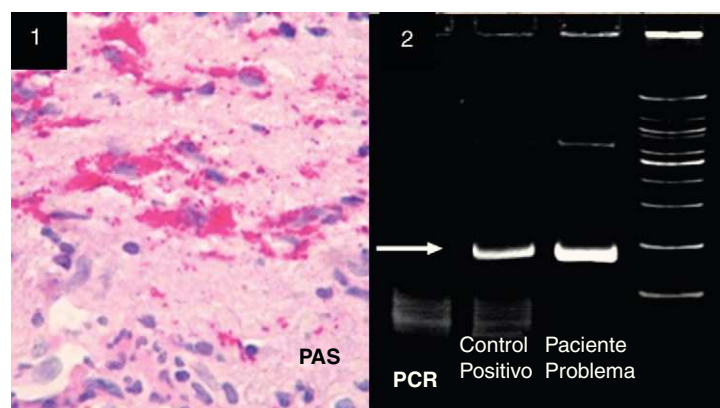


Figure 2 (1) Biopsy sample of brain and intraventricular adhesion tissue subjected to periodic acid Schiff test (PAS+), revealing lymphocytes and macrophages containing material consistent with TW bacteria. (2) Polymerase chain reaction (PCR) test; TW detected with 16s ribosomal RNA sequencing. These oligonucleotides can detect fragments of 160 base pairs in the presence of bacterial DNA. The white arrow indicates the intense white band in the column indicating our patient sample, compared to a positive control.

References

1. Taratuto AL, Zuccaro G, Arias E, Mac Keith P, Muller C, Dominguez R. Whipple's disease: an endless infection forty four years of disease and 15 years of brain involvement, report of a case. American Association of Neuropathologists, 86th Annual Meeting, Poster 124. *J Neuropathol Exp Neurol.* 2010;69:553.
2. Vital-Durand D, Lecomte C, Cathebras P, Rousset H, Godeau P. Whipple disease. Clinical review of 52 cases. *Medicine (Baltimore).* 1997;76:170–84.
3. Louis ED, Lynch T, Kaufmann P, Fahn S, Odel J. Diagnostic guidelines in central nervous system Whipple's disease. *Ann Neurol.* 1996;40:561–8.
4. Gerard A, Sarrot-Reynauld F, Liozon E, Cathebras P, Besson G, Robin C, et al. Neurologic presentation of Whipple disease: report of 12 cases and review of the literature. *Medicine (Baltimore).* 2002;81:443–57.
5. Ghigo E, Capo C, Arouze M, Tung CH, Gorvel JP, Raoult D, et al. Survival of *Tropheryma whippelii*, the agent of Whipple's disease, requires phagosome acidification. *Infect Immun.* 2002;70:1501–6.
6. Boulou A, Rolain JM, Raoult D. Antibiotic susceptibility of *Tropheryma whippelii* in MRC5 cells. *Antimicrob Agents Chemother.* 2004;48:747–52.
7. Marth T, Schneider T. Whipple disease. *Curr Opin Gastroenterol.* 2008;24:141–8.
8. Elsborg L, Gravgard E, Jacobsen NO. Treatment of Whipple's disease with sulphamethoxazole–trimethoprim. *Acta Med Scand.* 1975;198:141–3.
9. Fenollar F, Puéchal X, Raoult D. Whipple's disease. *Medical progress. N Engl J Med.* 2007;356:55–66.
10. Freeman HJ. *Tropheryma whippelii* infection. *World J Gastroenterol.* 2009;15:2078–80.
11. Lagier JC, Fenollar F, Lepidi H, Raoult D. Failure and relapse after treatment with trimethoprim/sulfamethoxazole in classic Whipple's disease. *J Antimicrob Chemother.* 2010;65:2005–12.

R.O. Domínguez^{a,*}, C. Müller^a, I. Davolos^a, P. MacKeith^b, E. Arias^c, A.L. Taratuto^c

^a *Departamentos de Neurología y Medicina Interna del Hospital Sirio Libanés, Buenos Aires, Argentina*

^b *Brighton and Sussex Medical School, Londres, United Kingdom*

^c *Departamento de Neuropatología, FLENI, Buenos Aires, Argentina*

*Corresponding author.

E-mail address: dominguezraulo@yahoo.com.ar (R.O. Domínguez).

Hypertrophic olivary degeneration secondary to a Guillain–Mollaret triangle lesion[☆]

Degeneración hipertrófica de la oliva por lesión del triángulo de Guillain-Mollaret. Presentación de 2 casos

Dear Editor:

Hypertrophic olivary degeneration (HOD) is an atypical form of trans-synaptic degeneration representing the final result of an alteration in the neuronal connection of the dentatorubral–olivary pathway. This anatomical pathway was described by Guillain and Mollaret¹ in 1931. Clinical manifestations of HOD include involuntary movements by muscles dependent on cranial nerve nuclei in the brainstem, such as palatal myoclonus and ocular myoclonus.²

Its anatomical pathology is characterised by vacuolar degeneration of the cytoplasm associated with an increase in the number of astrocytes in the olivary body, which also entails an increase in that structure's volume.

The purpose of this article is to present the MRI findings and pathophysiological profile of the lesions in 2 cases of HOD; 1 case was ipsilateral and the other was contralateral to high brainstem lesions.

Case 1. Patient aged 43 with no relevant medical history who abruptly presented with dizziness, instability, and right hemifacial paraesthesia. Physical examination revealed tactile hypoaesthesia and hypalgesia on the right side of the face and the upper right limb, dysarthria, and left clumsy hand. Brain CT showed no abnormalities. Patient was diagnosed with vertebralbasilar stroke and scheduled for an MRI and neurological check-up.

The MRI taken 6 months later revealed a linear millimetric hypointense focus in the left dorsolateral region of the midbrain (upper cerebellar peduncle), corresponding to traces of haemosiderin secondary to a haemorrhagic infarct or cavernous angioma (Fig. 1).

T2-weighted images showed a hyperintense lesion with an increase in volume in the right anterolateral region of the medulla oblongata corresponding to the location of the inferior olivary nucleus (Fig. 2).

Case 2. Patient aged 22 years with no relevant history who visited the emergency department due to diplopia, instability, right-sided paraesthesia, and intense headache. The patient reported having experienced several episodes of spontaneously remitting right-sided paraesthesia a year before. Physical examination revealed conjugate gaze palsy and unstable gait with deviation to the left.

The MRI showed a lobulated lesion on the left dorsomedial pontine region with a hypointense peripheral halo in the T2-weighted sequence and a heterogeneous, predominantly hyperintense, central reticulated core (Fig. 3) suggestive of a cavernoma.

Inferior to this structure, we identified a hyperintense focus and asymmetry in the anterior rim of the medulla due to an increase in volume in the typical location of the left inferior olivary nucleus (Fig. 4).

[☆] Please cite this article as: Sánchez Hernández J, et al. Degeneración hipertrófica de la oliva por lesión del triángulo de Guillain-Mollaret. Presentación de 2 casos. *Neurología.* 2013;28:59–61.