

References

1. Koller S, Kränke B. Nicolau syndrome following subcutaneous glatiramer-acetate injection. *J Am Acad Dermatol*. 2011;64:16–7.
2. Kim KK. Nicolau syndrome in patient following diclofenac administration: a case report. *Ann Dermatol*. 2011;23:501–3.
3. Gaudes C, Regnier S, Aractingi S, Heinzl O. Livedo-like dermatitis (Nicolau's syndrome) after injection of Copolymer-1 (Glatiramer acetate). *Rev Neurol (Paris)*. 2003;159:571–3.
4. Corazza M, Capozzi O, Virgili A. Five cases of livedo-like dermatitis (Nicolau's syndrome) due to bismuth salts and various other non-steroidal anti-inflammatory drugs. *J Eur Acad Dermatol Venereol*. 2001;15:585–8.
5. Kienast AK, Mentze D, Hoeger PH. Nicolau's syndrome induced by intramuscular vaccinations in children: report of seven patients and review of the literature. *Clin Exp Dermatol*. 2008;33:555–8.
6. Nagore E, Torrelo A, González-Mediero I, Zambrano A. Livedoid skin necrosis (Nicolau syndrome) due to triple vaccine (DTP) injection. *Br J Dermatol*. 1997;137:1030–1.
7. Wysong A, Venkatesan P. An approach to the patient with retiform purpura. *Dermatol Ther*. 2011;24:151–72.
8. Martínez-Morán C, Espinosa-Lara P, Nájera L, Romero-Maté A, Córdoba S, Hernández-Núñez A, et al. Embolia cutis medicamentosa (síndrome de Nicolau) tras inyección de acetato de glatirámico. *Actas Dermosifiliogr*. 2011;102:742–4.
9. Ruffieux P, Salomon D, Saurat JH. Livedo-like dermatitis (Nicolau's syndrome): a review of three cases. *Dermatology*. 1996;193:368–71.
10. Marangi GF, Gigliofiorito P, Toto V, Langella M, Pallara T, Persichetti P. Three cases of embolia cutis medicamentosa (Nicolau's syndrome). *J Dermatol*. 2010;37:488–92.

A. Pulido Pérez^{a,*}, V. Parra Blanco^b, R. Suárez Fernández^a

^a *Servicio de Dermatología, Hospital General Universitario Gregorio Marañón, Madrid, Spain*

^b *Servicio de Anatomía Patológica, Hospital General Universitario Gregorio Marañón, Madrid, Spain*

* Corresponding author.

E-mail address: ana.pulido@madrimasd.net
(A. Pulido Pérez).

Potomania and osmotic imbalance: Permanent cortical visual impairment due to extrapontine myelinolysis[☆]

Potomanía y desequilibrio osmótico: Ceguera cortical definitiva por mielinólisis extrapontina

Dear Editor:

Potomania or psychogenic polydipsia is characterised by excessive drinking of liquids, such as water (polydipsia) or alcohol (dipsomania). Excessive drinking may lead to hyponatraemia (HNa) even in patients presenting no organic, metabolic, or toxic diseases.^{1,2} Central pontine myelinolysis (PM) and extrapontine myelinolysis (EPM) have numerous manifestations and affect different areas (generally symmetrical areas). Myelinolysis is mainly caused by hyponatraemia and the means used to correct it; to a lesser extent, it may be caused by association with hypokalaemia. We present the case of a woman aged 72 who was admitted to the hospital in a coma 3 hours after its onset. Coma was preceded by disorientation and progressive stupor developing in the preceding 6 hours. The patient presented decreased muscle tone in all limbs, deep tendon areflexia, lack of Babinski sign, and bilateral plantar reflex due to pain. The oculocephalic, corneal, and photomotor reflexes were present. The Glasgow coma scale score was 6/15. Studies showed no renal, cardiac, or hormonal disorders. The

patient had a history of non-alcoholic potomania in the preceding 6 months (water intake of 4 to 6 litres daily). She was in psychotherapy and undergoing treatment with quetiapine (50 mg/day). This treatment was beneficial for 5 months, after which potomania appeared again. Blood tests revealed hyponatraemia of 111 mM/L and hypokalaemia of 2.2 mM/L. The rest of the results were anodyne. The ECG showed sinus rhythm, a heart rate of 85 beats per minute, ST segment deviation, and flat T wave. The computed tomography (CT) performed in the first 12 hours yielded normal results. Natraemia was corrected at a rate of 9 mM/L/day; kalaemia was corrected by administering 5 mM/h of potassium chloride intravenously. The patient awoke 48 hours later with a confusional state, flexor withdrawal reflex in all 4 limbs, and purposeless hand movements. The Glasgow coma scale score was 12/15. At this time, natraemia was 127 mM/L and kalaemia, 3.7 mM/L. Doctors suspected bilateral vision loss since stimulating visual fields with rapid, nearby movements elicited no blink reflex. The brain MRI carried out on the third day of hospitalisation (Fig. 1) showed occipital lesions. There were no changes in the pons or the cerebral/cerebellar hemispheres. Blood test showed normal results on the 10th day after admission. Another brain MRI showed similar changes and the angiography of the neck vessels and intracranial arteries yielded normal results. In the fourth week of hospitalisation, the patient presented no cognitive decline, but cortical blindness had not abated. She was lucid and aware of her visual impairment. There are 2 main causes of hyponatraemia: net increase in water (total sodium remains normal), and sodium loss. Although the mechanisms often coexist, one is frequently predominant. In our case, psychogenic polydipsia triggered dilutional hyponatraemia; researchers found no primary diseases inducing potomania or hyponatraemia. PM is suspected when the patient presents severe manifestations (disorientation, stupor and coma, tetraparesis) or a history of malnutrition, alcoholism, or polydipsia.

[☆] Please cite this article as: Domínguez RO, Laguarde N, Pinkala E, González SE. Potomanía y desequilibrio osmótico: Ceguera cortical definitiva por mielinólisis extrapontina. *Neurología*. 2013;28:449–450.

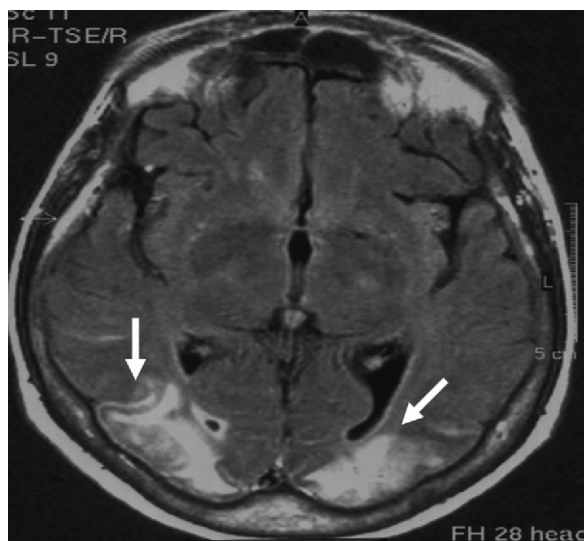


Figure 1 FLAIR Brain MRI. Axial slice showing bilateral extensive hyperintense cortical and subcortical lesions (white arrows) in both occipital lobes.

Myelinolysis is due to oligodendrocyte death, which is favoured by the predominance of proapoptotic factors.³ EPM presents similar pathological changes characterised by predominantly extrapyramidal manifestations, such as parkinsonism, dystonia, dyskinesias, and spasmodic dysphonia. According to a recent publication, EPM lesions are symmetrically arranged and located in the basal ganglia.⁴ We did not find any reports of osmotic myelinolysis with definitive amaurosis in the posterior half of the brain. The literature includes only one case of blindness due to optic nerve atrophy and one other case of transient vision loss due to osmotic changes resulting from an altered ammonium cycle.^{5,6} In cases of dipsomania, excessive beer intake may trigger hyponatraemia,⁷ which is sometimes accompanied by PM⁸; likewise, alcohol withdrawal syndrome may cause PM and EPM without associated hyponatraemia.⁹ In cases of asymptomatic normovolaemic hyponatraemia, guidelines suggest that correction should not exceed 10 to 12 mM/L per day.¹⁰ The presence of PM and EPM associated with hyponatraemia is a formidable cause of death and disability. This letter points out a new sequela of EPM, stressing that

potomania is a risk factor that can be modified to prevent the consequences described here.

References

1. Cronin RE. Psychogenic polydipsia with hyponatremia: report of eleven cases. *Am J Kidney Dis.* 1987;9:410–6.
2. Marco Martínez J. Hyponatremia: classification and differential diagnosis. *Endocrinol Nutr.* 2010;57 Suppl. 2:2–9.
3. DeLuca GC, Nagy Zs Esiri MM, Davey P. Evidence for a role for apoptosis in central pontine myelinolysis. *Acta Neuropathol.* 2002;103:590–8.
4. de Souza A, Desai PK. More often striatal myelinolysis than pontine? A consecutive series of patients with osmotic demyelination syndrome. *Neurol Res.* 2012. PMID: 22450756 [PubMed].
5. Silva FA, Rueda-Clausen CF, Ramírez F. Extrapontine osmotic myelinolysis. *Biomédica.* 2005;25:167–9.
6. Langer JE, Wilson WG, Raghavan P, Rust RS, Goodkin HP. Extrapontine myelinolysis resulting in transient cortical blindness. *Pediatr Neurol.* 2010;42:154–6.
7. Milisenda JC, Coloma E, Grau JM. Beer potomania. An uncommon cause of severe hyponatremia. *Med Clin (Barc).* 2011. PMID: 21940012 [PubMed].
8. Campbell MC. Hyponatremia and central pontine myelinolysis as a result of beer potomania: a case report. *Prim Care Companion. J Clin Psychiatry.* 2010;12. PMID: 21085565 [PubMed].
9. An JY, Park SK, Han SR, Song IU. Central pontine and extrapontine myelinolysis that developed during alcohol withdrawal, without hyponatremia, in a chronic alcoholic. *Intern Med.* 2010;49:615–8.
10. Verbalis JG, Goldsmith SR, Greenberg A, Schrier RW, Sterns RH. Hyponatremia treatment guidelines 2007: expert panel recommendations. *Am J Med.* 2007;120:S1–21.

R.O. Domínguez^{a,*}, N. Laguarde^b, E. Pinkala^b,
S.E. González^a

^a *Departamento de Neurología, Hospital Sirio Libanés, Buenos Aires, Argentina*

^b *Departamento de Medicina Interna, Hospital Sirio Libanés, Buenos Aires, Argentina*

* Corresponding author.

E-mail address: dominguezraulo@yahoo.com.ar
(R.O. Domínguez).