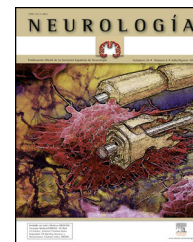




NEUROLOGÍA

www.elsevier.es/neurologia



LETTERS TO THE EDITOR

Peripheral polyneuropathy and Churg–Strauss syndrome[☆]

Polineuropatía periférica y síndrome de Churg–Strauss

Dear Editor:

Churg–Strauss syndrome (CSS) is a systemic disease characterised by asthma, pulmonary infiltrates, hypereosinophilia, and systemic vasculitis. Eosinophilic vasculitis can involve many organs, including the lungs, heart, skin, gastrointestinal tract, and nervous system, principally the peripheral nervous system (PNS).¹ We present 3 cases in which CSS was diagnosed due to PNS involvement, thus highlighting the severity of this disease and the need for early diagnosis and treatment.

Patient 1 was a 72-year-old man with personal history of nasal polyps. He had symptoms of motor and sensory peripheral polyneuropathy, a 5-month history of toxic syndrome, and ataxic gait for which he needed bilateral support. CSS was diagnosed based on findings of eosinophilia, p-ANCA positivity, diffuse pulmonary infiltrates, and EMG showing mixed axonal polyneuropathy in a moderate to severe stage. Infectious and/or neoplastic processes had previously been ruled out. He was started on remission induction treatment with prednisone dosed at 1 mg/kg/day and intravenous bolus cyclophosphamide as well as symptomatic treatment. After a few days, eosinophilia disappeared and respiratory symptoms improved progressively. Neurological symptoms only showed discrete improvement.

Patient 2 was a 45-year-old man with personal history of arterial hypertension and asthma. He showed symptoms of axonal sensorimotor polyneuropathy which had been developing over 3 months, eosinophilia, pansinusitis, pulmonary infiltrates, p-ANCA positive test results, and skin lesions. Sural nerve biopsy showed signs compatible with vasculitis. After being diagnosed with CSS, he started treatment with prednisone; when neurological involvement progressed, intravenous bolus of cyclophosphamide was

added. Once respiratory symptoms had resolved and neurological symptoms had also resolved partially, the patient started maintenance treatment with azathioprine. During treatment, he suffered 2 vertebral fractures due to secondary osteoporosis and showed reactivation of hepatitis B and iatrogenic Cushing syndrome. He is currently treated with azathioprine; dysaesthesia and ataxic gait persist.

Patient 3 was a 22-year-old man with personal history of asthma and rhinitis. He showed symptoms of mixed axonal polyneuropathy over a 2-month period with eosinophilia, positive ANCA test, and interstitial pneumonitis. The patient started induction treatment with decreasing doses of corticosteroids and 5 doses of cyclophosphamide. Clinical response was excellent. After that, he was treated with azathioprine as maintenance treatment. He is currently asymptomatic.

The incidence of CSS is 2.4 cases/million person-years in the general population; among asthma patients, the rate is 12.5 to 20 times higher, reaching up to 64 cases/million person-year. The syndrome is more frequent in men. It can appear in patients with a history of allergy and atopy, and it may develop over 30 years before any systemic manifestations are observed. It manifests in 3 stages and asthma seems to present years before the other symptoms do.

At the systemic level, it mainly affects the lungs, followed by the skin and the PNS (80%).^{2,3} When the PNS is affected, patients experience paraesthesia and dysaesthesia predominantly on the soles of the feet, hiccups, loss of strength, or patellar tendon and Achilles tendon areflexia. Involvement mainly manifests as mononeuritis multiplex or distal symmetric sensorimotor axonal polyneuropathy.^{4,5}

Treatment must be aggressive and immediate, using high-dose corticosteroids and/or cytostatic drugs.^{6,7} Initial treatment uses oral corticosteroids (1 mg/kg/day) to induce remission as soon as possible. The dose is then progressively decreased to continue with maintenance treatment. In cases of complications or poor response to these drugs, intravenous cyclophosphamide pulses, followed by azathioprine, are to be used. Cyclophosphamide would only be indicated as a first-line treatment if factors are present that indicate poor prognosis (proteinuria >1 g/day, creatinine >1.58 mg/dL, PNS involvement). Response to treatment with intravenous immunoglobulins^{5,8} or rituximab⁹ has been described in some cases.

By presenting these cases, we aim to highlight the need for early diagnosis and intensive treatment, considering the high degree of impairment caused when CSS is accompanied by PNS involvement.

[☆] Please cite this article as: Bonaventura Ibars I, de Francisco Moure J, Pineda Barrero S, Rodríguez Carballeira M, Saura Salvado J. Polineuropatía periférica y síndrome de Churg–Strauss. *Neurología*. 2014;29:249–250.

References

- Alfaro TM, Duarte C, Monteiro R, Simão A, Calretas S, Nascimento Costa JM. Churg–Strauss syndrome: case series. *Rev Port Pneumol.* 2012;18:86–92.
- Zhang W, Zhou G, Shi Q, Zhang X, Zeng XF, Zhang FC. Clinical analysis of nervous system involvement in ANCA-associated systemic vasculitides. *Clin Exp Rheumatol.* 2009;27 1 Suppl. 52:S65–9.
- Henes J, Horger M, Kanz L, Kötter I. 56-year-old patient with leg paresis, pulmonary infiltrates, and eosinophilia – Case 08/2009. *Dtsch Med Wochenschr.* 2009;134:2228.
- Pardal-Fernandez JM, Godes-Medrano B, Sánchez-Ayaso P, Rodríguez-Vázquez M, Iñiguez-De Onzoño L. Multiple mononeuritis in a patient with Churg–Strauss syndrome Pseudo conduction block as an early electroclinical expression. *Rev Neurol.* 2011;53:22–6 [Spanish].
- Nakamura M, Yabe I, Yaguchi H, Kishimoto R, Mito Y, Fujiki N, et al. Clinical characterization and successful treatment of 6 patients with Churg–Strauss syndrome-associated neuropathy. *Clin Neurol Neurosurg.* 2009;111:683–7.
- Kararizou E, Davaki P, Spengos K, Karandreas N, Dimitracopoulos A, Vassilopoulos D. Churg–Strauss syndrome complicated by neuropathy: a clinicopathological study of nine cases. *Clin Neuropathol.* 2011;30:11–7.
- Wolf J, Bergner R, Mutallib S, Buggle F, Grau AJ. Neurologic complications of Churg–Strauss syndrome – a prospective monocentric study. *Eur J Neurol.* 2010;17:582–8.
- Asashima H, Inokuma S, Yamada H. Step by step improvement of peripheral polyneuropathy associated with Churg–Strauss syndrome by six courses of high-dose intravenous immunoglobulin therapy. *Allergol Int.* 2012;61:503–5.
- Vaglio A, Moosig F, Zwerina J. Churg–Strauss syndrome: update on pathophysiology and treatment. *Curr Opin Rheumatol.* 2012;24:24–30.

I. Bonaventura Ibars^{a,*}, J. de Francisco Moure^a, S. Pineda Barrero^b, M. Rodríguez Carballeira^c, J. Saura Salvado^d

^a Servicio de Neurología, Hospital Universitario Mútua de Terrassa, Terrasa, Barcelona, Spain

^b Medicina de Familia y Comunitaria, Hospital Universitario Mútua de Terrassa, Terrasa, Barcelona, Spain

^c Servicio de Medicina Interna, Hospital Universitario Mútua de Terrassa, Terrasa, Barcelona, Spain

^d Servicio de Neurología, Hospital Universitari Sant Joan de Déu, Manresa, Barcelona, Spain

* Corresponding author.

E-mail address: 17002ibi@gmail.com

(I. Bonaventura Ibars).

Rhombencephalitis due to *Listeria monocytogenes*: A case study[☆]

A propósito de un caso: rombencefalitis por *Listeria monocitogenes*

Dear Editor:

Listeria monocytogenes normally affects multiple organs. In exceptional cases, it may involve the brainstem in a condition called rhombencephalitis. Rhombencephalitis due to *Listeria* is a rare disease that strikes previously healthy individuals.¹ The course of the disease is biphasic²; the patient initially presents non-specific virus-like symptoms, after which neurological symptoms occur (initially, progressive brainstem signs and cranial nerve deficits followed by obtundation and seizures).

Diagnosis is not easy. In up to 60% of all cases, CT scan results are normal but pontine involvement is typical in MRI scans. Blood culture results may be negative³ and lumbar puncture may yield a low white blood cell count and normal protein and glucose levels in CSF.

Differential diagnosis is performed to rule out infection (TB, fungus, HSV), inflammatory processes, lymphoma, or paraneoplastic syndromes. Treatment consists of intravenous ampicillin⁴ dosed at 150 to 300 mg/kg/day over at

least 6 weeks. Its prognosis depends on how early treatment is started. Mortality is 100% in untreated cases and 30% in treated ones. Neurological sequelae persist in 61% of the total patients.²

Our patient was a 50-year-old man with no relevant medical history who came to the emergency department with symptoms of dizziness without spinning sensation and right facial paraesthesia. The only finding from the examination was right facial hypoaesthesia. As the head CT revealed no anomalies, the patient was discharged.

Five days later, he returned to the emergency room with diplopia and low-grade fever. In addition to sensory alterations, the examination found that he could not walk in tandem gait. Doctors performed a laboratory analysis, chest radiography, and electroencephalography; all yielded normal results. CSF analysis found 10 white cells (75% neutrophils), a glucose level of 58 mg/dL, and protein level of 51.8 mg/dL. Given a suspected diagnosis of acute meningoencephalitis, the patient was admitted and initially treated with antibiotics and acyclovir. He remained stable during hospitalisation with no infectious signs and no changes in the examination. To complete the work-up, we performed serology tests (HIV, *Coxiella*, *Bartonella*, hepatitis B, cytomegalovirus, herpesvirus 1, 2 and 6, Epstein-Barr virus, and *Leptospira*); autoimmunity test, blood cultures, and CSF cultures; all results were negative. A second cerebrospinal fluid examination found 36 white cells (83% lymphocytes), glucose 58 mg/dL, proteins 57.7 mg/dL, and ADA 5.9 U/L. Brain MRI (Fig. 1) showed inflammatory lesions in the cerebellar peduncles.

Based on negative results from cultures and the suspicion of a non-infectious inflammatory process, doctors suspended acyclovir and antibiotics. On the fifth day the patient's

[☆] Please cite this article as: Gómez Eguílaz M, López Pérez MÁ, Blasco Martínez O, García De Carlos MS. A propósito de un caso: rombencefalitis por *Listeria monocitogenes*. *Neurología.* 2014;29:250–251.