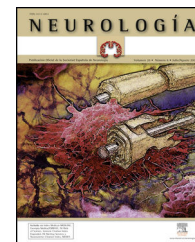




ELSEVIER  
DOYMA

# NEUROLOGÍA

www.elsevier.es/neurologia



## REVIEW ARTICLE

### Biomarkers: a new approach to behavioural variant frontotemporal dementia<sup>☆</sup>

M. Fernández-Matarrubia\*, J.A. Matías-Guiu, T. Moreno-Ramos, J. Matías-Guiu

Servicio de Neurología, Hospital Clínico San Carlos, Madrid, Spain

Received 27 February 2013; accepted 16 March 2013

Available online 3 December 2014

#### KEYWORDS

Behavioural variant frontotemporal dementia;  
Frontotemporal lobar degeneration;  
Biomarker;  
TDP-43;  
Tau;  
Genetics

#### Abstract

**Introduction:** Lobar frontotemporal degeneration (FTLD) encompasses a group of molecular disease defined by the deposition of an abnormal protein in the central nervous system. Behavioural variant frontotemporal dementia (bvFTD) is the most frequent clinical presentation of FTLD. The past two decades of research have contributed to a better understanding of this entity, which may be the first manifestation in many different neurodegenerative disorders. **Development:** We reviewed correlations between clinical, pathological, and genetic findings and the main disease biomarkers of FTLD, with particular interest in bvFTD. Anatomical pathology findings in FTLD are heterogeneous and the syndrome is not associated with any one specific histopathological type. Promising available biomarkers include structural and functional neuroimaging techniques and biochemical and genetic biomarkers. Disease-modifying drugs designed for specific molecular targets that are implicated in FTLD pathogenesis are being developed.

**Conclusions:** BvFTD is a frequent cause of dementia. Of all the clinical variants of FTLD, behavioural variant is the one in which establishing a correlation between clinical and pathological signs is the most problematic. A biomarker evaluation may help predict the underlying pathology; this approach, in conjunction with the development of disease-modifying drugs, offers new therapeutic possibilities.

© 2013 Sociedad Española de Neurología. Published by Elsevier España, S.L.U. All rights reserved.

#### PALABRAS CLAVE

Demencia frontotemporal variante conductual;  
Degeneración lobar frontotemporal;

**Demencia frontotemporal variante conductual: biomarcadores, una aproximación a la enfermedad**

#### Resumen

**Introducción:** Las degeneraciones lobares frontotemporales (DLFT) son un grupo de patologías moleculares que se definen en función de la proteína acumulada en el sistema nervioso central. La demencia frontotemporal variante conductual (DFT vc) es el síndrome clínico de

<sup>☆</sup> Please cite this article as: Fernández-Matarrubia M, Matías-Guiu JA, Moreno-Ramos T, Matías-Guiu J. Demencia frontotemporal variante conductual: biomarcadores, una aproximación a la enfermedad. Neurología. 2015;30:50–61.

\* Corresponding author.

E-mail addresses: [martafmatarrubia@gmail.com](mailto:martafmatarrubia@gmail.com), [marta\\_fm1@hotmail.com](mailto:marta_fm1@hotmail.com) (M. Fernández-Matarrubia).

Biomarcador;  
TDP-43;  
Tau;  
Genética

presentación más frecuente. Los avances realizados en los últimos años han contribuido a un mayor conocimiento de esta entidad, que puede ser el modo de presentación de diferentes enfermedades neurodegenerativas.

**Desarrollo:** Se revisa la correlación entre clínica, patología y genética de las DLFT, en especial de la DFT vc, así como los principales biomarcadores de la enfermedad. La anatomía patológica de la DFT vc es muy variada, sin mostrar asociación significativa con ningún subtipo histopatológico concreto. Entre los biomarcadores disponibles, destacan la neuroimagen anatómica y funcional, los biomarcadores analíticos y la genética. Se están diseñando fármacos dirigidos contra dianas moleculares concretas implicadas en la patogenia de las DLFT.

**Conclusiones:** La DFT vc es una causa frecuente de demencia. De entre todas las variantes clínicas de las DLFT, es en la que resulta más difícil establecer una relación clínico-patológica. El uso de biomarcadores puede ayudar a predecir la anatomía patológica subyacente, lo que junto al desarrollo de fármacos ligando-específicos ofrece nuevas posibilidades terapéuticas.

© 2013 Sociedad Española de Neurología. Publicado por Elsevier España, S.L.U. Todos los derechos reservados.

## Introduction

The term frontotemporal lobar degeneration (FTLD) designates a pathological concept that includes a group of molecular diseases that are classified according to the protein that accumulates in the central nervous system. In 2007, Cairns et al.<sup>1</sup> established 4 main subtypes according to the protein deposits: tauopathies (FTLD-tau), ubiquitinopathies (FTLD-U), dementia without specific histopathological changes, and neuronal intermediate filament inclusion disease. Since then, following new breakthroughs in pathology and molecular biology, this classification system has been modified. FTLD cases are now classified into 3 main subtypes according to pathology: FTLD associated with tau protein (FTLD-tau), FTLD associated with the TAR DNA-binding protein 43 (FTLD-TDP), and FTLD associated with the fused-in sarcoma protein (FTLD-FUS). Only a very small percentage of cases will not fit any of these subtypes (FTLD-other).<sup>2</sup> Each of these main pathological groups can be subdivided into different entities or variants according to the distribution and morphology of protein inclusions and the histological characteristics specific to the case (Table 1). These groups give rise to 6 well-defined syndromes: the 3 clinical variants of frontotemporal dementia or FTD (behavioural variant frontotemporal dementia [bv-FTD], progressive nonfluent aphasia [PNFA], semantic dementia [SD]); frontotemporal dementia associated with motor neuron disease (FTD-MND); progressive supranuclear palsy syndrome (PSPS); and corticobasal syndrome (CBS).

A small percentage of cases with clinical features suggesting FTD actually have Alzheimer disease (AD).<sup>3</sup> This finding is more frequent in cases of logopenic primary progressive aphasia (PPA),<sup>4</sup> but it has also been described in some cases of SD (10%)<sup>5</sup> and bv-FTD (5%-7%).<sup>5-7</sup> Cases of AD with an antemortem diagnosis of bv-FTD are referred to as frontal-variant AD.<sup>8</sup>

The purpose of this study is to revise the clinical-pathological and biomolecular correlations in FTD subtypes, especially bv-FTD, as well as the diagnostic accuracy of biomarkers used to hypothesise which disease was responsible for clinical symptoms.

## Clinical-pathological and biomolecular correlations in frontotemporal lobar degeneration

FTLDs have classically been regarded as a heterogeneous group of neurodegenerative diseases and researchers have found it extraordinarily difficult to establish links between clinical presentation and the underlying pathological process. Doctors also believed it was not possible to deduce the type of clinical manifestation based on the pathological diagnosis. Advances in neuropathology, biochemistry, molecular biology, and genetics now let us establish clinical, histological, biomolecular, and genetic correlations, in addition to links between clinical and pathological findings.

In 2011, Josephs et al.<sup>9</sup> published a review of several clinical-pathological studies<sup>10-17</sup> performed in the preceding decade in 6 hospitals in the United States, Canada, the UK, and Australia, including a total of 544 cases of FTLD. They observed that bv-FTD showed similar percentages of underlying FTLD-tau and FTLD-TDP. Almost all cases of PSPS and CBS presented FTLD-tau, whereas 100% of the cases of FTD-MND displayed FTLD-TDP. FTLD-TDP was present in 83% of the patients with SD, whereas PNFA was fundamentally associated with FTLD-tau (70%). Examining by specific groups (FTLD-TDP and FTLD-tau), these researchers found significant associations between clinical phenotype and histopathological subtype, except for PNFA and the FTLD-tau subtype, for which associations were not statistically significant. Patients with bv-FTD and tauopathy were associated with Pick disease (PiD) in 70% of all cases. Those with TDP histopathology demonstrated an association with subtype 1 in the Mackenzie et al. classification.<sup>18</sup> Nevertheless, the association between bv-FTD and the histopathological subtype was not robust (Fig. 1).

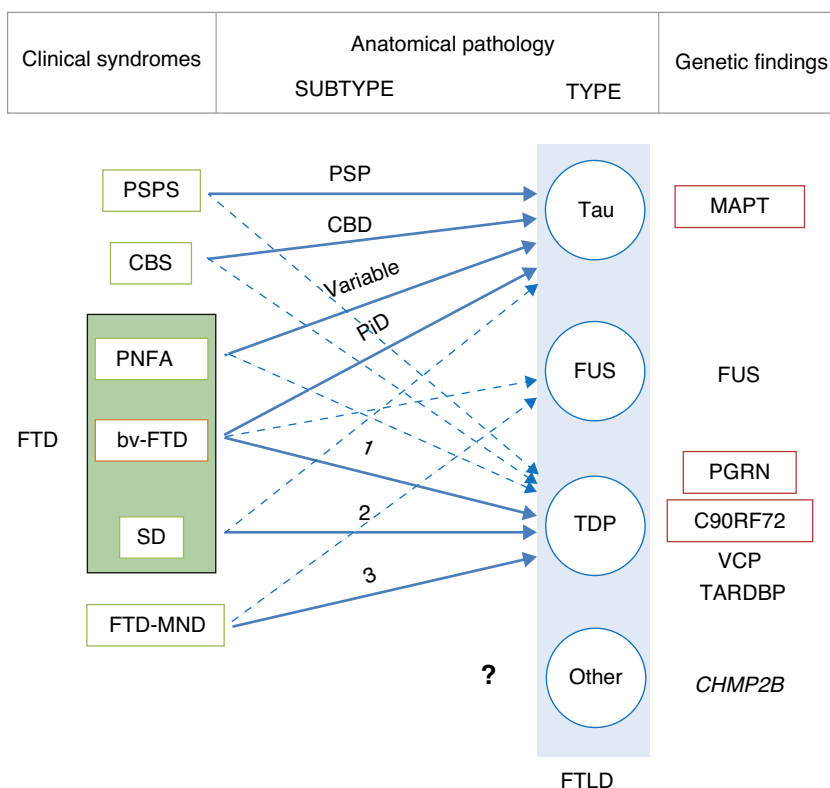
In some cases of bv-FTD, doctors may find clinical features that point towards a specific histopathological subtype.<sup>19</sup> One clinical subtype is characterised by changes in behaviour and personality, especially hypersexuality, hyperphagia, and stereotyped or obsessive behaviour. This subtype is strongly associated with atypical FTLD with immunoreactivity to ubiquitin only (aFTLD-U).<sup>20,21</sup> These

**Table 1** Histopathological and biomolecular classification of types of frontotemporal lobar degeneration

Histopathological type and subtype	Protein	Histopathology characteristics
<b>FTLD-tau</b>		
<i>Pick disease</i>	tau 3R	Rounded argyrophilic cytoplasmic masses (Pick bodies) Non-pyramidal cells in dentate gyrus and CA1 area of the hippocampus Pyramidal neurons of the frontal and temporal lobes (layers II and VI)
<i>Corticobasal degeneration</i>	tau 4R	Rounded tangles in neurons and glia, predominantly in the cortex Ring-shaped tau deposits in astrocytes (glial plaque) Deposits in oligodendrocytes (coiled bodies)
<i>Progressive supranuclear palsy</i>	tau 4R	Rounded tangles in neurons and glia, predominantly in the cortex Tufted astrocytes
<i>Dementia with argyrophilic grains</i>	tau 4R	Deposits in dendritic spines Deposits in oligodendrocytes (coiled bodies)
<i>Multisystemic tauopathy</i>	tau 4R	Neocortex (frontal, temporal and parietal lobes) Basal ganglia and brainstem
<i>Tangle-predominant dementia</i>	tau 3R/4R	Cortical neurofibrillary tangles Absence of amyloid plaques
<i>FTLD associated with MAPT gene mutation</i>	tau 3R, 4R or 3R/4R	Pronounced heterogeneity
<b>FTLD-U</b>		
<i>FTLD-TDP</i>		
Type 1	TDP-43	Abundant NCI and dystrophic neurites (DN) Variable NII (cat's eyes)
Type 2	TDP-43	Abundant DNs Few or no NCIs or NIIs
Type 3	TDP-43	Numerous NCIs Few NIIs/DNs
Type 4	TDP-43	Numerous NCIs Few NCIs and DNs
<i>FTLD-FUS</i>		
Neuronal intermediate filament inclusion disease	FUS	NCIs positive for FUS, intermediate filaments, and ubiquitin Visible in H&E stain
Basophilic inclusion body disease	FUS	NCIs positive for FUS and ubiquitin and negative for TDP-43, tau, and intermediate filaments Basophils in H&E stain
Atypical FTLD with ubiquitin-positive inclusions	FUS	NCIs positive for FUS and ubiquitin and negative for TDP-43, tau, and intermediate filaments
<b>FTLD-other</b>		
<i>FTLD without inclusions</i>	?	Frontotemporal gliosis and neuronal loss No evidence of inclusions
<i>FTLD immunoreactive to proteins in the ubiquitin-proteasome pathway</i>	Ubi	Inclusions positive for ubiquitin or p62 Negative for tau, $\alpha$ -synuclein, $\alpha$ -internexin, TDP-43, and FUS
<b>No FTLD</b>		
AD	tau 3R and 4R $\beta$ -amyloid	Neuritic plaques positive for $\beta$ -amyloid Neurofibrillary tangles positive for tau 3R and 4R

FTLD-TDP subtypes 1-4 are designated according to Mackenzie's classification.

AD: Alzheimer disease; FTLD-FUS: frontotemporal lobar degeneration associated with fused-in sarcoma protein; FTLD-tau: frontotemporal lobar degeneration with tau inclusions; FTLD-TDP: frontotemporal lobar degeneration associated with TAR DNA-binding protein 43; aFTLD-U: atypical frontotemporal lobar degeneration with ubiquitin-immunoreactive inclusions; NCI: neuronal cytoplasmic inclusions; NII: neuronal intranuclear inclusions; Ubi: ubiquitin.



**Figure 1** Clinical, molecular, and genetic correlations in frontotemporal lobar degeneration. Arrows indicate the links between clinical syndromes and underlying disease, while continuous lines show the most robust associations. The most frequent histopathological subtype is listed for each syndrome. FTD: frontotemporal dementia; FTLT: frontotemporal lobar degeneration; PSPS: progressive supranuclear palsy syndrome; CBS: corticobasal syndrome; PNFA: progressive nonfluent aphasia; bv-FTD: behavioural variant frontotemporal dementia; SD: semantic dementia; FTD-MND: frontotemporal dementia associated with motor neuron disease; PSP: progressive supranuclear palsy; CBD: corticobasal degeneration; PiD: Pick disease; MAPT: microtubule associated protein tau; FUS: fused-in sarcoma protein; PGRN: progranulin; VCP: valosin containing protein; TARDBP: TAR DNA-binding protein 43; CHMP2B: charged multivesicular body protein 2B. FTLT-DTP subtypes 1-3 are designated according to Mackenzie's classification.

cases also show very early onset (mean age of about 40 years), and they are typified by pronounced striatal atrophy.<sup>22,23</sup> On the other hand, the coexistence of psychotic symptoms or signs of motor neuron disease (MND) points to FTLT-DTP type 3 pathology,<sup>24</sup> whereas apathy as the dominant trait is indicative of FTLT-DTP type 1 associated with *PGRN* mutations.<sup>25,26</sup> The coexistence of marked disinhibition and alteration of the semantic axis of language suggests tau pathology associated with mutation of the microtubule-associated protein tau (MAPT) gene.<sup>14,26,27</sup> The presence of vertical supranuclear gaze palsy is associated with tau pathology, and specifically with corticobasal degeneration; to a lesser extent, it is associated with progressive supranuclear palsy (PSP).<sup>28</sup>

Although the clinical-pathological correlations for the FTLT-FUS subtype have undergone less study,<sup>29–36</sup> it seems there is also an association between clinical phenotype and FTLT-FUS. Neuronal intermediate filament inclusion disease has been linked to 3 syndromes; the most frequent is bv-FTD, followed by FTD-MND and CBS/primary lateral sclerosis. Basophilic inclusion body disease is associated with bv-FTD, FTD-MND, motor neuron diseases, and juvenile amyotrophic lateral sclerosis (JALS). There is a

strong association between aFTLT-U and bv-FTD. There are no clinical-pathological studies on FTLT without inclusions, or on FTLT with cytoplasmic inclusions that are immunoreactive to proteins in the ubiquitin-proteasome pathway and negative for TDP-43 (FTLT-UPS).

Although one specific syndrome tends to be dominant in the first 4 years, it is common for different clinical syndromes in FTD to overlap as the disease progresses.<sup>37</sup> Kertesz et al.<sup>38</sup> prospectively studied 262 patients with clinical criteria of FTD. During follow-up, they documented the appearance of second and sometimes even third clinical syndromes. Patients with bv-FTD developed PNFA in 50% of the cases, CBS/PSPS in 22.5% of the cases, and SD in about 16% of the cases. Slightly more than 50% of the PNFA cases developed bv-FTD and a third developed CBS/PSPS. The rest of the PNFA cases did not exhibit any other syndromes. Three-quarters of the patients with SD developed bv-FTD and the rest did not progress to exhibit other clinical syndromes. Cases with CBS/PSPS were likely to develop bv-FTD (50%) or PNFA (50%).

Since the same patient may manifest different clinical syndromes as the disease progresses, it is possible to state that the same histopathological subtype may elicit different

types of clinical disease due to unknown aetiological or neuropathological mechanisms.

### Clinical-pathological correlations in the genetic variants of frontotemporal lobar degeneration

Although most FTLD cases are sporadic, a small percentage of them are associated with specific genetic mutations. Seven genes are currently known to be involved in cases of familial FTLD: *MAPT*, the progranulin gene (*PGRN*), *C9ORF72*, valosin containing protein-1 (*VCP-1*), charged multivesicular body protein 2B (*CHMP2B*), TAR DNA-binding protein 43 (*TARDBP*) and fused-in sarcoma (*FUS*). Mutations in the *MAPT*, *PGRN*, and *C9ORF72* are responsible for most FTD cases with an autosomal dominant inheritance pattern.

*MAPT* mutations<sup>39</sup> are typically associated with FTLD-tau pathology and do not display a specific histological pattern;<sup>40</sup> histological presentations may include PiD, PSP, and corticobasal degeneration (CBD).<sup>41</sup> Patients with *MAPT* gene mutations usually present a bv-FTD phenotype, which is occasionally associated with extrapyramidal symptoms.<sup>27</sup> This group characteristically presents pronounced symmetrical atrophy of the anterior medial temporal and orbitofrontal regions,<sup>42,43</sup> and it is therefore quite common for the disease to manifest as SD with signs of bv-FTD (or bv-FTD with changes in the semantic processing of language). Disinhibition is a particularly common feature among these patients.<sup>23,26,27</sup>

Familial cases associated with *PGRN* mutations present a typical neuropathology pattern with marked atrophy at the level of the frontal lobe, caudate nucleus, substantia nigra, and medial area of the thalamus. Unlike *MAPT* mutations, which are associated with tauopathy, *PGRN* mutations are associated with deposits of TDP-43, especially in type 1 FTLD-TDP according to Mackenzie's classification.<sup>18</sup> Neuronal intranuclear inclusions with a 'cat's eye' or 'lentiform' appearance are the most striking histological finding.<sup>44–46</sup>

Clinically, expression of *PGRN* mutations varies considerably, even within the same family in addition to between different families. Age at onset is also quite variable, once again, even among members of the same family.<sup>47</sup> These mutations may present as CBS,<sup>48–51</sup> PNFA,<sup>23,51,52</sup> and bv-FTD,<sup>48</sup> with apathy as the dominant trait.<sup>25</sup> Cases of associated MND are exceptional.<sup>53</sup> In patients with *PGRN* mutations, even when asymptomatic, plasma levels of *PGRN* are very low.<sup>47,54–56</sup>

Hexanucleotide repeat expansion of the nucleotide string GGGGCC in the first intron of the *C9ORF72* gene is not only the known mutation most frequently associated with ALS and FTD-MND, but also the second-most frequent in FTLD after *PGRN* mutations. According to DeJesus-Hernandez et al.,<sup>57</sup> 12% of the familial cases of FTD and 22.5% of ALS cases are associated with that mutation. Slightly higher prevalences have been found in Nordic populations: the mutation was present in 46% of the population with familial ALS, 21.1% in sporadic ALS, and 29.3% in FTD in Finland.<sup>58</sup>

Mutations in the *C9ORF72* gene, associated with FTLD-TDP pathology, may manifest clinically as bv-FTD, ALS, or FTD-MND. Presentations vary considerably, even between

members of the same family. In the study by DeJesus-Hernandez et al.,<sup>57</sup> 26.9% of the patients with FTLD also presented ALS, and more than 30% had family members with ALS.

Mutations in the *VCP-1* gene are associated with a rare autosomal dominant disorder that presents with myopathy (90%), Paget's disease of bone, and less frequently, FTD (30%). FTD usually appears years after the onset of muscular symptoms.<sup>59</sup> According to Sampathu's and Mackenzie's histopathological classification systems for types of FTLD-TDP, the above entity is known as subtype 4.<sup>60</sup> Biopsy typically reveals myopathic inclusion bodies.

Mutations in the *CHMP2B* gene, which until now have only been detected in 5 families, are typically associated with bv-FTD, with or without associated pyramidal or extrapyramidal signs.<sup>61,62</sup> Myoclonia may also appear in later stages.<sup>61</sup> There are only 2 published cases of associated MND.<sup>63</sup> From a neuropathology viewpoint, they are associated with FTLD-UPS.

Mutations in the *TARDBP* and *FUS* genes are fundamentally associated with cases of familial ALS and only rarely do they cause FTD.<sup>64–67</sup>

The relationship between different clinical phenotypes and underlying disease in genetic cases differs from that found in sporadic cases. For example, PNFA and CBS in sporadic cases are more commonly associated with FTLD-tau, whereas in familial cases, the same symptoms would be more frequently found in FTLD-TDP (especially type 1). Either sporadic or familial bv-FTD may be associated with FTLD-tau or FTLD-TDP indiscriminately. Cases of SD and PSPS are almost always sporadic.

## Neuroimaging biomarkers

### Structural neuroimaging: brain magnetic resonance

Neurodegenerative diseases are associated with progressive cerebral atrophy. This process can be measured and quantified using structural neuroimaging techniques, including brain MRI. Measuring atrophy using neuroimaging techniques has been shown to be a useful biomarker in other neurodegenerative diseases.<sup>68,69</sup>

The relationship between different FTD syndromes and the pattern of atrophy is now well-defined. In general, bv-FTD is associated with atrophy predominantly affecting the frontal lobe, insula, anterior cingulate, and anterior temporal lobe in an asymmetrical pattern (predominantly in the non-dominant hemisphere). SD is associated with asymmetrical atrophy affecting the anterior inferior temporal lobes, whereas PNFA is associated with asymmetrical atrophy of the anterior perisylvian cortex (more pronounced in the dominant hemisphere).<sup>70–72</sup>

Lindberg et al.<sup>73</sup> analysed the volumes of 9 cortical regions of interest in 61 individuals (27 controls, 12 with bv-FTD, 9 with PNFA, and 13 with SD) and compared findings between the different clinical entities. They observed that it was possible to distinguish between these syndromes with relatively high levels of sensitivity and specificity. Identifying atrophy as temporal or frontal was the best discriminator between SD and the other 2 clinical subtypes. Laterality of

atrophy (right vs left) was the most useful feature for discriminating between bv-FTD and PNFA. Despite the above, doctors must be mindful that there is a certain degree of heterogeneity and overlap between neuroanatomical findings, and that brain MRI may not show alterations in early stages of disease.

Cerebral alterations found in bv-FTD are not limited to the cerebral cortex. Atrophy also affects numerous subcortical regions, including the amygdala, hippocampus, caudate nucleus, striatum, putamen, thalamus, and hypothalamus.<sup>74,75</sup> In fact, amygdalar atrophy may be a useful marker for distinguishing between bv-FTD and Alzheimer disease.<sup>74</sup> Similarly, Chao et al.<sup>76</sup> observed that reduced volume of frontal white matter is indicative of reduction in volume in adjacent grey matter in patients with bv-FTD, and that different FTD subtypes are associated with different white matter atrophy patterns.

### Early changes, progression, and stages of behavioural variant frontotemporal dementia

Developing automated quantitative methods, such as voxel-based morphometry and cortical thickness mapping, has been crucial for the detection of selective atrophy of the anterior cingulate and the frontal and insular cortices in early stages of bv-FTD.<sup>71,77,78</sup> This differs from the atrophy pattern observed in other FTD variants and other types of dementia, including AD.<sup>79</sup> Macroscopic changes may not be apparent in early clinical phases, even though molecular disease is known to be present in the brain several years before symptoms appear (preclinical phase). The yearly rate of overall cerebral atrophy in bv-FTD is as high as 8%, or nearly twice that observed in AD. However, some patients with bv-FTD may present lower rates (0.3% yearly) that resemble those seen in healthy individuals.<sup>80</sup> This low figure may be due to phenocopies being included among cases.

The advance of brain atrophy in FTD has been studied by analysing the pattern of atrophy in patients with different progression times.<sup>81</sup> In initial phases, atrophy generally affects the medial and orbital frontal lobe. It subsequently affects the temporal pole, hippocampal formation, frontal dorsolateral cortex, and basal ganglia. This progression pattern has been linked to the volume of the cortical and subcortical regions, and to underlying neuronal loss.<sup>82,83</sup> As a result, determining the atrophy pattern is a useful way of identifying the stage of the disease.<sup>84,85</sup> Based on these findings, Kipps et al.<sup>86</sup> proposed a visual assessment scale using brain MRI.

Seeley et al.<sup>77</sup> carried out a case-control study in patients with bv-FTD at different stages of progression. These researchers classified cases in 3 groups according to scores on the Clinical Dementia Rating scale: CDR 0.5, CDR 1, and CDR 2-3. The group in the mildest stage (CDR 0.5) displayed bilateral but asymmetrical atrophy, predominantly in the right hemisphere, affecting different regions of the frontal lobe (rostromedial, frontal pole, dorsolateral, and orbitofrontal), anterior cingulate cortex, anterior insula, hippocampus, and subcortical areas (ventral striatum, dorsomedial thalamus). Atrophy was more widespread in the above areas in subjects with higher CDR scores, especially

in the frontal lobe, and it extended to more posterior areas including the posterior insula and the temporal and parietal lobes. Another study of cases of bv-FTD confirmed by a pathology study showed similar results.<sup>87</sup>

Subsequent studies suggest that the areas affected in early stages of the disease (frontal, insular, and anterior cingulate) form part of a structurally and functionally differentiated circuit called the salience network (SN). The anatomical substrate of this neural circuit are the von Economo cells, a unique neuronal population that probably plays a fundamental role in social cognition.<sup>88,89</sup> A study using functional cerebral MRI found the clinical severity of bv-FTD to be correlated with the degree of disruption in right-sided SN connectivity.<sup>90</sup> Nevertheless, given the heterogeneity of bv-FTD pathology, it is not clear whether or not this neural circuit undergoes similar changes in all histopathological subtypes.

### Correlation between anatomy and pathological subtype

An even more interesting prospect is neuroimaging, which has great potential for exploring the pathological process underlying the syndrome.

The first studies carried out provided contradictory results; some showed differences between patients with FTLD-tau and FTLD-U,<sup>91</sup> while others found very similar patterns of atrophy.<sup>92</sup> In 2009, Whitwell et al.<sup>93</sup> used morphometry to analyse regional cortical atrophy in a cohort of 66 patients with a clinical diagnosis of bv-FTD. They observed that half of the patients presented predominantly frontal atrophy, while the other half showed temporal predominance. Based on these findings, they established 4 anatomical subtypes: frontal-dominant, frontotemporal, temporofrontoparietal, and temporal-dominant. The patients with frontal-dominant and frontotemporal atrophy patterns predominantly presented frontal lobe impairment (orbitofrontal, medial frontal, and dorsolateral regions); atrophy was quite restricted in the first pattern, but less restricted and also appearing in temporal areas in the second. Patients with the temporofrontoparietal pattern characteristically showed temporoparietal and medial frontal atrophy. The least frequent subtype was temporal-dominant, in which atrophy was restricted to the inferior and medial region of the temporal lobe. This pattern was associated with predominantly right-sided atrophy in all cases, and with *MAPT* mutations in 83% of the cases. *PGRN* mutations, unlike those previously listed, were never associated with the temporal-dominant subtype; this indicates that the anatomical pattern may be useful in distinguishing between *MAPT* and *PGRN* mutations. Cases of the temporal-dominant subtype showed poorer results on language and memory tests, and those with the frontal-dominant subtype scored lower for executive function, but differences were not statistically significant. The most frequent behavioural symptom in subtypes with frontal atrophy was apathy (76%), and this is not the case in the temporal-dominant subtype. Among patients who had undergone pathology studies, there were no clear correlations between the anatomical pattern and pathological subtype except in patients diagnosed with FTLD-TDP associated with MND, whose atrophy patterns

**Table 2** Correlations between histopathology, atrophy pattern, and clinical syndrome

Histopathological type	Histopathological subtype	Atrophy pattern	Clinical syndrome
FTLD-TDP	Type 1	Diffuse asymmetrical extratemporal	Variable (bv-FTD)
	Type 1 due to <i>PGRN</i> mutation	Diffuse asymmetrical extratemporal	Variable
	Type 3	–	FTD-MND
	Type 2	Asymmetrical temporal	SD
FTLD-tau	Associated with <i>MAPT</i> gene mutation	Symmetrical temporal	bv-FTD
	PiD	Diffuse asymmetrical extratemporal	Variable
	CBD	Diffuse asymmetrical extratemporal	Variable
	PSP	–	PSPS
FTLD-FUS	–	Diffuse localised symmetrical	Early onset bv-FTD

FTLD-TDP subtypes 1-3 are designated according to Mackenzie's classification.

CBD: corticobasal degeneration; FTD-MND: frontotemporal dementia associated with motor neuron disease; bv-FTD: behavioural variant of frontotemporal dementia; FTLD-FUS: frontotemporal lobar degeneration associated with fused-in sarcoma protein; FTLD-TDP: frontotemporal lobar degeneration associated with TAR DNA-binding protein 43; FTLD-Tau: frontotemporal lobar degeneration with tau inclusions; SD: semantic dementia; FUS: fused-in sarcoma protein; MAPT: microtubule associated protein; PGRN: progranulin; PiD: Pick disease; PSP: progressive supranuclear palsy; CBS: corticobasal syndrome; PSPS: progressive supranuclear palsy syndrome.

Based on data from Rohrer et al.<sup>94</sup>

were restricted to the frontal lobe. In addition to being associated with TDP-43, the temporofrontoparietal pattern was associated with AD or CBD in 3 subjects. According to these authors, the frontotemporal subtype may be a stage in bv-FTD progression; it would begin as frontal-dominant atrophy and subsequently extend to the temporal lobes. The temporofrontoparietal pattern cannot be explained in the same way. Frontal atrophy detected in this pattern was less pronounced than in cases with a frontal-dominant pattern, and temporal atrophy was also less pronounced than in temporal-dominant cases.<sup>93</sup>

In 2011, Rohrer et al.<sup>94</sup> presented a retrospective study in which they analysed clinical, neuropsychological, and neuroimaging data (using voxel-based volumetry and morphometry) in a cohort of 95 patients with a diagnosis of FTLD confirmed by pathology study. These researchers attempted to find clinical-anatomical correlations for all histopathological subtypes. They classified anatomical findings in 4 patterns based on symmetry or asymmetry and the temporal or extratemporal location of atrophy. They observed that specific pathological subtypes exhibited a significant association with distinct clinical syndromes, also finding an association between some subtypes and certain atrophy patterns (Table 2).

### Role of neuroimaging in the differential diagnosis of FTD and other dementia types

It is usually easy to distinguish between FTD and AD based on clinical observation. However, some patients with FTD initially exhibit marked changes in episodic memory, and patients with Alzheimer disease may also show atypical disease presentations. Examples include language-variant AD (usually logopenic PPA), frontal-variant AD (with striking behavioural and executive changes), posterior cortical atrophy (usually presenting with visuospatial and/or visuo-perceptual changes and sometimes known as 'visual variant'), or CBS associated with AD.

Structural MRI with voxel-based morphometry is a useful tool for distinguishing between FTD and AD. FTD exhibits

atrophy in the frontal, insular, anterior cingulate, and striate regions, whereas AD shows posterior parietal and occipital atrophy.<sup>95</sup> Regional cortical thickness analysis is also helpful, since AD cases will show cortical thinning at the parietal and precuneal levels.<sup>96</sup>

Other MRI techniques used in distinguishing AD from FTLD include diffusion tensor imaging sequence<sup>97</sup> (decreased fractional anisotropy in frontal regions in FTLD), arterial spin labelling<sup>98,99</sup> (hypoperfusion in parietal regions and posterior cingulate in AD vs frontal lobe hypoperfusion in FTLD), and combined techniques using positron-emission tomography (PET) with F18-fluorodeoxyglucose (FDG)/RM.<sup>100</sup>

Several studies performed on atypical variants of AD have shown that, regardless of clinical presentation, AD is associated with impairment in the posterior cingulate gyrus, precuneus, posterior parietal regions, and medial temporal regions.<sup>101,102</sup> Other studies have compared patients with PPA and AD to those with PPA only. They found that the patients with AD (usually associated with logopenic PPA) presented more pronounced temporoparietal atrophy, while those with FTLD had imaging studies showing typical 'knife-edge' atrophy of the temporal lobe.<sup>103,104</sup>

Less frequently, FTLD may be confused with Lewy body dementia (LBD), fundamentally in patients who experience visual illusions or hallucinations.<sup>105,106</sup> A recent study in a small sample suggested that I<sup>123</sup>-MIBG scintigraphy may be useful for distinguishing between these 2 entities, because LBD, unlike FTLD, shows a pronounced decrease in contrast uptake.<sup>106</sup> In another small study, MR images were not useful for differential diagnosis.<sup>107</sup>

### Functional neuroimaging: cerebral positron-emission tomography and single-photon emission computed tomography

Recent years have seen increasing use of functional neuroimaging techniques, including single-photon emission computed tomography (SPECT) using Tc<sup>99m</sup>-hexamethylpropyleneamine oxime, or <sup>18</sup>F-FDG-PET, in

the diagnosis of bv-FTD. Hypoperfusion/hypometabolism is observed in frontal regions in bv-FTD, whereas AD displays hypoperfusion in the temporoparietal and posterior cingulate areas.<sup>108,109</sup> Both SPECT and FDG-PET are more sensitive than brain MRI for detecting the early changes occurring in bv-FTD.<sup>110</sup> FDG-PET is also very important for detecting phenocopies, since these cases will show preserved metabolism in the frontal regions. However, using FDG-PET in patients whose MRI shows clear cerebral atrophy is unlikely to provide any additional benefit.

Some PET techniques employ new radioisotopes. One uses a compound called carbon 11-labelled Pittsburgh compound B, which binds to  $\beta$ -amyloid and has shown promising results for differential diagnosis of AD and FTD,<sup>111,112</sup> especially in cases displaying language alteration.<sup>113,114</sup> Other techniques are currently being developed, including PET imaging of tau, PGRN, or FUS. These promising diagnostic tools may be ready for use in the near future.

## Biomarkers in plasma and cerebrospinal fluid

Low CSF levels of the 42 amino acid beta-amyloid peptide (A  $\beta$ 42), and high levels of tau protein, are biomarkers that are both sensitive and specific for diagnosis of AD.<sup>115,116</sup> Tau/beta amyloid ratio: A  $\beta$ 42 is a useful parameter for distinguishing FTL from AD since it is lower in FTL.<sup>117</sup> Researchers have reported high levels of TDP-43 in cerebrospinal fluid from patients whose diagnosis of FTD-MND had not been confirmed by a histopathological study.<sup>118</sup>

Various studies have shown that patients with mutations in the *PGRN* gene display very low plasma levels of PGRN.<sup>54,55,119</sup> Measuring plasma PGRN levels has been proposed as a sensitive and specific screening method for use in these patients.<sup>120</sup>

Other research indicates that plasma levels of TDP-43 may be related to cerebral impairment in patients with FTL.<sup>121</sup>

## Conclusions

Picturing FTL on the molecular level is a way of gaining a more precise understanding of the disease in terms of its causal mechanisms. This also opens the doors to new treatment options. Ligand-specific drugs are currently being developed to search out defined molecular targets.

Of all of the clinical variants, bv-FTD is the most heterogeneous variety, which makes it difficult to predict the underlying disease type. It is possible that this syndrome describes a concept that is too broad and actually includes a number of very different entities. As a result, identifying differential clinical features and defining clinical subtypes may provide better clinical-pathological correlations. In any case, as a complement to clinical evaluation techniques, doctors must develop tools that will deliver

in vivo histopathological and molecular diagnoses of these processes.

Structural and functional neuroimaging, biomarkers in laboratory analyses, and genetic studies are being transformed into useful tools for diagnosis or differential diagnosis and for predicting the underlying pathological process. Of all of the biomarkers that have been listed, we should stress the importance of functional neuroimaging. It is more sensitive than structural neuroimaging in early stages of the disease, and it can be used in novel techniques with specific radiotracers (<sup>11</sup>C-labelled Pittsburgh compound B and tracers for tau, PGRN, and FUS). This technique is emerging as an instrument that promises good results in the near future.

## Conflicts of interest

The authors have no conflicts of interest to declare.

## References

1. Cairns NJ, Bigio EH, Mackenzie IRA, Neumann M, Lee VM-Y, Hatanpaa KJ, et al. Neuropathologic diagnostic and nosologic criteria for frontotemporal lobar degeneration: consensus of the Consortium for Frontotemporal Lobar Degeneration. *Acta Neuropathol.* 2007;114:5–22.
2. Mackenzie IR, Neumann M, Bigio EH, Cairns NJ, Alafuzoff I, Kril J, et al. Nomenclature and nosology for neuropathologic subtypes of frontotemporal lobar degeneration: an update. *Acta Neuropathol.* 2010;119:1–4.
3. Matías-Guiu JA, García-Ramos R. Afasia progresiva primaria: del síndrome a la enfermedad. *Neurologia.* 2012; <http://dx.doi.org/10.1016/j.nrl.2012.04.003>.
4. Mesulam M, Wicklund A, Johnson N, Rogalski E, Leger GC, Rademaker A, et al. Alzheimer and frontotemporal pathology in subsets of primary progressive aphasia. *Ann Neurol.* 2008;63:709–19.
5. Alladi S, Xuereb J, Bak T, Nestor P, Knibb J, Patterson K, et al. Focal cortical presentations of Alzheimer's disease. *Brain.* 2007;130:2636–45.
6. Kertesz A, McMonagle P, Blair M, Davidson W, Munoz DG. The evolution and pathology of frontotemporal dementia. *Brain.* 2005;128:1996–2005.
7. Knopman DS, Boeve BF, Parisi JE, Dickson DW, Smith GE, Ivnik RJ, et al. Antemortem diagnosis of frontotemporal lobar degeneration. *Ann Neurol.* 2005;57:480–8.
8. Johnson JK, Head E, Kim R, Starr A, Cotman CW. Clinical and pathological evidence for a frontal variant of Alzheimer disease. *Arch Neurol.* 1999;56:1233–9.
9. Josephs KA, Hodges JR, Snowden JS, Mackenzie IR, Neumann M, Mann DM, et al. Neuropathological background of phenotypical variability in frontotemporal dementia. *Acta Neuropathol.* 2011;122:137–53.
10. Davidson Y, Kelley T, Mackenzie IRA, Pickering-Brown S, Du Plessis D, Neary D, et al. Ubiquitinated pathological lesions in frontotemporal lobar degeneration contain the TAR DNA-binding protein. TDP-43. *Acta Neuropathol.* 2007;113:521–33.
11. Grossman M, Wood EM, Moore P, Neumann M, Kwong L, Forman MS, et al. TDP-43 pathologic lesions and clinical phenotype in frontotemporal lobar degeneration with ubiquitin-positive inclusions. *Arch Neurol.* 2007;64:1449–54.



12. Hodges JR, Davies RR, Xuereb JH, Casey B, Broe M, Bak TH, et al. Clinicopathological correlates in frontotemporal dementia. *Ann Neurol*. 2004;56:399–406.
13. Snowden J, Neary D, Mann D. Frontotemporal lobar degeneration: clinical and pathological relationships. *Acta Neuropathol*. 2007;114:31–8.
14. Josephs KA, Stroh A, Dugger B, Dickson DW. Evaluation of subcortical pathology and clinical correlations in FTL-D-U subtypes. *Acta Neuropathol*. 2009;118:349–58.
15. Josephs KA, Petersen RC, Knopman DS, Boeve BF, Whitwell JL, Duffy JR, et al. Clinicopathologic analysis of frontotemporal and corticobasal degenerations and PSP. *Neurology*. 2006;66:41–8.
16. Forman MS, Farmer J, Johnson JK, Clark CM, Arnold SE, Coslett HB, et al. Frontotemporal dementia: clinicopathological correlations. *Ann Neurol*. 2006;59:952–62.
17. Mackenzie IRA, Baker M, Pickering-Brown S, Hsiung G-YR, Lindholm C, Dwosh E, et al. The neuropathology of frontotemporal lobar degeneration caused by mutations in the progranulin gene. *Brain*. 2006;129:3081–90.
18. Mackenzie IRA, Baborie A, Pickering-Brown S, Plessis DD, Jaros E, Perry RH, et al. Heterogeneity of ubiquitin pathology in frontotemporal lobar degeneration: classification and relation to clinical phenotype. *Acta Neuropathol*. 2006;112:539–49.
19. Fernández Matarrubia M, Matías-Guiu JA, Moreno-Ramos T, Matías-Guiu J. *Neurología*. 2013, <http://dx.doi.org/10.1016/j.nrl.2013.03.001>.
20. Snowden JS, Hu Q, Rollinson S, Halliwell N, Robinson A, Davidson YS, et al. The most common type of FTL-D-FUS (aFTLD-U) is associated with a distinct clinical form of frontotemporal dementia but is not related to mutations in the FUS gene. *Acta Neuropathol*. 2011;122:99–110.
21. Urwin H, Josephs KA, Rohrer JD, Mackenzie IR, Neumann M, Authier A, et al. FUS pathology defines the majority of tau and TDP-43-negative frontotemporal lobar degeneration. *Acta Neuropathol*. 2010;120:33–4.
22. Josephs KA, Whitwell JL, Jack CR Jr. Anatomic correlates of stereotypies in frontotemporal lobar degeneration. *Neurobiol Aging*. 2008;29:1859–63.
23. Josephs KA, Whitwell JL, Parisi JE, Petersen RC, Boeve BF, Jack CR Jr, et al. Caudate atrophy on MRI is a characteristic feature of FTL-D-FUS. *Eur J Neurol*. 2010;17:969–75.
24. Lillo P, Garcin B, Hornberger M, Bak TH, Hodges JR. Neurobehavioral features in frontotemporal dementia with amyotrophic lateral sclerosis. *Arch Neurol*. 2010;67:826–30.
25. Pickering-Brown SM, Rollinson S, Du Plessis D, Morrison KE, Varma A, Richardson AM, et al. Frequency and clinical characteristics of progranulin mutation carriers in the Manchester frontotemporal lobar degeneration cohort: comparison with patients with MAPT and no known mutations. *Brain*. 2008;131:721–31.
26. Josephs KA, Whitwell JL, Knopman DS, Boeve BF, Vemuri P, Senjem ML, et al. Two distinct subtypes of right temporal variant frontotemporal dementia. *Neurology*. 2009;73:1443–50.
27. Pickering-Brown SM, Richardson AM, Snowden JS, McDonagh AM, Burns A, Braude W, et al. Inherited frontotemporal dementia in nine British families associated with intronic mutations in the tau gene. *Brain*. 2002;125:732–75.
28. Williams DR, de Silva R, Paviour DC, Pittman A, Watt HC, Kilford L, et al. Characteristics of two distinct clinical phenotypes in pathologically proven progressive supranuclear palsy: Richardson's syndrome and PSP-Parkinsonism. *Brain*. 2005;128:1247–58.
29. Cairns NJ, Grossman M, Arnold SE, Burn DJ, Jaros E, Perry RH, et al. Clinical and neuropathologic variation in neuronal intermediate filament inclusion disease. *Neurology*. 2004;63:1376–84.
30. Josephs KA, Lin WL, Ahmed Z, Stroh DA, Graff-Radford NR, Dickson DW. Frontotemporal lobar degeneration with ubiquitin-positive, but TDP-43-negative inclusions. *Acta Neuropathol*. 2008;116:159–67.
31. Josephs KA, Uchikado H, McComb RD, Bashir R, Wszolek Z, Swanson J, et al. Extending the clinicopathological spectrum of neurofilament inclusion disease. *Acta Neuropathol*. 2005;109:427–32.
32. Molina-Porcel L, Lladó A, Rey MJ, Molinuevo JL, Martínez-Lage M, Esteve FX, et al. Clinical and pathological heterogeneity of neuronal intermediate filament inclusion disease. *Arch Neurol*. 2008;65:272–5.
33. Muñoz DG, Neumann M, Kusaka H, Yokota O, Ishihara K, Terada S, et al. FUS pathology in basophilic inclusion body disease. *Acta Neuropathol*. 2009;118:617–27.
34. Neumann M, Rademakers R, Roeber S, Baker M, Kretzschmar HA, Mackenzie IR. A new subtype of frontotemporal lobar degeneration with FUS pathology. *Brain*. 2009;132:2922–31.
35. Neumann M, Roeber S, Kretzschmar HA, Rademakers R, Baker M, Mackenzie IR. Abundant FUS-immunoreactive pathology in neuronal intermediate filament inclusion disease. *Acta Neuropathol*. 2009;118:605–16.
36. Urwin H, Josephs KA, Rohrer JD, Mackenzie IR, Neumann M, Authier A, et al. FUS pathology defines the majority of tau and TDP-43-negative frontotemporal lobar degeneration. *Acta Neuropathol*. 2010;120:33–41.
37. Boeve B. Relationship between frontotemporal dementia, corticobasal degeneration, progressive supranuclear palsy and amyotrophic lateral sclerosis. *Alzheimer Dis Assoc Disord*. 2007;21:531–8.
38. Kertesz A, Blair M, McMonagle P, Muñoz D. The diagnostic and evolution of frontotemporal dementia. *Alzheimer Dis Assoc Disord*. 2007;21:155–63.
39. Hutton M, Lendon CL, Rizzu P, Baker M, Froelich S, Houlden H, et al. Association of missense and 5'-splice-site mutations in tau with the inherited dementia FTDP-17. *Nature*. 1998;393:702–5.
40. Van Swieten J, Spillantini MG. Hereditary frontotemporal dementia caused by Tau gene mutations. *Brain Pathol*. 2007;17:63–73.
41. Ghetti B, Hutton M, Wszolek Z. Frontotemporal dementia and Parkinsonism linked to chromosome 17 associated with tau gene mutations (FTDP-17t). In: Dickson D, editor. *Neurodegeneration: the molecular pathology of dementia and movement disorders*. Basel: ISN Neuropath Press; 2003. p. 86–102.
42. Rohrer JD, Ridgway GR, Modat M, Ourselin S, Mead S, Fox NC, et al. Distinct profiles of brain atrophy in frontotemporal lobar degeneration caused by progranulin and tau mutations. *Neuroimage*. 2010;53:1070–6.
43. Whitwell JL, Jack CR Jr, Boeve BF, Senjem ML, Baker M, Rademakers R, et al. Voxel-based morphometry patterns of atrophy in FTL-D with mutations in MAPT or PGRN. *Neurology*. 2009;72:813–20.
44. Cairns NJ, Neumann M, Bigio EH, Holm IE, Troost D, Hatanpaa KJ, et al. TDP-43 in familial and sporadic frontotemporal lobar degeneration with ubiquitin inclusions. *Am J Pathol*. 2007;171:227–40.
45. Josephs KA, Ahmed Z, Katsuse O, Parisi JF, Boeve BF, Knopman DS, et al. Neuropathologic features of frontotemporal lobar degeneration with ubiquitin-positive inclusions with progranulin gene (PGRN) mutations. *J Neuropathol Exp Neurol*. 2007;66:142–51.
46. Mackenzie IR, Baker M, Pickering-Brown S, Hsiung GY, Lindholm C, Dwosh E, et al. The neuropathology of frontotemporal lobar

- degeneration caused by mutations in the progranulin gene. *Brain*. 2006;129:3081–90.
47. Pietroboni AM, Fumagalli GG, Ghezzi L, Fenoglio C, Cortini F, Serpente M, et al. Phenotypic heterogeneity of the GRN Asp22fs mutation in a large Italian kindred. *J Alzheimers Dis*. 2011;24:253–9.
  48. Kelley BJ, Haidar W, Boeve BF, Baker M, Graff-Radford NR, Krefft T, et al. Prominent phenotypic variability associated with mutations in progranulin. *Neurobiol Aging*. 2009;30:739–51.
  49. Masellis M, Momeni P, Meschino W, Heffner R Jr, Elder J, Sato C, et al. Novel splicing mutation in the progranulin gene causing familial corticobasal syndrome. *Brain*. 2006;129:3115–23.
  50. Spina S, Murrell JR, Huey ED, Wassermann EM, Pietrini P, Grafman J, et al. Corticobasal syndrome associated with the A9D progranulin mutation. *J Neuropathol Exp Neurol*. 2007;66:892–900.
  51. Mesulam M, Johnson N, Krefft TA, Gass JM, Cannon AD, Adamson JL, et al. Progranulin mutations in primary progressive aphasia: the PPA1 and PPA3 families. *Arch Neurol*. 2007;64:43–7.
  52. Snowden JS, Pickering-Brown SM, Mackenzie IR, Richardson AM, Varma A, Neary D, et al. Progranulin gene mutations associated with frontotemporal dementia and progressive non-fluent aphasia. *Brain*. 2006;129:3091–102.
  53. Gass J, Cannon A, Mackenzie IR, Boeve B, Baker M, Adamson J, et al. Mutations in progranulin are a major cause of ubiquitin-positive frontotemporal lobar degeneration. *Hum Mol Genet*. 2006;15:2988–3001.
  54. Finch N, Baker M, Crook R, Swanson K, Kuntz K, Surtees R, et al. Plasma progranulin levels predict progranulin mutation status in frontotemporal dementia patients and asymptomatic family members. *Brain*. 2009;132:583–91.
  55. Ghidoni R, Benussi L, Glionna M, Franzoni M, Binetti G. Low plasma progranulin levels predict progranulin mutations in frontotemporal lobar degeneration. *Neurology*. 2008;71:1235–9.
  56. Carecchio M, Fenoglio C, Cortini F, Comi C, Benussi L, Ghidoni R, et al. Cerebrospinal fluid biomarkers in Progranulin mutations carriers. *J Alzheimers Dis*. 2011;27:781–90.
  57. DeJesus-Hernandez M, Mackenzie IR, Boeve BF, Boxer AL, Baker M, Rutherford NJ, et al. Expanded GGGGCC hexanucleotide repeat in noncoding region of C9ORF72 causes chromosome 9p-linked FTD and ALS. *Neuron*. 2011;72:245–56.
  58. Renton AE, Majounie E, Waite A, Simón-Sánchez J, Rollinson S, Gibbs JR, et al. A hexanucleotide repeat expansion in C9ORF72 is the cause of chromosome 9p21-linked ALS-FTD. *Neuron*. 2011;72:257–68.
  59. Watts GD, Wymer J, Kovach MJ, Mehta SG, Mumm S, Darvish D, et al. Inclusion body myopathy associated with Paget disease of bone and frontotemporal dementia is caused by mutant valosin-containing protein. *Nat Genet*. 2004;36:377–81.
  60. Neumann M, Mackenzie IR, Cairns NJ, Boyer PJ, Markesbery WR, Smith CD, et al. TDP-43 in the ubiquitin pathology of frontotemporal dementia with VCP mutations. *J Neuropathol Exp Neurol*. 2007;66:152–7.
  61. Gydesen S, Brown JM, Brun A, Chakrabarti L, Gade A, Johannsen P, et al. Chromosome 3 linked frontotemporal dementia (FTD-3). *Neurology*. 2002;59:1585–94.
  62. Van der Zee J, Urwin H, Engelborghs S, Bruyland M, Vandenberghe R, Dermaut B, et al. CHMP2B C-truncating mutations in frontotemporal lobar degeneration are associated with an aberrant endosomal phenotype in vitro. *Hum Mol Genet*. 2008;17:313–22.
  63. Parkinson N, Ince PG, Smith MO, Highley R, Skibinski G, Andersen PM, et al. ALS phenotypes with mutations in CHMP2B (charged multivesicular body protein 2B). *Neurology*. 2006;67:1074–7.
  64. Kabashi E, Valdmanis PN, Dion P, Spiegelman D, McConkey BJ, Van de Velde C, et al. TARDBP mutations in individuals with sporadic and familial amyotrophic lateral sclerosis. *Nat Genet*. 2008;40:572–4.
  65. Kwiatkowski TJ Jr, Bosco DA, Leclerc AL, Tamrazian E, Vandenburg CR, Russ C, et al. Mutations in the FUS/TLS gene on chromosome 16 cause familial amyotrophic lateral sclerosis. *Science*. 2009;323:1205–8.
  66. Sreedharan J, Blair IP, Tripathi VB, Hu X, Vance C, Rogelj B, et al. TDP-43 mutations in familial and sporadic amyotrophic lateral sclerosis. *Science*. 2008;319:1668–72.
  67. Vance C, Rogelj B, Hortobagyi T, De Vos KJ, Nishimura AL, Sreedharan J, et al. Mutations in FUS, an RNA processing protein, cause familial amyotrophic lateral sclerosis type 6. *Science*. 2009;323:1208–11.
  68. Vemuri P, Whitwell JL, Kantarci K, Josephs KA, Parisi JE, Shiung MS, et al. Antemortem MRI based Structural Abnormality iNDEX (STAND)-scores correlate with postmortem Braak neurofibrillary tangle stage. *Neuroimage*. 2008;42:559–67.
  69. Whitwell JL, Josephs KA, Murray ME, Kantarci K, Przybelski SA, Weigand SD, et al. MRI correlates of neurofibrillary tangle pathology at autopsy: a voxel-based morphometry study. *Neurology*. 2008;71:743–9.
  70. Seelaar H, Rohrer JD, Pijnenburg YAL, Fox NC, van Swieten JC. Clinical, genetic and pathological heterogeneity of frontotemporal dementia: a review. *J Neurol Neurosurg Psychiatry*. 2011;82:476–86.
  71. Schroeter ML, Raczka K, Neumann J, Yves von Cramon D. Towards a nosology for frontotemporal lobar degenerations – a meta-analysis involving 267 subjects. *Neuroimage*. 2007;36:497–510.
  72. Schroeter ML, Raczka K, Neumann J, Von Cramon DY. Neural networks in frontotemporal dementia – a meta-analysis. *Neurobiol Aging*. 2008;29:418–26.
  73. Lindberg O, Östberg P, Zandbelt BB, Öberg J, Zhang Y, Andersen C, et al. Cortical morphometric subclassification of frontotemporal lobar degeneration. *Am J Neuroradiol*. 2009;30:1233–9.
  74. Barnes J, Whitwell JL, Frost C, Josephs KA, Rossor M, Fox NC. Measurements of the amygdala and hippocampus in pathologically confirmed Alzheimer disease and frontotemporal lobar degeneration. *Arch Neurol*. 2006;63:1434–9.
  75. Piguet O, Petersén Á, Yin Ka Lam B, Gabery S, Murphy K, Hodges JR, et al. Eating and hypothalamus changes in behavioral-variant frontotemporal dementia. *Ann Neurol*. 2011;69:312–9.
  76. Chao LL, Schuff N, Clevenger EM, Mueller SG, Rosen HJ, Gorno-Tempini ML, et al. Patterns of white matter atrophy in frontotemporal lobar degeneration. *Arch Neurol*. 2007;64:1619–24.
  77. Seeley WW, Crawford R, Rascofsky K, Kramer JH, Weiner M, Miller BL, et al. Frontal paralimbic network atrophy in very mild behavioral variant frontotemporal dementia. *Arch Neurol*. 2008;65:249–55.
  78. Boccardi M, Sabbatoli F, Laakso MP, Testa C, Rossi R, Beltramello A, et al. Frontotemporal dementia as a neural system disease. *Neurobiol Aging*. 2005;26:37–44.
  79. Davies RR, Scihill VL, Graham A, Williams GB, Graham KS, Hodges JR. Development of an MRI rating scale for multiple brain regions: comparison with volumetrics and with voxel-based morphometry. *Neuroradiology*. 2009;51:491–503.
  80. Chan D, Fox NC, Jenkins R, Scihill RI, Crum WR, Rossor MN. Rates of global and regional cerebral atrophy in AD and frontotemporal dementia. *Neurology*. 2001;57:1756–63.
  81. Broe M, Hodges JR, Schofield E, Shepherd CE, Kril JJ, Halliday GM. Staging disease severity in pathologically confirmed cases of frontotemporal dementia. *Neurology*. 2003;60:1005–11.

82. Kersaitis C, Halliday GM, Kril JJ. Regional and cellular pathology in frontotemporal dementia: relationship to stage of disease in cases with and without Pick bodies. *Acta Neuropathol.* 2004;108:515–23.
83. Kril JJ, Macdonald V, Patel S, Png F, Halliday GM. Distribution of brain atrophy in behavioral variant frontotemporal dementia. *J Neurol Sci.* 2005;232:83–90.
84. Roberson ED, Hesse JH, Rose KD, Slama H, Johnson JK, Yaffe K, et al. Frontotemporal dementia progresses to death faster than Alzheimer disease. *Neurology.* 2005;65:719–25.
85. Mendez MF. Frontotemporal dementia: therapeutic interventions. *Front Neurol Neurosci.* 2009;24:168–78.
86. Kipps CM, Davies RR, Mitchell J, Kril JJ, Halliday GM, Hodges JR. Clinical significance of lobar atrophy in frontotemporal dementia: application of an MRI visual rating scale. *Dement Geriatr Cogn Disord.* 2007;23:334–42.
87. Whitwell JL, Jack CR, Senjem ML, Parisi JE, Boeve BF, Knopman DS, et al. MRI correlates of protein deposition and disease severity in postmortem frontotemporal lobar degeneration. *Neurodegener Dis.* 2009;6:106–17.
88. Seeley WW. Selective functional, regional, and neuronal vulnerability in frontotemporal dementia. *Curr Opin Neurol.* 2008;21:701–7.
89. Seeley WW, Crawford RK, Zhou J, Miller BL, Greicius MD. Neurodegenerative diseases target large-scale human brain networks. *Neuron.* 2009;62:42–52.
90. Zhou J, Greicius MD, Gennatas ED, Growdon ME, Jang JY, Rabinovici GD, et al. Divergent network connectivity changes in behavioural variant frontotemporal dementia and Alzheimer's disease. *Brain.* 2010;133:1352–67.
91. Kim EJ, Rabinovici GD, Seeley WW, Halabi C, Shu H, Weiner MW, et al. Patterns of MRI atrophy in tau positive and ubiquitin positive frontotemporal lobar degeneration. *J Neurol Neurosurg Psychiatry.* 2007;78:1375–8.
92. Pereira JMS, Williams GB, Acosta-Cabronero J, Pengas G, Spillantini MG, Xuereb JH, et al. Atrophy patterns in histologic vs clinical groupings of frontotemporal lobar degeneration. *Neurology.* 2009;72:1653–60.
93. Whitwell JL, Przybelski SA, Weigand SD, Ivnik RJ, Vemuri P, Gunter JL, et al. Distinct anatomical subtypes of the behavioural variant of frontotemporal dementia: a cluster analysis study. *Brain.* 2009;132:2932–46.
94. Rohrer JD, Lashley T, Schott JM, Warren JE, Mead S, Isaacs AM, et al. Clinical and neuroanatomical signatures of tissue pathology in frontotemporal lobar degeneration. *Brain.* 2011;134:2565–81.
95. Rabinovici GD, Seeley WW, Kim EJ, Gorno-Tempini ML, Rascofsky K, Pagliaro TA, et al. Distinct MRI atrophy patterns in autopsy-proven Alzheimer's disease and frontotemporal lobar degeneration. *Am J Alzheimers Dis Other Dement.* 2007;22:474–88.
96. Du A-T, Schuff N, Kramer JH, Rosen HJ, Gorno-Tempini ML, Rankin K, et al. Different regional patterns of cortical thinning in Alzheimer's disease and frontotemporal dementia. *Brain.* 2007;130 Pt 4:1159–66.
97. Zhang Y, Schuff N, Du A-T, Rosen HJ, Kramer JH, Gorno-Tempini ML, et al. White matter damage in frontotemporal dementia and Alzheimer's disease measured by diffusion MRI. *Brain.* 2009;132:2579–92.
98. Du AT, Jahng GH, Hayasaka S, Kramer JH, Rosen HJ, Gorno-Tempini ML, et al. Hypoperfusion in frontotemporal dementia and Alzheimer disease by arterial spin labeling MRI. *Neurology.* 2006;67:1215–20.
99. Hu WT, Wang Z, Lee VM-Y, Trojanowski JQ, Detre JA, Grossman M. Distinct cerebral perfusion patterns in FTL and AD. *Neurology.* 2010;75:881–8.
100. Dukart J, Mueller K, Horstmann A, Barthel H, Möller HE, Villringer A, et al. Combined evaluation of FDG-PET and MRI improves detection and differentiation of dementia. *PLoS ONE.* 2011;6:e18111.
101. Migliaccio R, Agosta F, Rascofsky K, Karydas A, Bonasera S, Rabinovici GD, et al. Clinical syndromes associated with posterior atrophy: early age at onset AD spectrum. *Neurology.* 2009;73:1571–8.
102. Lehmann M, Rohrer JD, Clarkson MJ, Ridgway GR, Scahill RI, Modat M, et al. Reduced cortical thickness in the posterior cingulate gyrus is characteristic of both typical and atypical Alzheimer's disease. *J Alzheimers Dis.* 2010;20:587–98.
103. Xiong L, Xuereb JH, Spillantini MG, Patterson K, Hodges JR, Nestor PJ. Clinical comparison of progressive aphasia associated with Alzheimer versus FTD-spectrum pathology. *J Neurol Neurosurg Psychiatry.* 2011;82:254–60.
104. Hu WT, McMillan C, Libon D, Leight S, Forman M, Lee VM-Y, et al. Multimodal predictors for Alzheimer disease in nonfluent primary progressive aphasia. *Neurology.* 2010;75:595–602.
105. Omar R, Sampson EL, Loy CT, Mummery CJ, Fox NC, Rossor MN, et al. Delusions in frontotemporal lobar degeneration. *J Neurol.* 2009;256:600–7.
106. Novellino F, Bagnato A, Salsone M, Cascini GL, Nicoletti G, Arabia G, et al. Myocardial (123I)-MIBG scintigraphy for differentiation of Lewy bodies disease from FTD. *Neurobiol Aging.* 2010;31:1903–11.
107. Claassen DO, Parisi JE, Giannini C, Boeve BF, Dickson DW, Josephs KA. Frontotemporal dementia mimicking dementia with Lewy bodies. *Cogn Behav Neurol.* 2008;21:157–63.
108. Varma AR, Adams W, Lloyd JJ, Carson KJ, Snowden JS, Testa HJ, et al. Diagnostic patterns of regional atrophy on MRI and regional cerebral blood flow change on SPECT in young onset patients with Alzheimer's disease, frontotemporal dementia and vascular dementia. *Acta Neurol Scand.* 2002;105:261–9.
109. Kanda T, Ishii K, Uemura T, Miyamoto N, Yoshikawa T, Kono AK, et al. Comparison of grey matter and metabolic reductions in frontotemporal dementia using FDG-PET and voxel-based morphometric MR studies. *Eur J Nucl Med Mol Imaging.* 2008;35:2227–34.
110. Piguet O, Hornberger M, Mioshi E, Hodges JR. Behavioural-variant frontotemporal dementia: diagnosis, clinical staging, and management. *Lancet Neurol.* 2011;10:162–72.
111. Rowe CC, Ng S, Ackermann U, Gong SJ, Pike K, Savage G, et al. Imaging beta-amyloid burden in aging and dementia. *Neurology.* 2007;68:1718–25.
112. Engler H, Santillo AF, Wang SX, Lindau M, Savitcheva I, Nordberg A, et al. In vivo amyloid imaging with PET in frontotemporal dementia. *Eur J Nucl Med Mol Imaging.* 2008;35:100–6.
113. Klunk WE, Engler H, Nordberg A, Wang Y, Blomqvist G, Holt DP, et al. Imaging brain amyloid in Alzheimer's disease with Pittsburgh Compound-B. *Ann Neurol.* 2004;55:306–19.
114. Rabinovici GD, Furst AJ, O'Neil JP, Racine CA, Mormino EC, Baker SL, et al. 11C-PIB PET imaging in Alzheimer disease and frontotemporal lobar degeneration. *Neurology.* 2007;68:1205–12.
115. Blennow K, Hampel H. CSF markers for incipient Alzheimer's disease. *Lancet Neurol.* 2003;2:605–13.
116. Sunderland T, Linker G, Mirza N, Putnam KT, Friedman DL, Kimmel LH, et al. Decreased beta-amyloid1-42 and increased tau levels in cerebrospinal fluid of patients with Alzheimer disease. *JAMA.* 2003;289:2094–103.
117. Bian H, Van Swieten JC, Leight S, Massimo L, Wood E, Forman M, et al. CSF biomarkers in frontotemporal lobar degeneration with known pathology. *Neurology.* 2008;70:1827–35.

118. Steinacker P, Hendrich C, Sperfeld AD, Jesse S, von Arnim CAF, Lehnert S, et al. TDP-43 in cerebrospinal fluid of patients with frontotemporal lobar degeneration and amyotrophic lateral sclerosis. *Arch Neurol*. 2008;65:1481–7.
119. Sleegers K, Brouwers N, Van Damme P, Engelborghs S, Gijselinck I, van der Zee J, et al. Serum biomarker for progranulin-associated frontotemporal lobar degeneration. *Ann Neurol*. 2009;65:603–9.
120. Schofield EC, Halliday GM, Kwok J, Loy C, Double KL, Hodges JR. Low serum progranulin predicts the presence of mutations: a prospective study. *J Alzheimers Dis*. 2010;22:981–4.
121. Foulds PG, Davidson Y, Mishra M, Hobson DJ, Humphreys KM, Taylor M, et al. Plasma phosphorylated-TDP-43 protein levels correlate with brain pathology in frontotemporal lobar degeneration. *Acta Neuropathol*. 2009;118:647–58.