

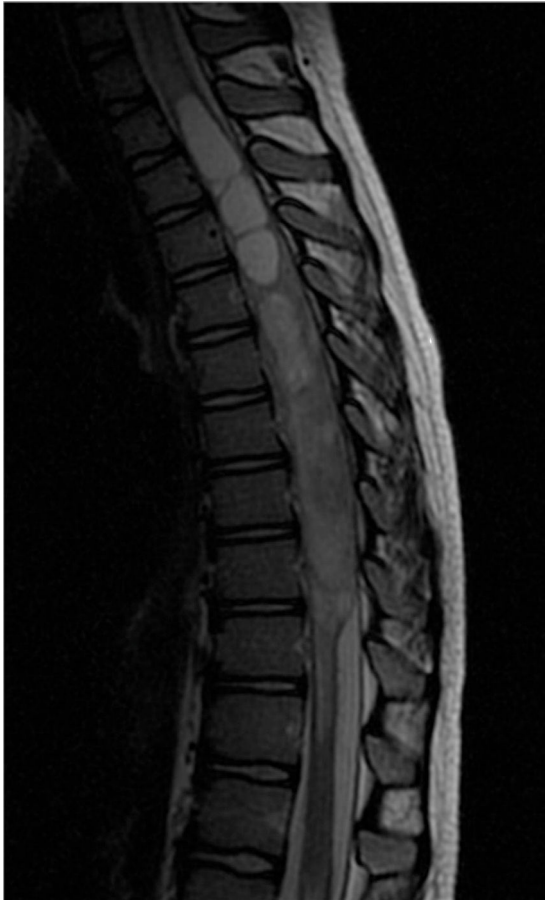

Figure 1 Craniomedullary magnetic resonance imaging study. Sagittal T2-weighted sequence before contrast administration showing an intramedullary tumour from D5 to D9, and syringomyelia proximal to the tumour.

characteristics, a spinal MRI should be performed to rule out compressive diseases of the spinal cord, such as traumatic lesion, haemorrhage, intramedullary abscess, tumour, and transverse myelitis.^{1,5–7} In our case, the diagnosis of GBS was doubtful because of presence of abdominal pain radiating to the lumbar region at symptom onset, bladder symptoms, the asymmetric pattern of weakness, and absent cremasteric and abdominal reflexes. These symptoms led doctors to the

correct diagnosis and treatment. Furthermore, the patient's elevated protein levels were another source of doubt, since this finding suggests of an entity other than GBS. However, we did not find any literature citing the maximum protein levels in GBS and we believe that this value should always be scrutinised closely.

Conflicts of interest

This study has not been presented at any of the SEN's Annual Meetings or any other meeting or congress. It has not received any funding, whether public or private. The authors have no conflicts of interest to declare.

References

- Ortez C, Díaz A. Síndrome de Guillain-Barré en la infancia. *An Pediatr Contin.* 2013;11:98–103.
- Yuki N, Hartung HP. Guillain-Barré syndrome. *N Engl J Med.* 2012;366:2294–304.
- Van den Berg B, Walgaard C, Drenthen J, Fokke C, Jacobs BC, van Doorn PA. Guillain-Barré syndrome: pathogenesis, diagnosis, treatment and prognosis. *Nat Rev Neurol.* 2014;10:469–82.
- González-Suárez I, Sanz-Gallego I, Rodríguez de Rivera FJ, Arpa J. Guillain-Barré syndrome: natural history and prognostic factors: a retrospective review of 106 cases. *BMC Neurol.* 2013;13:95.
- Wilner S, Walker D. Spine and spinal cord tumours: a diagnostic and therapeutic challenge to healthcare systems. *Arch Dis Child Educ Pract Ed.* 2010;95:47–54.
- Arroyo HA. Mielopatías agudas no traumáticas en niños y adolescentes. *Rev Neurol.* 2013;57 Suppl. 1:S129–38.
- Bloch SA, Akhavan M, Avarello J. Weakness and the inability to ambulate in 14-month-old female: a case report and concise review of Guillain-Barre syndrome. *Case Rep Emerg Med.* 2013;1–5, 953612.

P. Molina-Giraldo, A. Ulate-Campos*, J. Petanàs-Argemí, M. Rebollo Polo, V. González-Álvarez

Servicio de Neurología Pediátrica, Hospital Universitario Sant Joan de Déu, Barcelona, Spain

*Corresponding author.

E-mail address: adrianaulate@hotmail.com (A. Ulate-Campos).

Spinal cord ischaemia after endovascular thoracic aneurysm repair[☆]



Isquemia medular tras reparación endovascular de aneurisma torácico

[☆] Please cite this article as: Martínez-Saniger A, López-Herrera-Rodríguez D, Guerrero-Domínguez R, Sánchez-Carrillo F. Isquemia medular tras reparación endovascular de aneurisma torácico. *Neurología.* 2016;31:501–503.

Dear Editor:

Spinal cord ischaemia, the most feared postoperative complication of thoracoabdominal aneurysm repair, is a frequent event with a high morbidity and mortality. Its estimated incidence is between 2.7% and 9.5%.¹ Symptoms vary and may appear in both early and late stages. Recovery may be partial or complete. Postoperative management of spinal cord ischaemia is based on measures favouring spinal cord perfusion, mainly haemodynamic optimisation and drainage of cerebrospinal fluid (CSF).¹

We present the case of a 70-year-old man with a history of arterial hypertension (AHT), type 2 diabetes mellitus,

obstructive sleep apnoea syndrome (OSAS), chronic kidney disease (CKD) associated with vascular nephropathy in the pre-dialysis stage, and secondary hyperparathyroidism. Our patient was admitted for endovascular repair of a 7-cm thoracic aortic aneurysm near the diaphragm. After he was anaesthetised, we attempted to place a catheter at L3-L4 for CSF drainage but did not succeed in doing so due to technical difficulties. Surgery was performed under balanced anaesthesia after canalisation of the right internal jugular vein and the right radial artery; the latter was used for invasive blood pressure monitoring. During surgery, the patient was infused with 2500 mL of crystalloid solution and required perfusion of norepinephrine ($0.05 \mu\text{g}/\text{kg}/\text{min}$) to maintain mean arterial pressure (MAP) around 80 mm Hg. The intervention was conducted without complications; a 10-cm vascular endoprosthesis with 3 stents was placed from the exit of the left subclavian artery, covering the ostium, to the ostium of the celiac trunk. After surgery, the patient was extubated and transferred to the intensive care unit for monitoring. Twenty-four hours after the intervention, our patient experienced sudden-onset symptoms of paraplegia; after a few minutes, he spontaneously recovered movement in the right lower limb but left lower limb monoplegia remained. We ordered an MRI scan to determine whether the complication was haemorrhagic or ischaemic, but the scan was not conducted since the prosthetic device can cause artefacts. We therefore performed a CT scan, which ruled out the presence of epidural haematoma. In view of the radiological findings and the need for rapid action, we performed an additional intervention to place a drainage catheter in the intrathecal space at L4-L5. CSF pressure was 18 mm Hg; 45 mL of CSF were drained in 3 hours. CSF pressure decreased to 11 mm Hg, leading to complete recovery of mobility and strength in the left lower limb.

Acute spinal cord ischaemia is the main suspected diagnosis in cases of sudden onset paraplegia after aortic surgery. Although the prevalence of this complication has decreased in recent years due to the advances in endovascular repair and consequent decline of open surgery, it must not be overlooked. The main risk factors are a stent graft covering ≥ 25 cm, distal aortic repair (T7-L2), and a history of abdominal aortic aneurysm repair.¹⁻³ However, several other significant predictors of spinal cord ischaemia have been described, including preoperative kidney disease (independent factor), occlusion of the subclavian or hypogastric arteries, iliac artery injury, placement of 3 or more stent grafts, AHT, and diabetes.³⁻⁶ Multiple studies have confirmed the effectiveness of drainage to protect the spinal cord in both the preoperative and immediate to late postoperative periods. However, unlike in open surgery, placing a CSF drainage catheter is not a standard measure in endovascular treatment¹; preoperative use of these devices is therefore controversial. Prevention strategies include intraoperative monitoring with somatosensory and motor evoked potentials, CSF drainage if available, and

maintaining haemodynamic stability (PAM >80 mm Hg).²⁻⁴ Likewise, Matsuda et al.² suggest performing CT angiography or MR angiography scans to identify the artery of Adamkiewicz (the longest intercostal artery, which originates at T8-L1 and supplies the spinal arteries). This serves to prevent unnecessary coverage in cases for which distal aortic repair is indicated.

A neurological examination of these patients is essential during the postoperative period, as it enables early response to any focal neurological signs with potentially fatal consequences. If spinal cord ischaemia is suspected, treatment should aim to include CSF drainage when available and maintain a MAP allowing adequate spinal cord perfusion. Rapid placement of a CSF drainage catheter is the intervention best able to treat this devastating complication, and it therefore has a major impact on the prognosis of these patients.

Conflicts of interest

We followed the instructions for authors when preparing this article, which complies with the ethical standards of the journal. All the authors meet the authorship criteria established by the Elsevier Editorial System. This study has received no funding of any kind. The authors have no conflicts of interest to declare. No personal data from patients have been revealed.

References

- Martín Torrijos M, Aguilar Lloret C, Ariño Irujo JJ, Serrano Hernando FJ, López Timoneda F. Paraplejía tardía transitoria tras reparación de aneurismas torácico y toracoabdominal. *Rev Esp Anestesiol Reanim.* 2013;60:528–30.
- Matsuda H, Ogino H, Fukuda T, Iritani O, Sato S, Iba Y, et al. Multidisciplinary approach to prevent spinal cord ischemia after thoracic endovascular aneurysm repair for distal descending aorta. *Ann Thorac Surg.* 2010;90:561–5.
- Fedorow AC, Moon CM, Mutch CA, Grocott PH. Lumbar cerebrospinal fluid drainage for thoracoabdominal aortic surgery: rationale and practical considerations for management. *Anesth Analg.* 2010;111:46–58.
- Ullery WB, Cheung TA, Fairman MR, Jackson MB, Woo Y, Bavaria EJ, et al. Risk factors, outcomes, and clinical manifestations of spinal cord ischemia following thoracic endovascular aortic repair. *J Vasc Surg.* 2011;54:677–84.
- Wong S, Healy C, Canning D, Coffey JC, Boyle RJ, Walsh RS. A systematic review of spinal cord injury and cerebrospinal fluid drainage after thoracic aortic endografting. *J Vasc Surg.* 2012;56:1438–47.
- Keith JC, Passman AM, Carignan JM, Parmar MG, Nagre BS, Patterson AM, et al. Protocol implementation of selective postoperative lumbar spinal drainage after thoracic aortic endograft. *J Vasc Surg.* 2012;55:1–9.

A. Martínez-Saniger*, D. López-Herrera-Rodríguez,
R. Guerrero-Domínguez, F. Sánchez-Carrillo

*Servicio de Anestesiología y Reanimación, Hospital
Universitario Virgen del Rocío, Sevilla, Spain*

*Corresponding author.

E-mail address: ana.martinezsa@gmail.com

(A. Martínez-Saniger).

Binocular vertical diplopia following chemical labyrinthectomy with gentamicin: A case report and review of literature[☆]



Diplopía vertical binocular tras laberintectomía química con gentamicina. A propósito de un caso y revisión de la literatura

Dear Editor:

Chemical labyrinthectomy with gentamicin (CLG) is a minimally-invasive outpatient procedure aiming to achieve high concentrations of the drug in the cochlea with very little systemic dissemination. It is a useful treatment alternative in those patients with Meniere disease (MD) who do not respond to conventional medical treatment. Although vestibular toxicity secondary to CLG is a known adverse effect, visual alterations are rare; there are only 3 published cases of binocular vertical diplopia (BVD) with skew deviation (SD) due to this treatment. We present the fourth case of this complication, a patient with MD who developed BVD after undergoing an initial session of CLG.

Our patient was a 79-year-old woman with a 2-year history of drug-resistant MD in the left ear. She had received an intratympanic gentamicin injection one week previously (30 mg/mL; 0.5 mL). Before receiving the second dose, she reported a 5-day history of gradually progressing symptoms of BVD. In view of the patient's symptoms, her otorhinolaryngologist ordered an urgent neuro-ophthalmologic assessment. The study of extraocular movements revealed right hypertropia with 3 prism dioptres in all eye positions (Fig. 1). All other tests (visual acuity, pupillary light reflex, confrontation visual field exam, saccades and smooth pursuit eye movements, Bielschowsky head-tilting test, Ishihara test, and fundus observation with slit-lamp) yielded normal results. The patient was taking her usual medication, and her vital signs, cognitive state, and clinical examination results were all normal. Despite the above, she was admitted to the neurology department due to possible CNS involvement. Analyses and a brain MRI study did not reveal any relevant results. She was finally discharged and instructed to continue with the treatment she had received during her hospital stay: alternating an eye patch every day and using

prisms. After 8 weeks of follow-up by the neurology and ophthalmology departments, BVD disappeared, confirming the diagnosis of SD due to CLG.

Binocular visual diplopia is a medical emergency that requires immediate neuro-ophthalmologic assessment. SD is considered one of the most frequent causes of BVD (Table 1) as well as the semiological manifestation of damage at the level of the cerebellum or brainstem. However, this clinical manifestation may also be observed in the immediate and late postoperative periods following surgery for unilateral peripheral vestibular disorders.^{1–5} In addition, MD is a chronic disorder of the inner ear that manifests with vertigo, tinnitus, ear fullness, and fluctuating hypacusia. Today, CLG has replaced other invasive treatment options for MD. This treatment destroys the glycoalyx and stops endolymph production.^{4–8} Although numerous studies on CLG have been conducted, there is no consensus on dosing schedules. Weekly dosing plus follow-up hearing tests is an increasingly common approach. Although relatively safe, CLG is also associated with a number of complications,

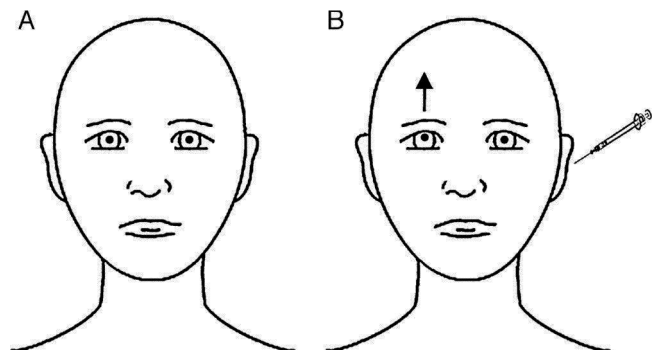


Figure 1 Ocular findings in our patient with her eyes in the primary position, before (A) and immediately after (B) intratympanic gentamicin injection. At baseline, eyes were in their neutral position. After CLG, the patient experienced upward deviation of the visual axis of the right eye, whereas the left eye remained unaltered; called hypertropia, this misalignment of the eyes is present in SD and eventually leads to BVD. Skew deviation is usually caused by supranuclear alterations in the brainstem or the cerebellum. It affects vertical vestibulo-ocular tracts or, at times, the vestibular nerve or vestibular terminal organ (organ of Corti). SD is usually comitant; when incomitant, it may mimic partial paralysis of the third or fourth cranial nerves. The cause is usually vascular ischaemia in the pons or the lateral medulla oblongata (Wallenberg syndrome), probably due to involvement of the vestibular nuclei or their projections. When damage is located in the inferior area of the pons (as in our patient), the ipsilateral eye is undermost (ipsiversive SD), whereas in the case of rostral lesions at the level of the pons, the undermost eye is the contralateral eye (contraversive SD).^{1–3}

[☆] Please cite this article as: León Ruiz M, Izquierdo Esteban L, Parra Santiago A, Benito-León J, Nieto Altuzarra AE, García-Albea Ristol E. Diplopía vertical binocular tras laberintectomía química con gentamicina. A propósito de un caso y revisión de la literatura. *Neurología*. 2016;31:503–505.