

- Chang Y, Lan M, Peng C, Wu H, Chang D, Liu J. Progressive multifocal leukoencephalopathy in an immunocompetent Taiwanese patient. *J Formos Med Assoc.* 2007;106:560–4.
- Christakis PG, Okin D, Huttner AJ, Baehring JM. Progressive multifocal leukoencephalopathy in an immunocompetent patient. *J Neurol Sci.* 2013;326:107–10.
- Bosh J, Sumalla J, Mauleón A, Rovira A, Molins A, Acarin N. Progressive multifocal leukoencephalopathy in elderly immunocompetent patients. Report of 2 cases. *Rev Neurol.* 1999;29:133–7 [in Spanish].
- Johansen KK, Torp SH, Rydland J, Aasly JO. Progressive multifocal leukoencephalopathy in an immunocompetent patient? *Case Rep Neurol.* 2013;5:149–54.
- Gourineni VC, Juvet T, Kumar Y, Bordea D, Sena KN. Progressive multifocal leukoencephalopathy in a 62-year-old

immunocompetent woman. *Case Rep Neurol Med.* 2014;2014:549271.

E. Muiño\*, M.A. Rubio, I. Navalpotro, E. Munteis

*Servicio de Neurología, Hospital del Mar, Parc de Salut Mar, Barcelona, Spain*

\*Corresponding author.

E-mail address: [elena.muinho@gmail.com](mailto:elena.muinho@gmail.com) (E. Muiño).

2173-5808/

© 2015 Sociedad Española de Neurología. Published by Elsevier España, S.L.U. This is an open access article under the CC BY-NC-ND license (<http://creativecommons.org/licenses/by-nc-nd/4.0/>).

## Hyperammonemic encephalopathy associated with multiple myeloma<sup>☆</sup>



### Encefalopatía hiperamoniémica en relación con mieloma múltiple

Dear Editor,

Diffuse encephalopathy is a common reason for in-hospital consultations with the neurology department. The aetiology and level of severity vary greatly from case to case; an accurate diagnosis and appropriate treatment are therefore essential.<sup>1</sup>

Hyperammonaemia may cause encephalopathy in hospital settings. It is associated with a wide range of symptoms, one of the most frequent being liver failure secondary to cirrhosis. Non-hepatic causes of hyperammonaemia in adults include use of such drugs as valproic acid or chemotherapy agents, infection by urease-producing pathogens, a recent history of surgery (ureterosigmoidoscopy, bariatric surgery), presence of a portacaval shunt, high parenteral protein intake, and inborn errors of metabolism (ornithine transcarbamylase or carbamoyl phosphate synthetase I deficiency).<sup>2,3</sup>

In patients with multiple myeloma, encephalopathy is frequently caused by high urea levels in blood, hypercalcaemia, and hyperviscosity. Encephalopathy due to hyperammonaemia is extremely rare; it is associated with high mortality and requires a high level of suspicion and early treatment.<sup>4,5</sup>

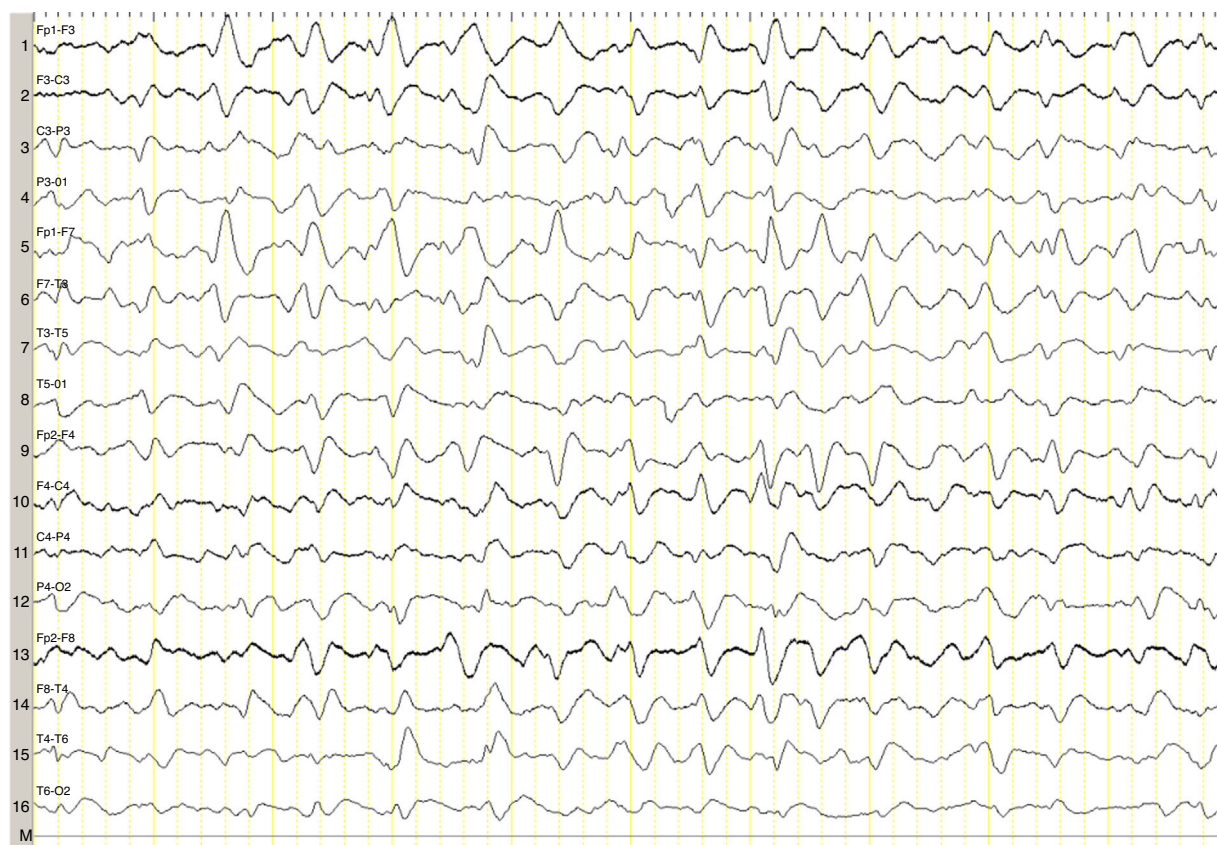
We describe the case of a 82-year-old woman with advanced multiple myeloma associated with a 2-year-history of hypergammaglobulinaemia (IgG-lambda). She was in

her fifth cycle of chemotherapy with lenalidomide and dexamethasone; first-line treatment with melphalan, prednisone, and bortezomib had failed. Our patient presented a month-and-a-half long history of irritability, disorientation, decreased appetite, and drowsiness, and she was therefore admitted to the haematology department. She was assessed in the neurology department due to stupor; she displayed no associated focal neurological signs, fever, or other relevant findings. The results of the liver and coagulation profiles and the levels of creatinine, urea, calcium, and total proteins were normal. Our patient had normocytic normochromic anaemia. Results from the brain CT scan were normal. An emergency EEG revealed generalised, non-reactive slowing of background activity with generalised sharp triphasic waves in the entire EEG trace (Fig. 1). In view of these EEG findings, we requested an ammonia test which revealed high levels of ammonia at 151 µmol/L (reference values 11–51 µmol/L). We initiated anti-encephalopathy measures but new lines of chemotherapy were not authorised by the patient's relatives. Our patient died a month after diagnosis.

Ammonia, a toxic product of protein degradation, is incorporated into urea in the liver and excreted by the kidneys. As ammonia levels increase, it passively diffuses through the blood-brain barrier, exerting a neurotoxic effect. It is incorporated into astrocytes to form glutamine, which results in swollen astrocytes, cortical-subcortical blood flow dysregulation, and cerebral oedema in cases of acute presentation.<sup>6–8</sup> From a clinical viewpoint, these biological changes result in alterations of the level of consciousness of varying degrees of severity. EEG results usually reveal diffuse slowing of brain activity, occasionally accompanied by presence of triphasic waves. Triphasic waves seem to be caused by abnormal activity of the thalamo-cortical circuits<sup>9,10</sup>; however, these waves are a non-specific finding since they appear in a variety of clinical conditions.<sup>11</sup> In our case, presence of triphasic waves in the context of diffuse encephalopathy led us to complete a metabolic study, which revealed high ammonia levels.

The pathophysiology of hyperammonaemia in multiple myeloma is unknown. It has been hypothesised that leukaemia transformation may increase the likelihood of

<sup>☆</sup> Please cite this article as: López-Blanco R, de Fuenmayor-Fernández de la Hoz CP, González de la Aleja J, Martínez-Sánchez P, Ruiz-Morales J. Encefalopatía hiperamoniémica en relación con mieloma múltiple. *Neurología.* 2017;32:339–341.



**Figure 1** 16-Channel EEG showing generalised slowing of background activity with generalised triphasic waves along the entire trace.

hyperammonaemia<sup>12</sup> and plasma cell infiltration of the liver leading to porto-systemic shunting<sup>13</sup>; likewise, metabolising and degrading large quantities of immunoglobulins has been suggested to increase ammonia levels, in excess of the normal rate of hepatic clearance, especially in advanced stages of the disease.<sup>14</sup>

The most frequent subtype of immunoglobulin produced by multiple myeloma seems to be IgG, followed by IgA.<sup>4</sup> Our patient had a subtype of IgG and was in an advanced stage of the disease, with very high levels of ammonia (151  $\mu\text{mol/L}$ ); these findings agree with those reported in the literature.<sup>4,5</sup>

Early diagnosis is essential since prognosis in these patients is poor, and the condition may even be fatal without proper treatment.<sup>4</sup>

In the most comprehensive study to date including patients with acute encephalopathy and triphasic waves, aetiology was found not to affect prognosis; absent EEG background reactivity, on the other hand, did predict a poor outcome,<sup>11</sup> as in our case, although the study did not include patients with hyperammonaemia secondary to myeloma. The role of EEG in these patients is therefore uncertain, although in our case it guided us to perform a metabolic study.

Non-hepatic hyperammonaemia should be considered a potential cause of diffuse encephalopathy in patients with multiple myeloma and exhibiting generalised triphasic waves on EEG, and it requires a different treatment approach.

## Funding

None.

## Conflicts of interest

The authors have no conflicts of interest to declare.

## References

1. Barrero-Hernández FJ, Muñuzuri-Sanz D, Casado-Torres A. A descriptive study of intrahospital neurology service consultations. *Rev Neurol.* 2003;36:1001–4.
2. LaBuzetta JN, Yao JZ, Bourque DL, Zivin J. Adult nonhepatic hyperammonemia: a case report and differential diagnosis. *Am J Med.* 2010;123:885–91.
3. Hawkes ND, Thomas GA, Jurewicz A, Williams OM, Hillier CE, McQueen IN, et al. Non-hepatic hyperammonaemia: an important, potentially reversible cause of encephalopathy. *Postgrad Med J.* 2001;77:717–22.
4. Pham A, Reagan JL, Castillo JJ. Multiple myeloma-induced hyperammonemic encephalopathy: an entity associated with high in-patient mortality. *Leuk Res.* 2013;37:1229–32.
5. Lora-Tamayo J, Palom X, Sarra J, Gasch O, Isern V, Fernandez de Sevilla A, et al. Multiple myeloma and hyperammonemic

- encephalopathy: review of 27 cases. *Clin Lymphoma Myeloma*. 2008;8:363–9.
6. Felipe V, Butterworth RF. Neurobiology of ammonia. *Prog Neurobiol*. 2002;67:259–79.
  7. Rao KV, Norenberg MD. Cerebral energy metabolism in hepatic encephalopathy and hyperammonemia. *Metab Brain Dis*. 2001;16:67–78.
  8. Haack N, Dublin P, Rose CR. Dysbalance of astrocyte calcium under hyperammonemic conditions. *PLOS ONE*. 2014;9:e105832.
  9. Karnaze DS, Bickford RG. Triphasic waves: a reassessment of their significance. *Electroencephalogr Clin Neurophysiol*. 1984;57:193–8.
  10. Kwon OY, Jung KY, Park KJ, Kang JK, Shon YM, Lee IK, et al. Source localization of triphasic waves: implications for the pathophysiological mechanism. *Clin EEG Neurosci*. 2007;38:161–7.
  11. Sutter R, Stevens RD, Kaplan PW. Significance of triphasic waves in patients with acute encephalopathy: a nine-year cohort study. *Clin Neurophysiol*. 2013;124:1952–8.
  12. Ikewaki J, Ogata M, Imamura T, Kohno K, Nakayama T, Kadota J. Development of hyperammonemic encephalopathy in patients with multiple myeloma may be associated with the appearance of peripheral blood myeloma cells. *Leuk Lymphoma*. 2009;50:667–9.
  13. Howman R, Thakerer A, Pitman M, Ding N, Thompson PA, Khot A, et al. Bortezomib, cyclophosphamide, and dexamethasone: highly effective for rapid reversal of myeloma-associated hyperammonemic encephalopathy. *Leuk Lymphoma*. 2010;51:2299–302.
  14. Otsuki T, Yamada O, Sakaguchi H, Ichiki T, Kouguchi K, Wada H, et al. In vitro excess ammonia production in human myeloma cell lines. *Leukemia*. 1998;12:1149–58.
- R. López-Blanco<sup>a,\*</sup>,  
C.P. de Fuenmayor-Fernández de la Hoz<sup>a</sup>,  
J. González de la Aleja<sup>a,b</sup>, P. Martínez-Sánchez<sup>c</sup>,  
J. Ruiz-Morales<sup>a</sup>
- <sup>a</sup> *Servicio de Neurología, Hospital Universitario 12 de Octubre, Madrid, Spain*  
<sup>b</sup> *Sección EEG-Epilepsia, Hospital Universitario 12 de Octubre, Madrid, Spain*  
<sup>c</sup> *Servicio de Hematología, Hospital Universitario 12 de Octubre, Madrid, Spain*
- \* Corresponding author.  
*E-mail address:* [robretolb@gmail.com](mailto:robretolb@gmail.com) (R. López-Blanco).  
2173-5808/  
© 2015 Sociedad Española de Neurología. Published by Elsevier España, S.L.U. This is an open access article under the CC BY-NC-ND license (<http://creativecommons.org/licenses/by-nc-nd/4.0/>).

## Differences between chronic migraine with and without medication overuse<sup>☆</sup>



## Diferencias entre migraña crónica con y sin uso excesivo de medicación

Dear Editor:

I read with great interest the outstanding article by Rojo et al.<sup>1</sup> analysing the differences between patients with chronic migraine (CM) with and without medication overuse (MO). According to this study, only 57% of these patients had received preventive treatment with the most frequent type being antidepressants; most patients had received only one type of preventive treatment. These findings should encourage self-criticism among general practitioners and neurologists alike regarding the way we manage migraine. This entity constitutes the main reason for neurology consultations in Spain, and it has been ranked eighth by the WHO in terms of impact on activities of daily living.<sup>2</sup>

<sup>☆</sup> Please cite this article as: Pascual J. Diferencias entre migraña crónica con y sin uso excesivo de medicación. *Neurología*. 2017;32:341–342.

Except for longer progression times, Rojo et al. found no differences between these 2 subgroups of patients with CM. This suggests that: (1) CM with and without MO are not separate entities, and (2) in most cases, MO is the consequence of CM, rather than the cause. Departing from the conventional wisdom that the vast majority of patients with CM meet criteria for MO, the above study reports that just over half of the patients with CM (258 out of 434, that is, 59.5%, not 72.2% as cited in the abstract [a considerable percentage by any standards]) met the criteria for MO, confirming once more that MO is not a necessary condition for migraine chronification.

## Conflicts of interest

The author has no conflicts of interest to declare.

## References

1. Rojo E, Pedraza MI, Muñoz I, Mulero P, Ruiz M, de la Cruz C, et al. Diferencias entre migraña crónica con y sin uso excesivo de medicación; experiencia en una serie hospitalaria de 434 pacientes. *Neurología*. 2015;30:158–62.
2. Vos T, Flaxman AD, Naghavi M, Lozano R, Michaud C, Ezzati M, et al. Years lived with disability (YLDs) for 1160 sequelae of 289 diseases and injuries 1990–2010: a systematic analysis for the Global Burden of Disease Study 2010. *Lancet*. 2012;380:2163–96.