

Conflicts of interest

The authors have no conflicts of interest to declare.

References

- Hamada T, McLean WH, Ramsay M, Ashton GH, Nanda A, Jenkins T, et al. Lipoid proteinosis maps to 1q21 and is caused by mutations in the extracellular matrix protein 1 gene (EMC1). *Hum Mol Genet.* 2002;11:833–40.
- Aroni K, Lazaris AC, Papadimitriou K, Paraskevaki H, Davaris PS. Lipoid proteinosis of the oral mucosa: case report and review of the literature. *Pathol Res Pract.* 1998;194:844–59.
- Cote DN. Head and neck manifestations of lipoid proteinosis. *Otolaryngol Head Neck Surg.* 1998;119:144–5.
- Heyl T. Geological study of lipoid proteinosis in South Africa. *Br J Dermatol.* 1970;83:338–40.
- Hofer PA. Urbach-Wiethe disease (lipoglycoproteinosis; lipoid proteinosis; hyalinosis cutis et mucosae): a review. *Acta Dermatol Venereol.* 1973;53 Suppl. 71:1–52.
- Van Houghehouck-Tulleken W, Chan I, Hamada T, Thornton H, Jenkins T, McLean WHI, et al. Clinical and molecular characterization of lipoid proteinosis in Namaqualand, South Africa. *Br J Dermatol.* 2004;151:413–23.
- Acar A, Eryilmaz A, Gocer C, Akmansu H, Korkmaz H. Lipoid proteinosis of larynx: review of four cases. *Int J Pediatr Otorhinolaryngol.* 2004;68:1557–61.
- Hamada T, Wessagowit V, South AP, Ashton GH, Chan I, Oyama N, et al. Extracellular matrix protein 1 gene (ECM1) mutations in lipoid proteinosis and genotype-phenotype correlation. *J Invest Dermatol.* 2003;120:345–50.
- Chan I, Liu L, Hamada T, Sethuraman G, McGrath JA. The molecular basis of lipoid proteinosis: mutations in extracellular matrix protein 1. *Exp Dermatol.* 2007;16:881–90.
- Savage MM, Crockett DM, McCabe BF. Lipoid proteinosis of the larynx: a cause of voice change in the infant and young child. *Int J Pediatr Otol.* 1988;15:33–8.
- Urbach E, Wiethe C. Lipoidosis cutis et mucosae. *Wirsch Arch Pathol Anat.* 1929;273:285–319.
- Staut CCV. Lipoid proteinosis. CT and MRI features. *Int J Neuro-radiol.* 1998;4:199–207.
- Hamada T. Lipoid proteinosis. *Clin Exp Dermatol.* 2002;27:624–9.
- Mondejar R, García-Moreno JM, Rubio F, Solano F, et al. Clinical and molecular study of the extracellular matrix protein 1 gene in a Spanish family with lipoid proteinosis. *J Clin Neurol.* 2014;10:64–8.

J. Abril-Jaramillo^{a,*}, R. Mondéjar^b, M. Lucas^c,
B. García-Bravo^d, J.J. Ríos-Martin^e, J.M. García-Moreno^{a,f}

^a Servicio de Neurología, H. Virgen Macarena, Sevilla, Spain

^b Servicio de Bioquímica, H. Virgen Macarena, Sevilla, Spain

^c Servicio de Biología Molecular, H. Virgen Macarena, Sevilla, Spain

^d Servicio de Dermatología, H. Virgen Macarena, Sevilla, Spain

^e Servicio de Anatomía Patológica, H. Virgen Macarena, Sevilla, Spain

^f Asociación Neuroinvest, Sevilla, Spain

*Corresponding author.

E-mail addresses: javierabriljaramillo@gmail.com,
nusame@gmail.com (J. Abril-Jaramillo).

2173-5808/

© 2015 Sociedad Española de Neurología. Published by Elsevier España, S.L.U. This is an open access article under the CC BY-NC-ND license (<http://creativecommons.org/licenses/by-nc-nd/4.0/>).

Multiple vascular malformations in a patient with microcephalic osteodysplastic primordial dwarfism type II[☆]



Múltiples malformaciones vasculares en un paciente con enanismo primordial osteodisplásico microcefálico tipo II

Dear Editor:

Microcephalic osteodysplastic primordial dwarfism (MOPD) is a syndrome characterised by intrauterine growth retardation, impaired postnatal growth, microcephaly, and a

phenotype similar to that of Seckel syndrome.¹ MOPD type II, the most distinctive type of MOPD, is a rare disorder with a recessive autosomal inheritance pattern. We recently published the case of a Colombian carrier of a new mutation of the *PCNT* gene with a nucleotide change in exon 10, c.1468C>T, resulting in a premature stop codon at amino acid position 490, p.Q490X, which is predicted to generate a truncated protein.²

When the case was reported, the patient was 5; he was extremely small (below the third percentile for his age), with delayed psychomotor development and microcephaly, downward-slanting palpebral fissure, a prominent nose, amelogenesis imperfecta, ulnar deviation, a high narrow pelvis, unusually short arms and legs, coxa vara, a high-pitched voice, and an outgoing personality.² Complementary tests performed when he was 4 included a simple brain CT scan and an angiography. The CT scan showed no alterations in the fourth ventricle and posterior fossa, closure of the metopic and sagittal sutures, and permeability of the coronal and lambdoid sutures, whereas the angiography revealed no aneurysms or signs of moyamoya disease. We requested a molecular study to confirm the diagnosis.

[☆] Please cite this article as: Ruiz-Botero F, Pachajoa H. Múltiples malformaciones vasculares en un paciente con enanismo primordial osteodisplásico microcefálico tipo II. *Neurología.* 2017;32:127–129.

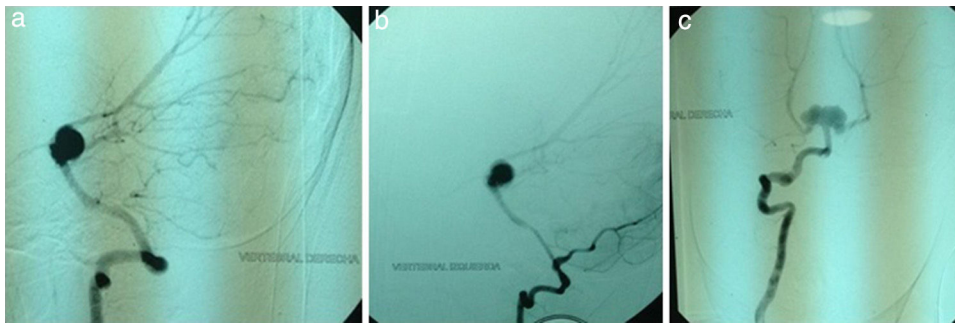


Figure 1 (a) Right vertebral artery. (b) Left vertebral artery. (c) Right vertebral artery and basilar artery. Note the presence of an aneurysm measuring 13 mm in the apex of the basilar artery which compromises the origin of both posterior cerebral arteries.

At the age of 7 (present), our patient experienced an episode of sudden headache associated with nausea, vomiting, seizures, loss of consciousness, and motor deficits. A brain CT scan displayed subarachnoid haemorrhage. An angiography study revealed infundibular dilation of the posterior communicating artery at the level of the left internal carotid artery, a transitional aneurysm in the left carotid artery measuring 3 mm, an infundibular dilation of the posterior communicating artery at the level of the right internal carotid artery, and an aneurysm measuring 13 mm at the apex of the basilar artery with clear signs of trilobular rupture compromising the origin of both posterior cerebral arteries (Fig. 1A–C). Although endovascular treatment achieved mild improvements in the patient's level of consciousness, quadriplegia and severe speech impairment persisted.

Vascular malformations in moyamoya disease and multiple aneurysms have been associated with various genetic disorders, especially MOPD type II. Hall et al.³ found aneurysms or moyamoya disease in 11 patients of a cohort of 58 (19%). Brancati et al.⁴ documented presence of these abnormalities in 15 of 63 patients (23.8%) and Bober et al.⁵ in 13 of 25 patients (52%). In these studies, cerebrovascular anomalies were more frequent in males.^{3–5} However, questions remain as to whether female sex has a protective effect or if instead male sex increases the risk of presenting these alterations.⁵

Neurological impairment secondary to cerebrovascular alterations results in a wide range of sequelae, from residual dysphasia to sudden death.^{3–5} In the study by Brancati et al.,⁴ patients with moyamoya disease were found to have cerebrovascular alterations at younger ages; patients with intracranial aneurysms in the posterior cerebral arteries, on the other hand, had a poorer prognosis due to severe chronic hypertension and dilated myocardiopathy.⁴

Diagnosis of multiple aneurysms and/or moyamoya disease is especially difficult in patients with MOPD type II due to the associated anatomical alterations, such as an unusually small vascular system and abnormally tortuous arteries.⁶ Given the close relationship between MOPD type II and cerebrovascular alterations, our case underscores the importance of conducting MRI or angiography screening tests annually in these patients to prevent potentially disabling or fatal events,⁵ enable early treatment, reduce surgery-

related complications, and increase patients' survival and quality of life. Patients with symptoms suggestive of MOPD or a diagnosis of MOPD confirmed by genetic studies should undergo routine angio-MRI studies to rule out aneurysms or moyamoya disease.

Funding

This study has received funding from the Congenital Anomalies and Rare Diseases Research Centre (CIACER) at Universidad Icesi, Colombia.

Conflicts of interest

The authors have no conflicts of interest to declare.

References

1. Bober MB, Niiler T, Duker AL, Murray JE, Ketterer T, Harley ME, et al. Growth in individuals with Majewski osteodysplastic primordial dwarfism type II caused by Pericentrin mutations. *Am J Med Genet Part A.* 2012;158A:2719–25.
2. Pachajoa H, Ruiz-Botero F, Isaza C. A new mutation of the PCNT gene in a Colombian patient with microcephalic osteodysplastic primordial dwarfism type II: a case report. *J Med Case Rep.* 2014;8:191.
3. Hall J, Flora C, Scott C, Pauli R, Tanaka K. Majewski osteodysplastic primordial dwarfism type II (MOPD II): natural history and clinical findings. *Am J Med Genet Part A.* 2004;130A:55–72.
4. Brancati F, Castori M, Mingarelli R, Dallapiccola B. Majewski osteodysplastic primordial dwarfism type II (MOPD II) complicated by stroke: clinical report and review of cerebral vascular anomalies. *Am J Med Genet Part A.* 2005;139A:212–5.
5. Bober MB, Khan N, Kaplan J, Lewis K, Feinstein JA, Scott CI Jr, et al. Majewski osteodysplastic primordial dwarfism type II (MOPD II): expanding the vascular phenotype. *Am J Med Genet Part A.* 2010;152A:960–5.
6. Waldron JS, Hetts SW, Armstrong-Wells J, Dowd CF, Fullerton HJ, Gupta N, et al. Multiple intracranial aneurysms and moyamoya disease associated with microcephalic osteodysplastic primordial dwarfism type II: surgical considerations. *J Neurosurg Pediatr.* 2009;4:439–44.

F. Ruiz-Botero*, H. Pachajoa

Facultad de Ciencias de la Salud Universidad Icesi, Grupo Biomédica, Centro de investigación en anomalías congénitas y enfermedades raras, Cali, Colombia

*Corresponding author.

E-mail address: Fruiz@icesi.edu.co (F. Ruiz-Botero).

2173-5808/

© 2014 Sociedad Española de Neurología. Published by Elsevier España, S.L.U. This is an open access article under the CC BY-NC-ND license (<http://creativecommons.org/licenses/by-nc-nd/4.0/>).

Optic neuritis following Epstein-Barr virus encephalitis in immunocompetent children: A case report[☆]



Neuritis óptica postencefalitis por virus de Epstein-Barr en niños inmunocompetentes. Caso clínico

Dear Editor,

Epstein-Barr virus (EBV) infections are very frequent in paediatric patients. The main clinical manifestation is infectious mononucleosis (IM).^{1,2} The age of primary infection varies between different regions: in developed countries, between 80% and 100% of all affected children are aged 3 to 6 years old, and most of them are asymptomatic.¹ Once the primary infection has occurred, the virus will remain latent in the human host for life.^{1,2}

In children and adolescents, IM is typically associated with such symptoms as fever, fatigue, general unease, acute pharyngitis, lymphadenopathy, and hepatosplenomegaly. In immunocompetent patients, IM is usually self-limiting and rarely associated with complications.^{1,2} Around 1% to 18% of patients with IM experience neurological complications; these are more frequent in the acute stage of the disease and rare in the final stage.¹⁻³

In paediatric patients, IM may present with central nervous system involvement (aseptic meningitis, meningoencephalitis, and encephalitis) either as the sole symptom of the disease or before the disease itself develops. Therefore, EBV infection must be regarded as a potential cause of acute meningitis regardless of its associated symptoms.^{1,4-7} However, other complications have also been described: cerebellitis, cranial nerve palsy, optic neuritis, Guillain-Barré syndrome, hemiplegia, and transverse myelitis.^{1,3}

We present the case of a healthy 6-year-old patient with a 20-day history of fever. She was initially diagnosed with pharyngo- and gingivostomatitis. The patient had persistent headache, photophobia, excessive

somnolence, and gait abnormalities. She had a normal level of consciousness, generalised hyperreflexia, cerebellar ataxia, and no meningeal signs. A laboratory test revealed leukocytosis (25 300 leukocytes/mm³; 60% neutrophils) with no activated lymphocytes and no heterophile antibodies (Paul-Bunnell test). A CSF cytochemical test showed 20 red blood cells/mm³, 40 leukocytes/mm³ (60% polymorphonuclear), glucose level of 0.45 g/L, and a total protein level of 0.46 g/L. The bacteriological study revealed no abnormalities. Polymerase chain reaction (PCR) testing was positive for EBV and negative for enterovirus and herpesviruses 1, 2, and 6. A cranial CT scan revealed no abnormalities and the EEG displayed diffuse cortical and periodic subcortical activity. A brain MRI scan revealed T2-weighted and FLAIR hyperintensities at the level of the thalamus, midbrain, and cerebellum. No contrast uptake or diffusion restriction was seen (Figs. 1 and 2).

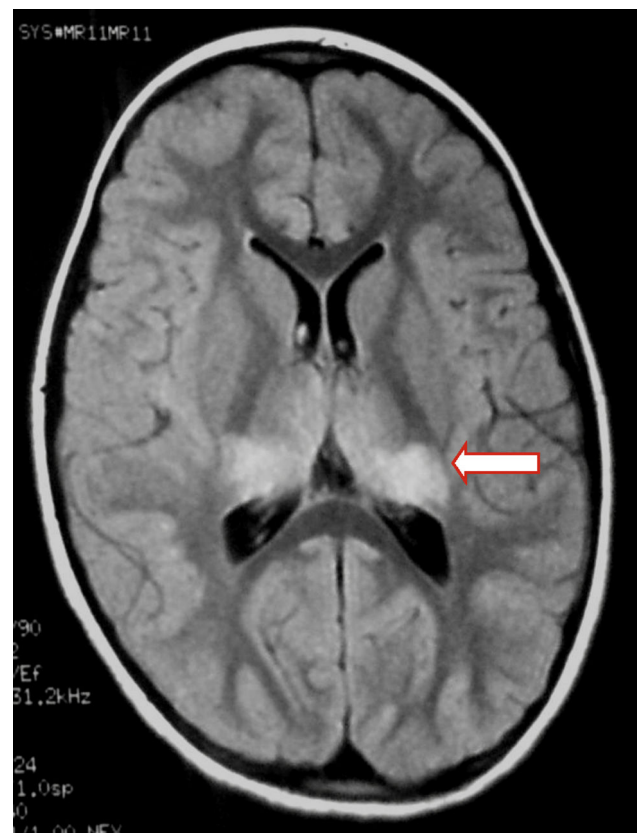

Figure 1 Axial FLAIR MR image: bilateral thalamic hyperintensities.

[☆] Please cite this article as: Bazzino Rubio F, Gonzalez Betlza M, Gonzalez Rabelino G, Bello Pedrosa O. Neuritis óptica postencefalitis por virus de Epstein-Barr en niños inmunocompetentes. Caso clínico. *Neurología*. 2017;32:129–131.