




SOCIEDAD ESPAÑOLA  
DE NEUROLOGÍA

# NEUROLOGÍA

[www.elsevier.es/neurologia](http://www.elsevier.es/neurologia)



## LETTERS TO THE EDITOR

### Recurrent dural arteriovenous fistulas in a patient with Behçet's disease<sup>☆</sup>



### Fístulas arteriovenosas durales recurrentes en paciente con enfermedad de Behçet

Dear Editor:

Behçet disease (BD) is a recurrent multisystemic inflammatory disease of unknown aetiology, with greater prevalence in Asian countries. The condition has been associated with specific histocompatibility antigens (HLAs) such as B5, B27, B56, and A26, while *HLA-B\*49* and *HLA-B\*03* are considered to be protective alleles.<sup>1</sup> The autoimmune basis of the disease is currently subject to debate: although the disease has been associated with specific antibodies, their role in pathogenesis is controversial, with some authors considering it to be an autoinflammatory disease.<sup>2</sup> Other features of BD are its peculiar geographic distribution along the former Silk Road between the Mediterranean and East Asia, and the varying prevalence of different clinical manifestations according to patients' ethnicity.<sup>3</sup> Neurological manifestations of BD, or neuro-Behçet disease (NBD), are present in only 5%-10% of patients.<sup>4,5</sup> NBD can feature parenchymal (80% of cases) or non-parenchymal involvement.<sup>6</sup> Non-parenchymal NBD affects vascular structures, with cerebral venous thrombosis (CVT) being the most frequent complication. Arteriovenous fistulae (AVF) are rare and have previously been described in the retina.<sup>7</sup> We present the case of a 37-year-old patient with dural AVFs (DAVF) secondary to CVT as the initial neurological manifestation of BD.

### Clinical case

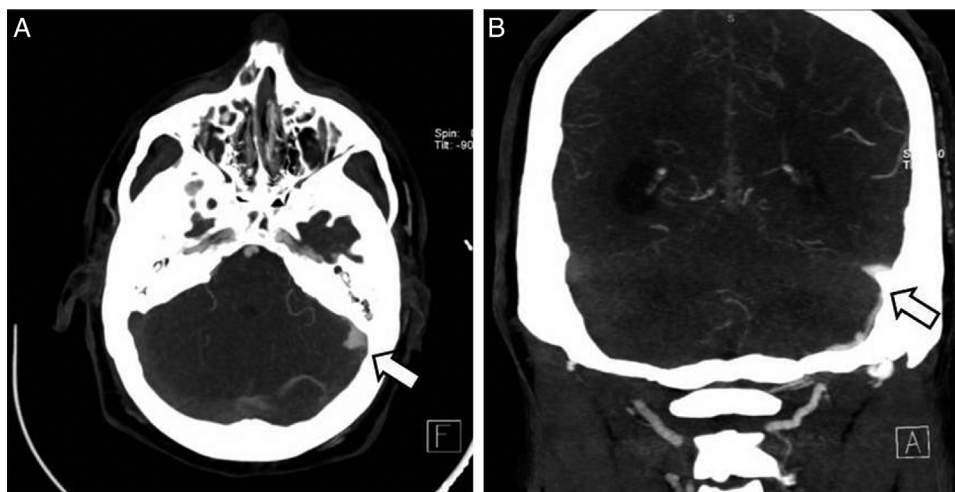
The patient was a 37-year-old man who came to our hospital with subacute-onset headache, transient hypoaesthesia of the left arm, and sudden loss of consciousness. A brain CT scan revealed a right frontal focal subarach-

noid haemorrhage (Fig. 1); however, a CT-angiography and arteriographic study found no abnormalities. Six months later, the patient returned to our centre after experiencing an episode of headache and dizziness. Another CT-angiography was performed, revealing anomalous vascular structures in the posterior fossa and an irregularity in the sigmoid sinus, accompanied by engorged branches of the external carotid artery (Fig. 1). A new cerebral arteriography showed the presence of 2 DAVFs: one in the posterior fossa, fed by the internal and external carotid arteries and with venous drainage through the sigmoid and transverse sinuses and cortical veins (type II a+b in the Cognard classification)<sup>8</sup>; and the other in the superior sagittal sinus, fed by the left meningeal artery, with cortical venous reflux (Cognard type III) (Fig. 2). A brain MRI with venography displayed thrombosis of the left transverse sinus.

The patient had a history of mouth ulcers and folliculitis. He reported no history of ocular pathology or genital ulcers; a pathergy test and coagulation study returned negative results. Positive results were found for histocompatibility antigen HLA-B51. BD was diagnosed according to the criteria established by the International Team for the Revision of the International Criteria for Behçet's Disease (ITR-ICBD).<sup>4</sup>

The Cognard classification distinguishes 5 types of DAVF according to drainage pattern, assisting physicians in assessing the risk of complication and in making treatment decisions. According to this classification, type II a+b and type III DAVFs, the types observed in our patient, present a high risk of bleeding.<sup>8</sup> We therefore decided to occlude the DAVFs using Onyx<sup>®</sup>, a liquid embolic agent, combined with immunotherapy consisting of colchicine and low doses of prednisone and azathioprine. It was initially decided not to begin thrombolytic treatment due to the high risk of cerebral haemorrhagic complication. The patient's only systemic symptom in the following months was occasional mouth ulcers. A year later, he experienced recurring intense headache and tinnitus in the right ear. An MRI with venography and an arteriographic study were performed. These showed another large DAVF with 2 components: one in the torcula, with associated cortical venous drainage (Cognard type II a+b); and another affecting the right sigmoid and transverse sinuses, fed by branches of the right internal carotid artery (Cognard type I). These were successfully treated. We suspected that the recurring DAVFs were secondary to a chronic, non-recanalised CVT and decided to begin oral anticoagulant treatment in order to achieve an international normalised ratio score between 2 and 3. Azathioprine dose was doubled.

<sup>☆</sup> Please cite this article as: Falgàs N, Borrego S, Llull L, Espinosa G, López-Rueda A, Blasco J, et al. Fístulas arteriovenosas durales recurrentes en paciente con enfermedad de Behçet. *Neurología*. 2017;32:623–626.



**Figure 1** CT-angiography showed arterialisation of the left sigmoid sinus (A) and engorgement of branches of the left external carotid artery (B).

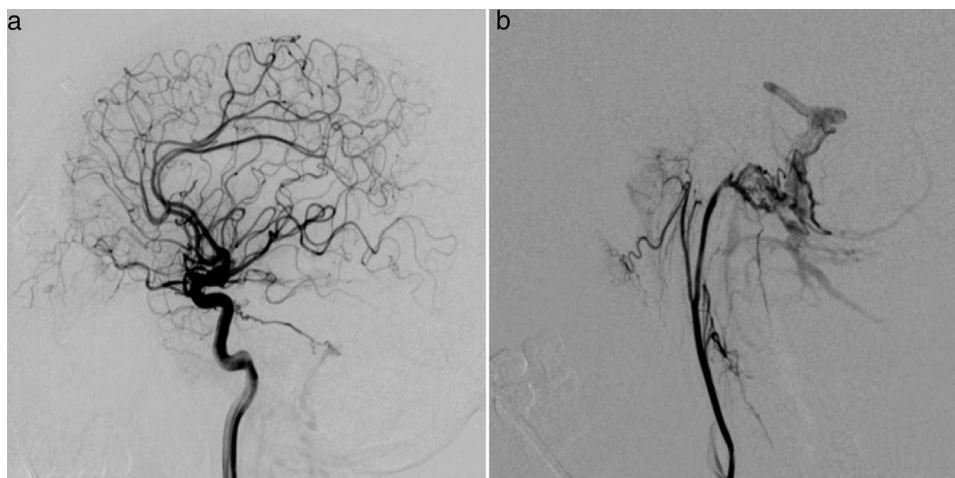
The patient did not present deep vein thrombosis or other vascular symptoms and remained radiologically stable during clinical follow-up of the anticoagulant treatment (8 months).

## Discussion

CVT is the most common vascular complication in BD, accounting for 18% of NBD cases<sup>9</sup>; it occurs in approximately 8% of all patients with BD.<sup>10</sup> Some authors have described specific characteristics of CVT in these patients, with a higher frequency of chronic or subacute course,<sup>11</sup> greater involvement of the sagittal and transverse sinuses,<sup>12,13</sup> and more favourable prognosis.<sup>11</sup> The pathogenesis of throm-

bus formation in BD remains unknown; its high incidence in this condition is not explained by classic thrombotic factors.<sup>14</sup>

Regarding coagulation, many studies have attempted to identify specific disorders in some process or reaction in the coagulation cascade, such as protein C, protein S, high thrombomodulin concentrations, and alterations affecting antithrombin function and various levels of plasmatic fibrinolysis (both the activator [tissue plasminogen activator; t-PA] and the inhibitor [type I t-PA inhibitor]).<sup>14</sup> Findings have been contradictory, however; this is probably due to a selection bias (patients in the active and inactive phase of the disease), methodological differences in laboratory testing, or due to the differing ethnicities of patients, as is the case with the roles that factor V Leiden and prothrombin gene mutation G20210A may play in thrombosis.<sup>15</sup> Other, less



**Figure 2** Arteriography revealed a DAVF in the posterior fossa, fed by the interior (a) and exterior (b) carotid arteries, with venous drainage through the transverse and sigmoid sinuses and cortical veins (Cognard II a + 2).

frequent, forms of neurovascular involvement in BD include arterial dissections, arterial thrombosis, intracranial haemorrhage, and cerebral aneurysm.

DAVFs are a series of heterogeneous conditions, all of which involve arteriovenous shunts, or connections, between dural vessels. They represent 10%-15% of all vascular malformations with shunts.<sup>16</sup> According to our literature search, DAVFs associated with BD have been described only once.<sup>17</sup> In that case, the first neurological manifestation of the disease was focal subarachnoid haemorrhage, probably related to a cortical venous thrombosis. We interpreted our patient's DAVF as being the consequence of high vascular resistance caused by a chronic, non-recanalised CVT.

Regarding treatment of thrombosis in BD, no recommendations are available with respect to long-term anticoagulant treatment.<sup>18</sup> On the one hand, it is essential to consider the potential for co-presence of arterial aneurysms and the associated haemorrhagic risk.<sup>19</sup> On the other hand, the presence of an underlying inflammatory process causing the thrombus to adhere to the vascular wall<sup>20</sup> has led many experts to consider only immunosuppressive treatment and not anticoagulation. A study including 64 patients with BD and CVT, 62 (96%) of whom were treated with anticoagulants, found that anticoagulants are safe and effective for these patients, and that immunosuppression had no additional benefit.<sup>13</sup> However, a recent international expert consensus was unable to make a definitive recommendation on long-term anticoagulation/immunosuppression in patients with CVT and BD.<sup>6</sup> In cases where the condition is recurrent or refractory to conventional treatment, physicians should consider biological treatment, particularly anti-TNF agents and interferon alpha. Despite having been shown to be very effective in patients with ocular or mucocutaneous manifestations of BD, the effectiveness of these drugs in patients with vascular involvement is currently only anecdotal; decisions should therefore be made case-by-case.<sup>21</sup>

Ours is the second published case of DAVF manifesting in the context of BD, presumably associated with chronic CVT. This complication may be the only manifestation of a silent CVT; treatment should be modified if it is detected.

## Conflicts of interest

None.

## References

1. Takeuchi M, Kastner DL, Remmers EF. The immunogenetics of Behçet's disease: a comprehensive review. *J Autoimmun.* 2015;64:137–48.
2. Yazici H, Fresko I. Behçet's disease and other autoinflammatory conditions: what's in a name? *Clin Exp Rheumatol.* 2005;23 Suppl. 38:S1–2.
3. Davatchi F, Shahram F, Chams-Davatchi C. Behçet's disease: from east to west. *Clin Rheumatol.* 2010;29:823–33.
4. International Team for the Revision of the International Criteria for Behçet's Disease (ITR-ICBD). The International Criteria for Behçet's Disease (ICBD): a collaborative study of 27 countries on the sensitivity and specificity of the new criteria. *J Eur Acad Dermatol Venereol.* 2014;28:338–47.
5. Rodríguez-Carballeira M, Alba MA, Solans-Laqué R, Castillo MJ, Ríos-Fernández R, Larrañaga JR, et al., on behalf of the REGEB investigators. Registry of the Spanish network of Behçet's disease: a descriptive analysis of 496 patients. *Clin Exp Rheumatol.* 2014;32 Suppl. 84:S33–9.
6. Kalra S, Silman A, Akman-Demir G, Bohlega S, Borhani-Haghighi A, Constantinescu CS, et al. Diagnosis and management of Neuro-Behçet's disease: international consensus recommendations. *J Neurol.* 2014;261:1662–76.
7. Tanaka T, Muraoka K, Tokui K. Retinal arteriovenous shunt at the arteriovenous crossing. *Ophthalmology.* 1998;105:1251–8.
8. Cognard C, Gobin YP, Pierot L, Bailly AL, Houdart E, Casasco A, et al. Cerebral dural arteriovenous fistulas: clinical and angiographic correlation with a revised classification of venous drainage. *Radiology.* 1995;194:671–80.
9. Al-Araji A, Kidd DP. Neuro-Behçet's disease: epidemiology, clinical characteristics, and management. *Lancet Neurol.* 2009;8:192–204.
10. Koc Y, Güllü I, Akpek G, Akpolat T, Kansu E, Kiraz S, et al. Vascular involvement in Behçet's disease. *J Rheumatol.* 1992;19:402–10.
11. Yesilot N, Bahar S, Yilmazer S, Mutlu M, Kurtuncu M, Tunçay R, et al. Cerebral venous thrombosis in Behçet's disease compared to those associated with other etiologies. *J Neurol.* 2009;256:1134–42.
12. Saadoun D, Wechsler B, Resche-Rigon M, Trad S, Le Thi Huong D, Sbai A, et al. Cerebral venous thrombosis in Behçet's disease. *Arthritis Rheum.* 2009;61:518–26.
13. Aguiar de Sousa D, Mestre T, Ferro JM. Cerebral venous thrombosis in Behçet's disease: a systematic review. *J Neurol.* 2011;258:719–27.
14. Espinosa G, Font J, Tàssies D, Vidaller A, Deulofeu R, López-Soto A, et al. Vascular involvement in Behçet's disease: relation with thrombophilic factors, coagulation activation, and thrombomodulin. *Am J Med.* 2002;112:37–43.
15. Chamorro A-J, Marcos M, Hernández-García I, Calvo A, Mejía J-C, Cervera R, et al. Association of allelic variants of factor v Leiden, prothrombin and methylenetetrahydrofolate reductase with thrombosis or ocular involvement in Behçet's disease: a systematic review and meta-analysis. *Autoimmun Rev.* 2013;12:607–16.
16. Gandhi D, Chen J, Pearl M, Huang J, Gemmete JJ, Kathuria S. Intracranial dural arteriovenous fistulas: classification, imaging findings, and treatment. *AJNR Am J Neuroradiol.* 2012;33:1007–13.
17. Imaizumi M, Nukada T, Yoneda S, Abe H. Behçet's disease with sinus thrombosis and arteriovenous malformation in brain. *J Neurol.* 1980;222:215–8.
18. Hatemi G, Silman A, Bang D, Bodaghi B, Chamberlain AM, Gul A, et al. Management of Behçet's disease: a systematic literature review for the EULAR evidence based recommendations for the management of Behçet's disease. *Ann Rheum Dis.* 2008;67:1656–62.
19. Calamia KT, Schirmer M, Melikoglu M. Major vessel involvement in Behçet's disease: an update. *Curr Opin Rheumatol.* 2011;23:24–31.
20. Seyahi E, Yurrdakul S. Behçet's syndrome and thrombosis. *Mediterr J Hematol Infect Dis.* 2011;3:e2011026.
21. Sfrikakis PP. Behçet's disease: a new target for anti-tumour necrosis factor treatment. *Ann Rheum Dis.* 2002;61 Suppl. 2:ii51–3.

N. Falgàs<sup>a</sup>, S. Borrego<sup>a</sup>, L. Llull<sup>a,\*</sup>, G. Espinosa<sup>b</sup>,  
A. López-Rueda<sup>c</sup>, J. Blasco<sup>c</sup>, A. Cervera<sup>d</sup>

<sup>a</sup> Servicio de Neurología, Hospital Clínic, Barcelona, Spain

<sup>b</sup> Servicio de Enfermedades Autoinmunes, Hospital Clínic, Barcelona, Spain

<sup>c</sup> Servicio de Radiología, Hospital Clínic, Barcelona, Spain

<sup>d</sup> Neurology Service, Southmead Hospital, North Bristol NHS Trust, Bristol, United Kingdom

\* Corresponding author.

E-mail address: [blull@clinic.ub.es](mailto:blull@clinic.ub.es) (L. Llull).

2173-5808/

© 2015 Sociedad Española de Neurología. Published by Elsevier España, S.L.U. This is an open access article under the CC BY-NC-ND license (<http://creativecommons.org/licenses/by-nc-nd/4.0/>).

## Hereditary neuropathy with liability to pressure palsy presenting as a bilateral brachial plexopathy<sup>☆</sup>



### Plexopatía braquial bilateral como forma de presentación de la neuropatía hereditaria con parálisis sensible a la presión

Dear Editor:

Hereditary neuropathy with liability to pressure palsies (HNPP) is a rare, autosomal dominant disease affecting peripheral myelin, which manifests as recurrent, and usually transient, painless motor and/or sensory neuropathies.<sup>1-3</sup> Neuropathies are triggered by minor trauma or repetitive movements with compression and traction of peripheral nerves. The most frequent forms of presentation affect the peroneal and the ulnar nerves. Brachial plexopathy occurs in 11%-20% of the cases over the natural course of the disease, but it is an unusual clinical manifestation; bilateral presentation is even rarer.<sup>1,2</sup> We present the clinical case of a patient with HNPP presenting as a bilateral brachial plexopathy.

Our patient was a 22-year-old man with no relevant personal or family history who was transferred to our department due to proximal weakness of the left arm which had persisted for 3 weeks. The patient noticed weakness upon waking but experienced no pain; he had no history of trauma, surgery, or infection. Curiously, he presented similar symptoms in the right arm 4 months earlier, with proximal, painless weakness and paraesthesia in the hand, from which he was still recovering. Again, our patient noticed all these symptoms upon waking. During the first event, an electroneuromyography (EMG) study (Tables 1 and 2) revealed right brachial plexopathy, extending throughout the upper trunk, and a slightly prolonged distal latency in the right motor median nerve, sensory median nerve, and sensory ulnar nerve. When the second event occurred, the patient was transferred to our department for observa-

tion. Examination revealed 4/5 muscle strength in abduction and external rotation of the right shoulder, and 3/5 muscle strength in abduction and 4/5 in external rotation of the left shoulder. No paresis was observed in the remaining muscle segments; deep tendon reflexes were weak in the upper limbs; no further abnormalities were observed. An EMG study (Tables 1 and 2) revealed left brachial plexopathy with a major lesion of the upper trunk and neuropathy of the left ulnar nerve at the elbow; no further alterations were observed. Cervical magnetic resonance imaging (MRI) results were normal. A high-resolution MRI of the brachial plexuses (Fig. 1) showed increased signal in the left supraspinatus, infraspinatus, and teres minor muscles, suggesting muscle denervation with no structural lesion of the left brachial plexus. Blood analyses, including an autoimmune profile, yielded normal results. Since the clinical symptoms and neurophysiological results suggested a diagnosis of HNPP, we requested genetic testing; this revealed a heterozygous deletion (17p11.2-12) in the peripheral myelin protein 22 gene (*PMP22*), which confirmed the diagnosis. Our patient recovered muscle strength in his arms with rehabilitation; preventive measures were adopted.

HNPP normally manifests during the second or third decade of life, although age of onset varies greatly.<sup>3,4</sup> Diagnosis requires a clinical history of recurrent neuropathies, a consistent family history of autosomal dominant inheritance, evidence of focal demyelinating sensorimotor neuropathies at entrapment sites and/or diffuse demyelinating sensorimotor polyneuropathy in nerve conduction studies, focal myelin thickening in nerve biopsy, when applicable, and lastly, confirmation from genetic testing.<sup>1-4</sup> Most patients present a deletion in chromosome 17p11.2, including the *PMP22* gene, and the remaining patients present a mutation of the gene itself.<sup>5,6</sup>

The phenotypic profile of HNPP is highly heterogeneous, even within a single family. Brachial plexopathy may manifest in some patients, but HNPP is generally associated with other recurrent mononeuropathies, presenting throughout the course of the disease.<sup>1,2</sup> The short disease duration in our patient may explain the lack of symptoms caused by the action of another nerve, and the negative family history may be explained by an asymptomatic disease in one of his parents, or a de novo deletion in our patient. In the literature, only a small number of families with HNPP present recurrent brachial plexopathies as the sole clinical manifestation,<sup>7-12</sup> and symptoms of those families started upon waking, which indicates a greater vulnerability of the brachial plexus to mechanical factors during sleep.<sup>11</sup>

Beyond HNPP, differential diagnosis of non-traumatic brachial plexopathy must consider compressive lesions,

<sup>☆</sup> Please cite this article as: Morgado J, Sousa AP, Alves P, Medeiros L. Plexopatía braquial bilateral como forma de presentación de la neuropatía hereditaria con parálisis sensible a la presión. *Neurología*. 2017;32:626-629.