



## LETTERS TO THE EDITOR

## Reversible delayed post-hypoxic leukoencephalopathy<sup>☆</sup>



### Leucoencefalopatía posthipóxica diferida reversible

Dear Editor,

Delayed post-hypoxic leukoencephalopathy (DPHL) is a rare condition that may manifest after a prolonged period of cerebral hypoxia.

We present the case of a 43-year-old man who was found unconscious at his home. Examination revealed generalised muscle rigidity, miotic pupils, lack of response to stimuli, and a Glasgow Coma Scale score of 3. He initially responded to intravenous naloxone, but significant respiratory effort persisted, with tachypnoea, tachycardia, and diffuse rhonchi on auscultation. Despite receiving oxygen at an FiO<sub>2</sub> of 100%, and nebulised salbutamol and ipratropium bromide, the patient developed acute respiratory failure, requiring orotracheal intubation and mechanical ventilation. He presented low-grade fever, and a chest radiography revealed consolidations at both lung bases; the results of a cranial CT scan and a blood test were normal. A urine test revealed presence of benzodiazepines, opioids, and cannabis. His personal history included paranoid schizophrenia, beginning in adolescence and treated with olanzapine and amisulpride. He also occasionally consumed opioid and sedative drugs, cannabis, and cocaine.

Two days after admission, his level of consciousness recovered; a neurological examination yielded normal results. As a complication, the patient developed a respiratory infection, which responded well to antibiotics, and acute renal damage secondary to an increased level of creatine kinase (8277 U/L), due to probable rhabdomyolysis. Twenty-one days after admission, his condition suddenly worsened, with the development of somnolence and bradypsychia. He progressively began to present stereotypic movements, motor disinhibition, and reduced verbal communication, with diminished fluency and impaired comprehension. All limbs presented cogwheel rigidity. Myotatic reflexes were normal and plantar reflexes were flexor

bilaterally. No focal deficit in strength or sensitivity was observed at any time. He became unable to walk, as gait deteriorated with a significant apraxic component. In the following days, clinical symptoms deteriorated until the patient's condition progressed to akinetic mutism.

A brain magnetic resonance imaging (MRI) scan performed 3 weeks after the hypoxic event revealed extensive involvement of the white matter in T2-weighted and FLAIR sequences, and restriction in diffusion-weighted sequences (Fig. 1A and B).

General analysis including a coagulation study, autoimmunity study, serology test, copper test, lactate tests, and arylsulphatase A test yielded no relevant findings. The patient received general care and rehabilitation therapy and his condition improved gradually; after 2 months and a half, he had recovered to a baseline state and was discharged. One year after admission, the patient remains asymptomatic and can perform the activities of daily living independently. Likewise, MRI scans show a very favourable evolution (Fig. 1C and D). Considering the clinical and radiological recovery, and having excluded other possible inflammatory or infectious causes, final diagnosis was reversible DPHL.

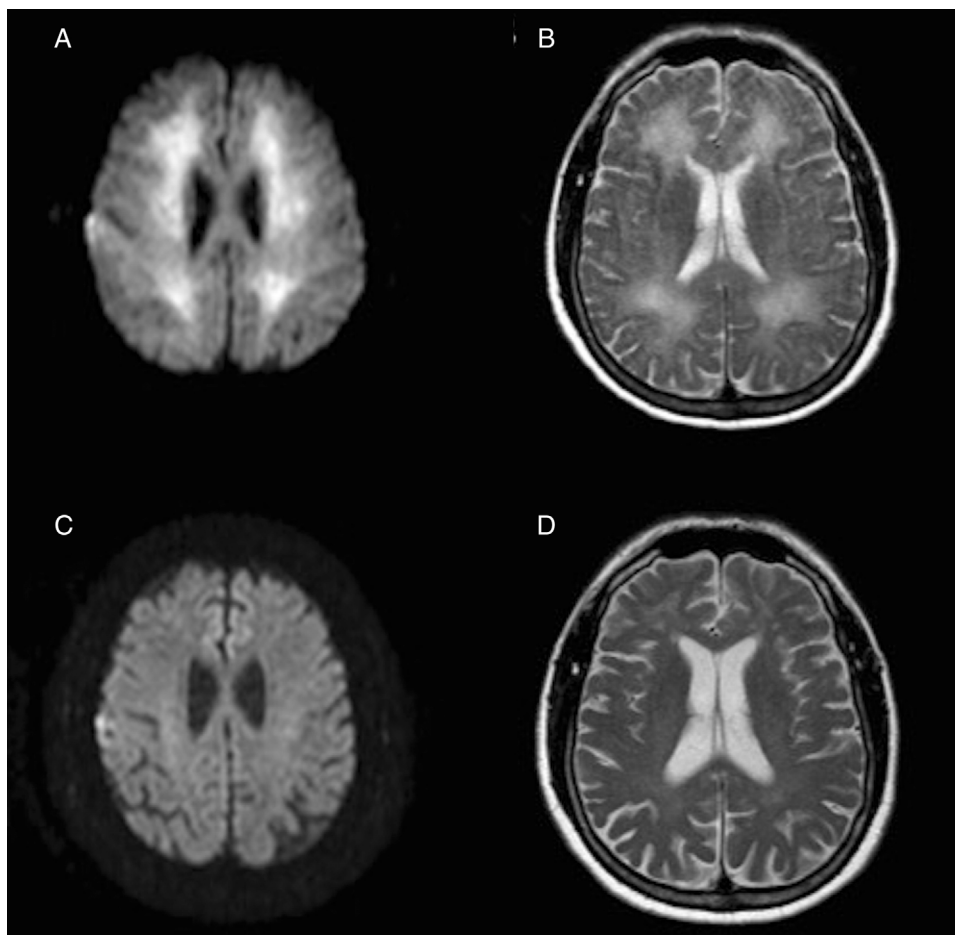
This condition is typically characterised by a biphasic course with an immediate recovery after an episode of cerebral hypoxia-induced coma; onset is followed by neuropsychiatric symptoms days or weeks after the episode.<sup>1</sup>

The cause most frequently associated with this entity is carbon monoxide poisoning,<sup>2</sup> but it may also occur after other such anoxic events as strangulation,<sup>3</sup> haemorrhagic shock,<sup>4,5</sup> or opiate or sedative agent abuse,<sup>6,7</sup> as in our case.

The precise pathophysiological mechanism of DPHL is still to be determined, but given the similarity between the demyelinating findings on the MRI and those typical of metachromatic leukodystrophy, it has been suggested that a deficiency of arylsulphatase A (which is necessary for myelin turnover) may predispose to this syndrome.<sup>8,9</sup> However, several similar cases with normal levels of this enzyme have also been published.<sup>10</sup> Other mechanisms involved are the myelin toxicity of some external agents,<sup>11</sup> alterations in the regulation of white matter vascularisation,<sup>12</sup> or the specific susceptibility of white matter oligodendrocytes to cerebral hypoxia.<sup>13</sup>

The characteristic clinical symptoms include cognitive/behavioural impairment, disorientation, frontal signs, amnesia, parkinsonism, akinetic mutism, and psychosis. MRI images typically show hyperintensity in T2- and diffusion-weighted sequences; cerebrospinal fluid analysis yields normal results. There is no specific treatment, and prognosis may vary; complete recovery may be achieved, probably depending on the patient's age.<sup>1</sup>

<sup>☆</sup> Please cite this article as: Tainta M, de la Riva P, Urta-sun MÁ, Martí-Massó JF. Leucoencefalopatía posthipóxica diferida reversible. Neurología. 2018;33:59–61.



**Figure 1** Axial MRI images obtained 3 weeks after the hypoxic event, with restricted diffusion in the diffusion-weighted sequence (A) and hyperintensity in the T2-weighted sequence (B) extensively affecting the whole periventricular white matter. Below, diffusion-weighted (C) and T2-weighted sequences (D) obtained one year later show the resolution of both alterations.

In conclusion, DPHL is an infrequent entity with characteristic clinical symptoms which should be known in order to avoid administering unnecessary treatments and diagnostic tests; cranial MRI scans are useful for diagnosis and follow-up.

## Funding

This study received no funding of any kind.

## Conflicts of interest

The authors have no conflicts of interest to declare.

## References

1. Shprecher D, Mehta L. The syndrome of delayed post-hypoxic leukoencephalopathy. *NeuroRehabilitation*. 2010;26:65–72.
2. Geraldo AF, Silva C, Neutel D, Neto LL, Albuquerque L. Delayed leukoencephalopathy after acute carbon monoxide intoxication. *J Radiol Case Rep*. 2014;8:1–8.
3. Hori A, Hirose G, Kataoka S, Tsukada K, Furui K, Tonami H. Delayed postanoxic encephalopathy after strangulation. Serial neuroradiological and neurochemical studies. *Arch Neurol*. 1991;48:871–4.
4. Mizutani T, Shiozawa R, Takemori S, Tsurumaru M, Akiyama H. Delayed post-anoxic encephalopathy without relation to carbon monoxide poisoning. *Intern Med*. 1993;32:430–3.
5. Chen-Plotkin AS, Pau KT, Schmahmann JD. Delayed leukoencephalopathy after hypoxic–ischemic injury. *Arch Neurol*. 2008;65:144–5.
6. Blackburn DJ, Alix JJ, Sarrigiannis P, Hoggard N, Bandmann O. Delayed toxic–hypoxic encephalopathy. *Pract Neurol*. 2013;13:114–9.
7. Okuda S, Ueno M, Hayakawa M, Araki M, Kanda F, Takano S. Delayed posthypoxic leukoencephalopathy: case reports. *Rinsho Shinkeigaku*. 2012;52:672–6 [in Japanese].
8. Gottfried JA, Mayer SA, Shungu DC, Chang Y, Duyn JH. Delayed posthypoxic demyelination. Association with arylsulfatase A deficiency and lactic acidosis on proton MR spectroscopy. *Neurology*. 1997;49:1400–4.
9. Weinberger LM, Schmidley JW, Schafer IA, Raghavan S. Delayed postanoxic demyelination and arylsulfatase – a pseudodeficiency. *Neurology*. 1994;44:152–4.

10. Molloy S, Soh C, Williams TL. Reversible delayed posthypoxic leukoencephalopathy. *Am J Neuroradiol.* 2006;27:1763–5.
11. Protass LM. Delayed postanoxic encephalopathy after heroin use. *Ann Intern Med.* 1971;74:738–9.
12. Ginsberg MD, Hedley-Whyte ET, Richardson EP. Hypoxic–ischemic leukoencephalopathy in man. *Arch Neurol.* 1976;33:5–14.
13. Benarroch EE. Oligodendrocytes: susceptibility to injury and involvement in neurologic disease. *Neurology.* 2009;72:1779–85.

M. Tainta<sup>a,\*</sup>, P. de la Riva<sup>a</sup>, M.Á. Urtasun<sup>a</sup>,  
J.F. Martí-Massó<sup>a,b,c</sup>

<sup>a</sup> *Servicio de Neurología, Hospital Universitario Donostia, San Sebastián, Guipúzcoa, Spain*

<sup>b</sup> *Facultad de Medicina, Universidad País Vasco, San Sebastián, Guipúzcoa, Spain*

<sup>c</sup> *Área de Neurociencias, Instituto Biodonostia, San Sebastián, Guipúzcoa, Spain*

\* Corresponding author.

E-mail address: [mikeltainta@gmail.com](mailto:mikeltainta@gmail.com) (M. Tainta).  
2173-5808/

© 2015 Sociedad Española de Neurología. Published by Elsevier España, S.L.U. This is an open access article under the CC BY-NC-ND license (<http://creativecommons.org/licenses/by-nc-nd/4.0/>).

## Clinical, biochemical, and molecular findings in a Colombian patient with Tay-Sachs disease<sup>☆</sup>



### Caracterización clínica, bioquímica y molecular de una paciente colombiana con enfermedad de Tay-Sachs

Dear Editor,

Tay-Sachs disease is an autosomal recessive neurodegenerative disorder characterised by a mutation or deletion of the hexosaminidase A gene (*HEXA*), located at 15q23. The gene codes for the alpha subunit of hexosaminidase A, a lysosomal enzyme involved in ganglioside metabolism.<sup>1,2</sup>

Tay-Sachs disease is a lysosomal storage disease and generally manifests after a period of normal neurological development. In this disease, gangliosides (GM2), a type of sphingolipid present in the membranes of cells of the central nervous system, are stored due to the lack of hexosaminidase A. The accumulation of gangliosides causes irreversible neurological damage and death at young ages.<sup>3,4</sup>

We present the case of a 5-year-old girl with clinical, biochemical, and molecular symptoms of Tay-Sachs disease.

Our patient was born in Colombia, and was the mother's second child; the older sibling was healthy. No alterations were observed during her gestation, except for the mother's subjective perception of reduced fetal movement. When she was 8 days old, she presented frequent vomiting with no food content and mobilisation of secretions which became persistent; no further relevant pathological findings were observed until 9 months of age, when initially distal and subsequently generalised myoclonic seizures appeared.

At about 10 months of age, the patient showed some regression in developmental milestones: she did not follow objects with her eyes or grasp objects and had a weak suck. At 11 months of age, she suffered a tonic-clonic seizure which led her to convulsive status epilepticus and was transferred to an emergency department; a brain CT scan showed no alterations. A brain MRI scan was performed when she was 14 months old (Fig. 1), revealing alterations in the myelination pattern, which affected the basal ganglia (mainly the putamen, globus pallidus, and caudate nucleus). A discrete component was observed in the posterior thalamic and corticospinal tracts at the level of the midbrain. These findings were compatible with hypomyelination.

From the age of 11 months, our patient began to display progressive neurological impairment and recurrent aspiration pneumonia, which led to the performance of a gastrostomy to decrease episodes of pulmonary aspiration. At the age of 3.5 years, she became completely disconnected from her environment, and hypotonia progressed to generalised spasticity; when the patient was 4 years of age, she presented central apnoea and underwent a tracheostomy connection to a continuous positive airway pressure system.

In the light of the clinical symptoms described, Tay-Sachs disease was suspected and a quantification of enzymatic activity of hexosaminidase in serum yielded normal levels; however, hexosaminidase A levels were critically diminished at 5.88% (reference values between 58% and 68%). The presence of lipids in neuronal cells was confirmed by magnetic resonance spectroscopy. Significantly reduced levels of N-acetyl aspartate and preserved levels of choline were observed (loss of N-acetyl aspartate is typical of demyelinating diseases). The brain nuclear MRI scan revealed greater hyperintensities in the thalamic and involuntary changes secondary to the disease in comparison to the MRI scan performed at 14 months of age (Fig. 1). Given the laboratory test results, sequencing studies of the *HEXA* gene were requested and revealed a heterozygous pathogenic mutation of intron 9, with a change in the nucleotide c. 1073 + 1G > A. This mutation has previously been reported as pathological by Akli et al.<sup>5</sup> in 1991.

Tay-Sachs disease, described in 1881 by Tay and in 1887 by Sachs, is currently one of the most widely studied sphingolipidoses within the context of lysosomal storage

<sup>☆</sup> Please cite this article as: Posso Gomez LJP, Gomez JF, Botero V, Pachajoa H. Caracterización clínica, bioquímica y molecular de una paciente colombiana con enfermedad de Tay-Sachs. *Neurología.* 2018;33:61–63.