

Brain perfusion SPECT with ^{99m}Tc -HMPAO in the diagnosis and follow-up of patients with anti-NMDA receptor encephalitis[☆]



SPECT cerebral de perfusión con ^{99m}Tc -HMPAO en el diagnóstico y seguimiento de la encefalitis con anticuerpos contra el receptor NMDA

Dear Editor:

Anti-N-methyl-D-aspartate (NMDA) receptor encephalitis was first described in 2007. The most frequent forms result from extracellular antibody-mediated autoimmunity.¹ Prognosis improves with early, aggressive immunotherapy; aetiological diagnosis is therefore essential. Diagnosis is based on the detection of anti-NMDA receptor antibodies in the serum and cerebrospinal fluid (CSF).² MRI usually shows normal findings or mild alterations.³ Given the lack of specificity and the frequently subacute onset of symptoms, brain

perfusion SPECT with ^{99m}Tc -HMPAO may be helpful for establishing a diagnosis, ruling out other conditions and revealing findings suggestive of encephalitis. However, SPECT findings in patients with anti-NMDA receptor encephalitis vary; alterations may affect one or both temporal lobes,^{4,5} and involve such other regions as the frontal lobe.^{3,6} We present the case of a 34-year-old man who was admitted with a 2-week history of progressive language impairment, which worsened in the days prior to admission. The examination revealed symptoms of aphasia associated with alexia and acalculia, as well as neuropsychiatric manifestations (agitation and delirium). At the age of 14 years, our patient had experienced an episode of refractory epilepsy, which was diagnosed as Rasmussen encephalitis and left no neurological sequelae. An EEG performed at admission revealed moderate, bilateral, frontotemporal, focal slow wave activity, predominantly affecting the left hemisphere, with no evidence of status epilepticus. Head CT and brain MRI scans revealed no alterations. Given suspicion of limbic encephalitis, we performed a brain perfusion SPECT with ^{99m}Tc -HMPAO, which showed hyperperfusion in the left temporal cortex; hyperperfusion in the right temporal cortex was less marked and less extensive. These findings are compatible with limbic encephalitis (Fig. 1A and C). Tests for anti-NMDA receptor antibodies in the CSF yielded

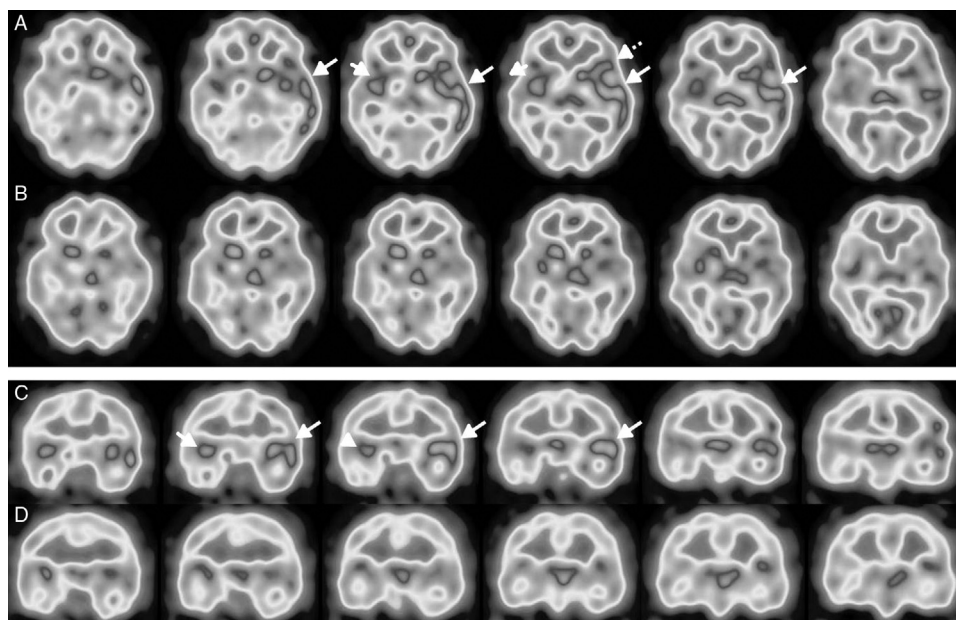


Figure 1 Brain perfusion SPECT scan with ^{99m}Tc -HMPAO, performed at diagnosis. Axial (A) and coronal (C) sequences showing hyperperfusion in the left temporal cortex (long arrows), predominantly in the superior lateral area and the insula, and extending to the adjacent frontotemporal area (Broca area) (dotted arrow). Hyperperfusion was less marked and less extensive in the right temporal cortex (short arrows). A follow-up study conducted after 5 months (B and D) revealed nearly complete resolution of abnormal brain perfusion.

[☆] Please cite this article as: Suárez JP, Domínguez ML, Gómez MA, Portilla JC, Gómez M, Casado I. SPECT cerebral de perfusión con ^{99m}Tc -HMPAO en el diagnóstico y seguimiento de la encefalitis con anticuerpos contra el receptor NMDA. *Neurología*. 2018;33:622–623.

positive results. The results of a chest, abdomen, and pelvis CT scan and a serum tumour marker test ruled out a paraneoplastic origin. The patient was diagnosed with non-paraneoplastic anti-NMDA receptor encephalitis and treated with corticosteroids, immunoglobulins, and rituximab. Clinical progression was unstable; language impairment and neuropsychiatric manifestations persisted, motor symptoms (myoclonus and rigidity, with no clear epileptogenic focus) worsened, and the patient developed symptoms of dysautonomia. Neurological symptoms improved progressively with cyclophosphamide. A follow-up brain SPECT scan performed 5 months after the initial symptoms showed near-complete resolution of the alterations (Fig. 1B and D). Other successfully treated patients with this type of encephalitis have also shown disappearance or improvement of abnormal findings in brain perfusion SPECT^{3,4} or ¹⁸F-FDG-PET.⁷ Brain perfusion SPECT played a crucial role in the diagnosis of this type of encephalitis given the atypical initial symptoms; language impairment of subacute onset suggested other diagnoses.

References

1. Dalmau J, Lancaster E, Martínez-Hernández E, Rosenfeld MR, Balice-Gordon R. Clinical experience and laboratory investigations in patients with anti-NMDAR encephalitis. *Lancet Neurol.* 2011;10:63–74.
2. Titulaer MJ, McCracken L, Gabilondo I, Armangué T, Glaser C, Iizuka T, et al. Treatment and prognostic factors for long-term outcome in patients with anti-NMDA receptor encephalitis: an observational cohort study. *Lancet Neurol.* 2013;12:157–65.
3. Llorens V, Gabilondo I, Gómez-Esteban JC, Agúndez M, Mendibe M, Bergara JC, et al. Abnormal multifocal cerebral blood flow

- on Tc-99m HMPAO SPECT in a patient with anti-NMDA-receptor encephalitis. *J Neurol.* 2010;257:1568–9.
4. Yoshino A, Kimura Y, Miyazaki M, Ogawa T, Matsumoto A, Nomura S, et al. Limbic encephalitis with autoantibodies against the glutamate receptor epsilon 2 mimicking temporal lobe epilepsy. *Psychiatry Clin Neurosci.* 2007;61:335.
5. Miyazaki M, Yoshino A, Teraishi T, Nomura S, Nemoto H, Takahashi Y. Encephalitis of unknown etiology with anti-GluR epsilon2 autoantibody, showing divergent neuroradiologic and clinical findings. *Eur Neurol.* 2007;57:111–3.
6. Iizuka T, Sakai F, Ide T, Monzen T, Yoshii S, Iigaya M, et al. Anti-NMDA receptor encephalitis in Japan: long-term outcome without tumor removal. *Neurology.* 2008;70:504–11.
7. Probasco JC, Benavides DR, Ciarallo A, Sanin BW, Wabulya A, Bergey GK, et al. Electroencephalographic and fluorodeoxyglucose-positron emission tomography correlates in anti-N-methyl-D-aspartate receptor autoimmune encephalitis. *Epilepsy Behav Case Rep.* 2014;2:174–8.

J.P. Suárez^{a,*}, M.L. Domínguez^a, M.A. Gómez^a, J.C. Portilla^b, M. Gómez^b, I. Casado^b

^a Servicio de Medicina Nuclear, Hospital San Pedro de Alcántara, Cáceres, Spain

^b Servicio de Neurología, Hospital San Pedro de Alcántara, Cáceres, Spain

* Corresponding author.

E-mail address: juanpablosuarez@yahoo.es

(J.P. Suárez).

2173-5808/

© 2016 Sociedad Española de Neurología. Published by Elsevier España, S.L.U. This is an open access article under the CC BY-NC-ND license (<http://creativecommons.org/licenses/by-nc-nd/4.0/>).

Varicella-zoster virus meningitis in an immunocompetent paediatric patient^{☆☆}



Meningitis causada por el virus varicela-zóster en un niño inmunocompetente

Dear Editor:

Herpes zoster is the localised manifestation of varicella-zoster virus (VZV) infection. It occurs as a result of reactivation of the virus, which remains latent in sensory ganglia of cranial and spinal nerves once the infection resolves. Neurological complications of herpes zoster are

relatively infrequent, especially in immunocompetent children.

We present the case of a 7-year-old boy who was admitted due to headache, vomiting, photophobia, and somnolence. The day before admission, the child's parents noticed that the patient had an erythematous exanthem on the left scapula, which was initially micropapular and subsequently vesicular; the exanthem was not pruriginous or painful. Two weeks previously, the patient had experienced upper respiratory tract infection. He had no recent history of foreign travel, contact with sick people, or insect bites. The patient had been vaccinated according to the Portuguese vaccination calendar; he had not received the varicella vaccine but had developed the condition at the age of 2 years. His parents were non-consanguineous.

During examination, the child was afebrile, haemodynamically stable, and drowsy (but easily awakened); he displayed no meningeal or focal neurological signs. Eye fundus examination revealed no abnormalities. The left scapular region showed a vesicular exanthem on an erythematous base, suggestive of herpes zoster. A complete blood count yielded 6000 leukocytes/mm³, 90.2% neutrophils, and normal C-reactive protein levels. A CSF analysis revealed 480 leukocytes/mm³ (96.7% mononuclear cells), a protein level of 90 mg/dL, and low glucose levels (41 mg/dL in the

[☆] Please cite this article as: Oliveira K, Fonseca J, Moreira D, Vila Real M. Meningitis causada por el virus varicela-zóster en un niño inmunocompetente. *Neurología.* 2018;33:623–624.

^{☆☆} This paper was presented in poster format at the 30th Annual Meeting of the European Society for Paediatric Infectious Diseases.